

# STRIPPING OF THE ANTERIOR ACCESSORY SAPHENOUS VEIN. AN UNEXPECTED COMPLICATION OF 1940 NM ENDOVENOUS LASER ABLATION

Łukasz Szczygieł, Piotr Hawro

Centre of Minimal Invasive Phlebology Avimed, Bytom, Poland

## ABSTRACT

Endovenous laser ablation (EVLA) by the means of the latest 1940 nm wavelength device is suggested to become a promising alternative to the standard 1470 nm device in the treatment of incompetent truncal superficial veins. Limited penetration into the vein wall as well as the lack of probe carbonisation and high procedure safety are among the main arguments in the centres promoting this technology.

In the paper we describe a unique complication of the 1940 nm laser ablation consisting of the removal of the treated vein by invagination stripping after its wall carbonization and sticking to the end of the laser fibre.

Fortunately, the procedure resulted in mild ecchymoses only and no severe damage was observed. The presented case highlights the importance of ultrasound guidance during the EVLA as well as the need to establish both the proper power and linear endovenous energy density for the individual procedure.

**Key words:** complications. endovenous laser ablation, varicose veins.

## CASE REPORT

Phlebological Review 2022; 30, 1: 17–20

DOI: <https://doi.org/10.5114/pr.2022.131067>

Submitted: 14.07.2022

Accepted: 26.09.2022

## ADDRESS FOR CORRESPONDENCE

Dr Łukasz Szczygieł

OFM Avimed

Pl. Stefana Żeromskiego 1

41-914 Bytom

e-mail: [lukasz\\_szczygiel@o2.pl](mailto:lukasz_szczygiel@o2.pl)

## INTRODUCTION

Endovenous laser ablation (EVLA) techniques for the treatment of truncal vein incompetence, both with 1470 nm and 1940 nm lasers, proved to be effective. With their short- and medium-term outcomes they are at least as effective as traditional surgical procedures of high junction ligation and saphenous vein stripping.

Laser energy exposure induces thermal injury of the vein wall as well as boiling the water around the probe, which results in the vein wall destruction, vein shrinkage, and effective vessel occlusion [1].

The 1940 nm laser, with its higher water affinity, is identified as having an ideal wavelength to produce selective damage with greater safety and lower incidence of adverse effects when compared to a 1470 nm laser. According to the previously performed research, it is claimed that lower power and lower linear endovenous energy density (LEED) are satisfactory when using the 1940 nm laser because water has a greater affinity for this wavelength [2]. Simultaneously, the shallower penetration depth of the 1940 nm wavelength into the vein wall and surrounding tissues at least theoretically gives the possibility of the safe application of much larger amounts of energy in the limited area around the probe [3]. In recently published research, Whiteley *et al.* reported that in a porcine liver model there was no significant difference in thermal spread between 1470 nm and 1940 nm laser

devices at powers of 6 W, 8 W, and 10 W. Surprisingly, in the same study, significantly more carbonisation was found with the 1940 nm laser compared to 1470 nm laser [4]. This differs from the previous observations from lower wavelength laser studies. In a paper published in 2010, Amzayy *et al.* reported that the thickness of carbonized blood deposited on fibres during 810, 940, and 1470 nm EVLA procedures correlated positively with delivered energy (LEED) and not with the wavelength [5].

In the case of highly water-absorbed laser radiation, convection and boiling play a major role in the process of heat transfer. As the water absorption for the 1940 nm wavelength is more effective than for 1470 nm, the higher wavelength has lower penetration and was more efficient especially in the very small inner vein diameters (vein lumens as small as possible, i.e. veins emptied of blood), so the proper tumescence procedures are crucial when using 1940 nm laser devices, not only for the procedure safety but also its efficacy [6].

In the case of improper contact of the probe with the inner layer of the vein wall, lower energies suggested for 1940 nm laser ablation, due to the insufficient LEED, may result in lower vein occlusion rates comparing to the 1470 nm wavelength laser [7].

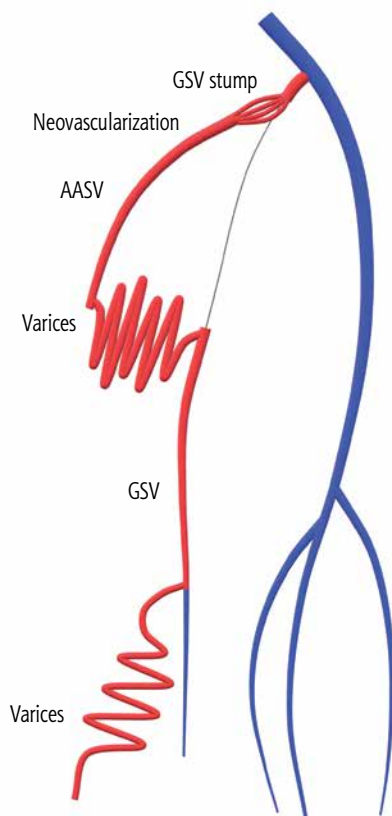
As documented in the previously performed studies, endovenous ablation procedures appear to be a more efficient therapy by the combination of higher laser power and faster pullback velocity than by the inverse combi-

nation, when the declared LEED is the same [8]. On the other hand, it has been reported that commonly used parameters of EVLA (wavelength, administered energy, and outcome definition) have no influence on the treatment success rate [9]. However, these conclusions are unacceptable to practicing phlebologists, and they have been met with balanced comment [10].

One of the possible complications of endovenous laser technology is thermal injury and vein wall perforation by the laser fibre, which happens more often in the case of the bare fibre application. The use of the radial fibre and continuous radial dispersion of the energy inside the vein lumen significantly decreases the risk of this kind of complications. However, the possible carbonisation on the fibre surface as well as the possibility of sticking of the probe to the vein wall surface can, at least potentially, lead to local thermal injury of the vein wall and perivenous tissues also in the case of the use of modern laser fibre technology. In this paper, we describe the case of unscheduled anterior accessory saphenous vein (AASV) stripping during 1940 nm endovenous ablation.

## CASE REPORT

A hybrid procedure was planned in a 54-year-old female patient with recurrent varicose veins. According



**Fig. 1.** Anatomy illustration

AASV – anterior accessory saphenous vein, GSV – great saphenous vein

to the medical history, the patient had undergone cross-section of the saphenofemoral junction and stripping of the great saphenous vein (GSV). She had also suffered from superficial vein thrombosis in the location of the varicose veins. In the preoperative ultrasound, the short (1 cm) saphenous vein stump generated reflux, which was transferred via the neovascularisation vessels in the groin region to the residual AASV trunk present in the upper one-third of the thigh (proximal diameter 6 mm, vein length 18 cm) generating varicose veins in the anterior part of the thigh. Below this point, the reflux from the varicose veins (fed by AASV) was also transferred to the residual incompetent GSV (present from the level of the mid-thigh, with diameter 5–8 mm) and to the varicose veins on the medial surface of the calf (Fig. 1).

Endovenous laser ablation was performed using a diode laser source (Biolitec Leonardo 1940) with a wavelength of 1940 nm, power of 8 W, and LEED of 80 J/cm. The amount of energy used by us to close the treated veins during the procedure was related to our experiences from the earlier application of the lower energy, which did not guarantee a sufficient closure rate (paper manuscript in preparation, data not published yet). Both the GSV and AASV veins were accessed via percutaneous route from the caudal aspect using a 21-gauge (G) needle under local anaesthesia and ultrasound (US) guidance.

Tumescent anaesthetic solution, which was prepared using 25 ml of 2% lidocaine, 500 ml 0.9% NaCl, 10 ml 8.4% sodium bicarbonate, and 0.5 mg adrenalin, was administered around the treated vein using 19 G needles under US guidance (100 ml per 10 cm of the treated vein length). Before administration of tumescent local anaesthesia, a 2-ring laser fibre, which was attached to the 1940 nm diode laser generator, was advanced through the catheter and placed in the proximal end of the GSV and then the proximal end of the AASV.

There were no technical difficulties during the laser ablation of the GSV. Laser energy was delivered in the total amount of 2857 J on the length of 46 cm.

During the AASV laser ablation, after pulling out about 10 cm of the fibre, significant resistance was noticed which prevented further withdrawal of the fibre. After an interruption of the laser energy emission, the laser fibre with its tip was released with gentle movements forward and backward, and then laser ablation was continued. After vascular sheath removal, during the removal of the tip of the laser fibre strong resistance was felt again, and the skin around the insertion site was bulged. Overcoming the resistance, the tip of the fibre was removed together with the evolved AASV (Fig. 2).

Having examined the tip of the fibre we found that the proximal part of the vein glued to it and the vein wall in this segment was charred (Fig. 3).

The remaining 6 cm section of the vein wall appeared unchanged, and there was no carbonization on the laser fibre tip. The delivered laser energy to the 18 cm AASV

length was 1178 J. In the performed US after unexpected stripping of the ASSV we did not notice any significant bleeding or local haematoma, and the groin tissue was compressed by the previously injected tumescent anaesthesia.

After the laser procedure, foam sclerotherapy was performed: under US guidance 6 ml of 3% aethoxysklerol in the form of foam was administered to the neovascularisation veins in the groin, filling the refluxing vessels as well as the GSV stump (due to the length of only 1 cm, the GSV stump was not closed by laser ablation).

After the procedure, compression therapy was applied (CCL-2 stocking), and the patient received antithrombotic prophylaxis with subcutaneous doses of LMWH.

During the post-operative observation, we investigated only slight subcutaneous haematoma in the groin that disappeared within 3 weeks. The follow-up colour Doppler US showed proper occlusion of the saphenous stump, trunk of GSV, and neovascularisation veins of the groin. The proximal part of the AASV was occluded and narrow, and the vein was invisible (removed) in the distal part.

## DISCUSSION

Endovenous laser ablation is an effective, safe, and easily applicable method that is well accepted by patients in the treatment of GSV and AASV refluxes. Together with radiofrequency ablation, EVLA remains one of the most commonly used methods of truncal varicose vein treatment, which corresponds with the current guideline recommendations [11]. The progress in the laser and fibre technology resulted in the implementation of the technical solutions including 1470 nm or 1940 nm lasers as well as radial fibres. Due to the high safety and very high efficacy, in many centres 1470 nm laser ablation has become the standard of care. Pavei *et al.* reported that 10 years after EVLA with a 1470 nm wavelength laser in 203 patients, only one recanalization (0.5%) of the treated GSV trunk was observed in an otherwise asymptomatic patient, and up to 98% of patients were asymptomatic or significantly improved after EVLA. Complications, such as transient thrombophlebitis in 1.5% and paraesthesia in 0.5%, were also reported [12]. After preliminary research in the animal model as well as clinical implementation in the phlebology centres, now new data concerning the clinical efficacy of the new wavelengths including 1940 nm are coming.

Viarengo *et al.* performed EVLA with the 1940 nm wavelength laser in 41 patients and reported 100% initial complete occlusion of the vein trunk, but the late success rate was 95.1% (the average follow-up time was 803 days), and 2 recanalizations were observed around 12 months after ablation [6].

Both 1470 nm and 1940 nm laser technology, together with radial fibres, are characterized by the low rate of the periprocedural complications, including mostly postop-

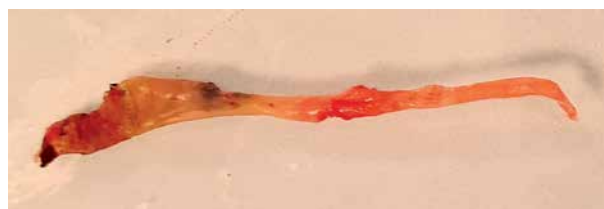

Fig. 2. Laser stripping

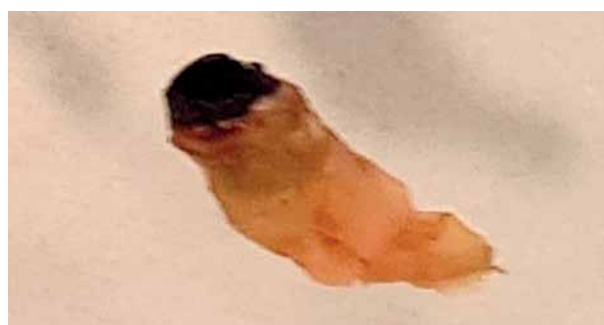

Fig. 3. Anterior accessory saphenous vein

erative neurological and thrombotic (EHIT, superficial thrombosis, DVT) episodes. To the best of our knowledge, laser fibre stripping has not been reported in the comprehensive literature of EVLA series. Despite years of experience with laser technology of various wavelengths, this was the first case of such complication also in our centre. In the available literature one case of vein stripping when using an MOCA device has been described by British authors, but up to now, no laser probe and endovenous laser-related stripping can be found [13].

The lack of the carbonisation of the radial fibre is one of the major described advantages of the new 1940 nm technology. According to our observation, the sticking of the fibre to the anterior accessory vein wall during our laser procedure interrupted the continuity of the vein and then pulled it out by eversion along with the laser fibre. Most of the energy administered thereafter was delivered locally to the vein glued to the fibre instead of the intended 18 cm AASV, and the actual LEED of the treatment in that segment was much higher than the planned 80 J per cm. This led to local vein closure but also to vein wall disruption.

The delivered energy tore the vein apart, but fortunately the thermal closure of the proximal end of the vein prevented bleeding. On the other hand, duplication

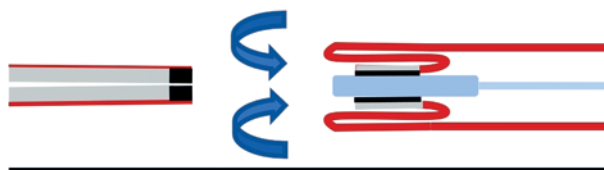


Fig. 4. Schema of the vein invagination, vein wall duplication, and stripping of the anterior accessory saphenous vein

of the vein wall during unexpected stripping meant that the applied energy did not reach the perivenous tissues of the extruded vein (Fig. 4).

## CONCLUSIONS

Despite this complication observed in our clinic, the final effect of the hybrid treatment was highly satisfactory, and we are still convinced that EVLA as a minimally invasive method is effective and safe, giving excellent results.

*The authors declare no conflict of interest.*

## References

1. Chudnovskii V, Mayor A, Kiselev A, Yusupov V. Foaming of blood in endovenous laser treatment. *Lasers Med Sci* 2018; 33: 1821-1826.
2. De Araujo WJB, Timi JRR, Kotze LR, Vieira da Costa CR. Comparison of the effects of endovenous laser ablation at 1470 nm versus 1940 nm and different energy densities. *Phlebology* 2019; 34: 162-170.
3. Żywicka B, Rybak Z, Janeczek M, et al. Comparison of A 1940 nm thulium-doped fiber laser and A 1470 nm diode laser for cutting efficacy and hemostasis in a pig model of spleen surgery. *Materials (Basel)* 2020; 13: 1167.
4. Whiteley MS, Cross AC, Whiteley VC. No significant difference between 1940 and 1470 nm in endovenous laser ablation using an in vitro porcine liver model. *Lasers Med Sci* 2021; 37: 1899-1906.
5. Amzayyb M, van den Bos RR, Kodach VM, et al. Carbonized blood deposited on fibres during 810, 940 and 1,470 nm endovenous laser ablation: thickness and absorption by optical coherence tomography. *Lasers Med Sci* 2010; 25: 439-447.
6. Viarengo LMA, Viarengo G, Martins AM, Mancini MW, Lopes LA. Resultados de médio e longo prazo do tratamento endovenoso de varizes com laser de diodo em 1940 nm: análise crítica e considerações técnicas. *J Vasc Bras* 2017; 16: 23-30.
7. Mendes-Pinto D, Bastianetto P, Cavalcanti Braga Lyra L, Kikuchi R, Kabnick L. Endovenous laser ablation of the great saphenous vein comparing 1920-nm and 1470-nm diode laser. *Int Angiol* 2016; 35: 599-604.
8. Poluektova AA, Malskat WS, van Gemert MJ, et al. Some controversies in endovenous laser ablation of varicose veins addressed by optical-thermal mathematical modeling. *Lasers Med Sci* 2014; 29: 441-452.
9. Malskat W, Engels L, Hollestein L, Nijsten T, van den Bos R. Commonly used endovenous laser ablation (EVLA) parameters do not influence efficacy: results of a systematic review and meta-analysis. *Eur J Vasc Endovasc Surg* 2019; 58: 230-242.
10. Whiteley MS. If it looks like a duck, swims like a duck, and quacks like a duck, then it probably is a duck. What "The Duck Test" tells us about systematic reviews and meta-analyses of LEED and other EVLA parameters. *Eur J Vasc Endovasc Surg* 2019; 58: 243.
11. De Maeseener M, Kakkos SK, Aherne T, et al. European Society for Vascular Surgery (ESVS) 2022 Clinical Practice Guidelines on the Management of Chronic Venous Disease of the Lower Limbs. *Eur J Vasc Endovasc Surg* 2022; 63: 184-267.
12. Pavei P, Spreafico G, Bernardi E, Giraldo E, Ferrini M. Favorable long-term results of endovenous laser ablation of great and small saphenous vein incompetence with a 1470-nm laser and radial fiber. *J Vasc Surg Venous Lymphat Disord* 2021; 9: 352-360.
13. Lane T, Moore H, Franklin I, Davies A. Retrograde inversion stripping as a complication of the Clarivein® mechanochemical venous ablation procedure. *Ann R Coll Surg Engl* 2015; 97: 18-20.