

A young woman with Takayasu arteritis: surgical and anesthetic management of Bentall procedure in a patient with abdominal aortic aneurysm and renal artery stenosis



Ayse Baysal, Murat Bulent Rabus, Saleh Alsalehi, Yasar Gul, Tuncer Kocak, Mehmet Balkanay

Kartal Kosuyolu Research and Training Hospital, Kartal, Istanbul, Turkey

Kardiochirurgia i Torakochirurgia Polska 2013; 10 (4): 422–424

Abstract

Takayasu's arteritis (TA) is a rare form of chronic vasculitis involving large arteries. We present the case of a 19-year-old female patient diagnosed with TA, whose medical treatment lasted a period of twelve months. The patient was admitted due to aortic regurgitation and enlargement of the aorta up to 6 cm. Her biochemical laboratory data were normal. Angiographic studies showed occlusive disease as well as aneurysms in the abdominal aorta and left renal artery, which are considered to be significant sources of postoperative complications. Hemodynamic parameters were well regulated throughout the surgery. No complications were recorded. Surgery for TA should be deferred during the active phase of the disease due to increased bleeding, friable tissue, and increased risk of thrombosis. Appropriate medical treatment before and during surgery is required to perform a successful surgical procedure without the development of postoperative complications.

Key words: Takayasu disease, vasculitis, abdominal aorta, aneurysm.

Introduction

Takayasu's arteritis (TA) is a rare chronic vasculitis that is associated with inflammatory changes in large arteries [1, 2]. Clinical and pathological studies on TA resulted in the classification of four different types of arterial lesions: 1) type I: the involvement is limited to the aortic arch and its branches; this affects 8.4% of patients; 2) type II: the lesions are localized in the descending and abdominal aorta; it concerns 11.2% of cases; 3) type III: the lesions share features of types I and II; it affects 65.4% of patients; 4) type IV: involvement of the pulmonary arteries in addition to the other lesions, which is observed in 15% of patients [3].

In this presentation, we discuss the clinical outcome of a young adolescent female patient with a diagnosis of TA

Streszczenie

Zespół Takayasu (*Takayasu's arteritis* – TA) jest rzadką formą przewlekłego zapalenia naczyń obejmującą duże tętnice. W pracy przedstawiono przypadek 19-letniej pacjentki z TA, która przeszła leczenie trwające 12 miesięcy. Pacjentka została przyjęta do szpitala z powodu niedomykalności zastawki aortalnej i poszerzenia aorty do 6 cm. Wyniki laboratoryjnych badań biochemicznych były w normie. Nie zaobserwowano komplikacji. Leczenie chirurgiczne TA powinno być odradzane na czas trwania aktywnej fazy choroby ze względu na zwiększone krwawienie, kruchość tkanek oraz zwiększone ryzyko zakrzepicy. Przeprowadzenie udanego zabiegu chirurgicznego bez wystąpienia pooperacyjnych komplikacji wymaga zastosowania adekwatnego leczenia przed zabiegiem i w jego czasie.

Słowa kluczowe: choroba Takayasu, zapalenie naczyń, aorta brzuszna, tętniak.

who was scheduled for an elective Bentall procedure after being under appropriate medical treatment for twelve months duration.

Case report

We present a 19-year-old female patient with TA who was on medical treatment for a year prior to admission for an elective Bentall procedure. She was started on a calcium channel blocker agent and on prednisolone treatment one year prior to admission. During her last six-month follow-up visit, she was found to have enlargement of the aorta up to 4 cm in the angiographic study which was not present in the previous studies. Although she was on steroid treatment, dipyridamole and immunosuppressive cyclophos-

Address for correspondence: Dr. Ayse Baysal, Kartal Kosuyolu Research and Training Hospital, Adres Denizler Cad. No:3 Kartal, 34400 Istanbul, Turkey, phone +902164562436, e-mail: draysebaysal@yahoo.com

phamide therapies were added to her regimen. Six months after this, she was admitted because of a moderate degree of aortic regurgitation and enlargement of the aorta up to 6 cm. On admission, the clinical findings during the physical examination included elevated superior limb blood pressure (148/92 mm Hg), decreased ratio of inferior to superior limb blood pressures (0.66), and detection of vascular murmurs at the bilateral regions of the neck and the abdomen. The results of hematologic examinations (C-reactive protein: 0.3 mg/dL; ESR: 16 mm/60 min) demonstrated no inflammatory findings. There were no abnormal findings in any other examinations. She was found to have normal biochemical laboratory data and normal

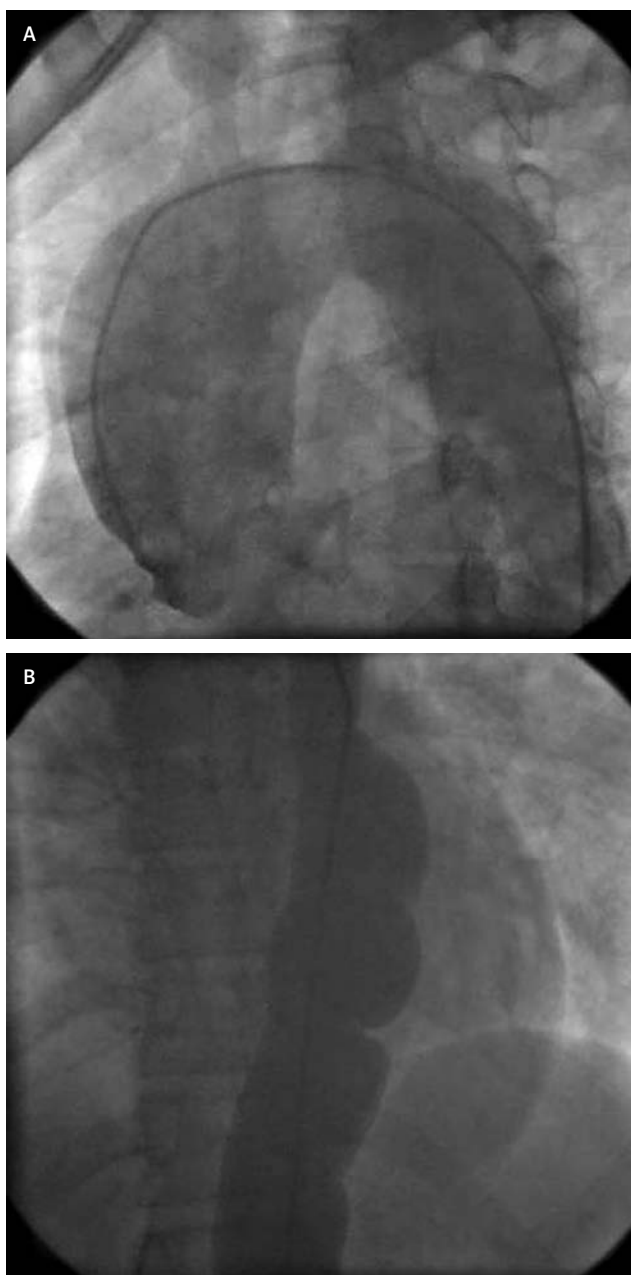


Fig 1A-B. A) Angiographic study of descending aorta. B) Angiographic study of abdominal aorta showing aneurysms and occlusive disease

chest X-ray without signs of cardiac dilatation or calcification. Occlusive disease and aneurysms were visualized in the ascending, descending and abdominal aorta in the angiographic study (Figs. 1A-B). Left sided renal artery stenosis was observed in this study as well. The visualization of the dilated ascending aorta and aortic insufficiency during dissection of the cardiac structures prior to the operative procedure is shown in Fig. 2. The surgical procedure involving aortic valve replacement (St Jude 21) and placement of a graft on the ascending aorta (Bentall procedure) was performed. Blood pressure, hemodynamic and renal function were adequately regulated throughout the surgery by appropriate anesthetic medical therapies including inhaled anesthetic agents (sevoflurane), an intravenous anesthetic agent (propofol), and intravenous doses of nitroglycerine, dopamine and furosemide. She required intravenous dobutamine at the dose of 5 μ /kg/hour at the end of cardiopulmonary bypass and continued for a total of 6 hours postoperatively. The patient was extubated on the first postoperative day and stayed three days in the intensive care unit. The patient was discharged home on the eighth postoperative day with continuance to her usual medical treatment. At her follow-up visit six months after surgery, her clinical and angiographic studies revealed that she remained stable.

Discussion

Surgery for TA should be deferred in the active phase of the disease as surgical interventions are associated with more bleeding, friable tissue and a high risk of thrombosis [1, 3, 4]. In our present case, the surgical procedure was successful without complications as the patient was well maintained on appropriate medical treatment before and during surgery. As the evaluation of the angiographic studies showed involvement of abdominal and renal arteries, TA can be classified as type III. For this reason, she was followed for deterioration in gastrointestinal and kidney functions after surgery for a week in hospital and during the next six months of the follow-up period. Surgical treat-

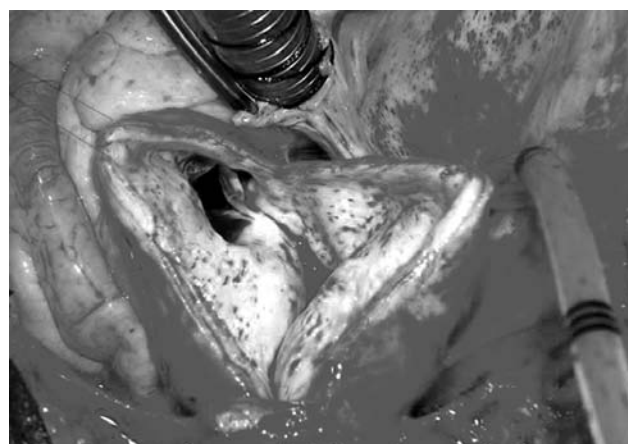


Fig. 2. Visualization of dilated ascending aorta and aortic insufficiency during dissection of the cardiac structures prior to the operative procedure

ment is reported to be challenging due to the diffuse nature of the disease and involvement of adjacent aortic walls. A high incidence of anastomotic aneurysm formation and graft failure was reported [5, 6]. In a report of 26 patients after a mean follow-up period of five years, it was suggested that surgical treatment of aortic lesions of the abdominal aorta in TA must be reserved for patients whose arterial hypertension is not under control despite medical treatment due to frequently occurring late degeneration of repairs [7]. However, another group of surgeons reported their findings on 10 patients after a 20-year follow-up and their opinion is that children with Takayasu's arteritis could benefit from reconstructive surgery with successful long-term results for mortality and morbidity [8].

In patients with TA, percutaneous angioplasty or stenting should be considered during long follow-up periods of symptomatic stenotic or occlusive disease. Percutaneous transluminal angioplasty is assuming a valuable role in treating involvement of the renal arteries [9, 10]. Endovascular therapy (usually balloon angioplasty) is safe to control hypertension with success rates ranging between 80 and 96%. The cumulative 5-year patency rate for the management of renal artery stenosis is 67% and the overall complication rates are low. Angioplasty has been reported to show less successful results in relieving obstruction in the mesenteric arteries [4, 11].

In patients with abdominal aortic aneurysm secondary to TA, a consensus on whether these patients should be treated with abdominal aortic resection has not been established. The incidence of abdominal aneurysm rupture has been reported to be low; however, as the disease occurs in young patients, a yearly routine follow-up is required to decide whether an abdominal aortic reconstruction is needed [4, 12].

The diagnosis of Takayasu's disease was made by clinical presentation, arteriography, and laboratory findings. In our clinic, patients with a diagnosis of TA are routinely assessed by routine physical examination, arteriography every 6 to 12 months and sedimentation rate. The use of steroid treatment is considered in the active state of TA and immunosuppressive drug treatment is added to the therapeutic regimen if steroid treatment is not successful to control the active disease state, which involves the presence of two or more of the following features: 1) fever or arthralgia, 2) raised erythrocyte sedimentation rate (ESR) (> 20 mm/h), 3) new claudication, bruit, or vascular pain, 4) new typical angiographic features. Arteriography is the best modality for the diagnosis of Takayasu's disease along with the use

of magnetic resonance angiography (MRA) and computed tomography (CT) scans that are commonly used during the process of diagnosis [7, 11, 12]. Surgery consists always of a bypass operation to vessels normal on angiography and distal to the occlusive or stenotic lesion. However, it has been reported that patients with normal angiographic studies showed microscopic involvement of these arteries up to 44% in the biopsies of arterial anastomotic sites [1].

Conclusions

In young patients with a diagnosis of TA, appropriate medical treatment before surgery is required to establish a successful operation without complications. Recently it has been reported in the literature that adequate control of the disease prior to surgical intervention is related to successful long-term outcomes.

Disclosure

The authors do not have a conflict of interest. The authors have no financial or other interest in the manufacture or distribution of any materials that were used.

References

1. Kerr GS, Hallahan CW, Giordano J, Leavitt RY, Fauci AS, Rottem M, Hoffman GS. Takayasu arteritis. *Ann Intern Med* 1994; 120: 919-929.
2. Liang P, Hoffman GS. Advances in the medical and surgical treatment of Takayasu arteritis. *Curr Opin Rheumatol* 2005; 17: 16-24.
3. Sharma BK, Jain S, Suri S, Numano F. Diagnostic criteria for Takayasu arteritis. *Int J Cardiol* 1996; 54 Suppl: S141-147.
4. Giordano JM. Surgical treatment of Takayasu's disease. *Cleve Clin J Med* 2002; 69 Suppl 2: S1146-148.
5. Khalife T, Alsac JM, Lambert M, Messas E, Duong Van Huyen JP, Brunelval P, Farahmand P, Julia P, Fabiani JN. Diagnosis and surgical treatment of a Takayasu disease on an abdominal aortic dissection. *Ann Vasc Surg* 2011; 25: 556.e1-5.
6. Ando M, Okita Y, Tagusari O, Kitamura S, Matsuo H. A surgically treated case of Takayasu's arteritis complicated by aortic dissections localized in the ascending and abdominal aortae. *J Vasc Surg* 2000; 31: 1042-1045.
7. Lacombe M. Renal and aortic localizations in Takayasu's disease. *Ann Chir* 2002; 127: 268-275.
8. Kalangos A, Christenson JT, Cikirikcioglu M, Vala D, Buerge A, Simonet F, Didier D, Beghetti M, Jaeggi E. Long-term outcome after surgical intervention and interventional procedures for the management of Takayasu's arteritis in children. *J Thorac Cardiovasc Surg* 2006; 132: 656-664.
9. Teoh MK. Takayasu's arteritis with renovascular hypertension: results of surgical treatment. *Cardiovasc Surg* 1999; 7: 626-632.
10. Unal N, Paytoncu S, Saylam GS, Kumtepe S, Kösecik M, Kir M, Akçoral A, Kozan O. Takayasu's arteritis with bilateral renal artery stenosis: unilateral kissing balloon angioplasty. *Int J Cardiol* 2004; 93: 299-300.
11. Kerr GS, Hallahan CW, Giordano J, Leavitt RY, Fauci AS, Rottem M, Hoffman GS. Takayasu's arteritis. *Ann Intern Med* 1994; 120: 919.
12. Sharma S, Gupta A. Visceral artery interventions in Takayasu's arteritis. *Semin Intervent Radiol* 2009; 26: 233-244.