

# A novel stent fixation method for anastomotic leaks after gastrectomy: anchoring of the distal flare to the jejunum by using through-the-scope endoclips

Serdar Şenol<sup>1</sup>, Dursun Burak Özdemir<sup>2</sup>

<sup>1</sup>Gastroenterological Surgery, Samsun Training and Research Hospital, Samsun, Turkey

<sup>2</sup>Surgical Oncology, Samsun Training and Research Hospital, Samsun, Turkey

Gastroenterology Rev 2023; 18 (4): 416–420

DOI: <https://doi.org/10.5114/pg.2022.121045>

**Key words:** anastomotic leak, gastrectomy, self-expandable metal stent, through-the-scope endoclips.

---

**Address for correspondence:** Serdar Şenol MD, Gastroenterological Surgery, Samsun Training and Research Hospital, Samsun, Turkey, phone: 03623111500, e-mail: [serdarardaduru@gmail.com](mailto:serdarardaduru@gmail.com)

## Abstract

**Introduction:** An anastomotic leak is a life-threatening complication after gastrectomy. A fully covered, self-expandable, metal stent (FC-SEMS) can be used as an alternative to traditional surgical re-intervention. However, stent migration can be worrisome.

**Aim:** To evaluate the feasibility and effectiveness of anchoring of the distal flare of the FC-SEMS to the jejunum by using through-the-scope (TTS) endoclips to prevent stent migration.

**Material and methods:** Patients, who received a FC-SEMS capable of being fixed to the jejunum by using TTS endoclips due to an anastomotic leak after gastrectomy, were reviewed retrospectively. Demographic and clinical characteristics, the properties of the deployed stents, and outcomes were evaluated.

**Results:** A total of 7 patients underwent FC-SEMS placement. The mean age was  $59 \pm 13.8$  years, and the mean body mass index was  $29.8 \pm 8.4$  kg/m<sup>2</sup>. All patients' American Society of Anesthesiologists scores were between II and IV. The mean time between gastrectomy and stent insertion was  $6.7 \pm 6.1$  days. Technical success was achieved in all patients. Stent migration was not observed in any of the patients. All but one were removed between 4 and 6 weeks after placement. The mean stent removal time was  $37 \pm 4.6$  days. Complete resolution of the leak was achieved in 6 patients.

**Conclusions:** Anchoring of the distal flare of the FC-SEMS to the jejunum with TTS endoclips is feasible and may reduce the risk of migration. This inexpensive and safe technique may be proposed to patients with factors predictive of FC-SEMS migration.

## Introduction

Anastomotic leakage is the most feared complication after upper gastrointestinal surgery. Both subclinical and symptomatic cases entail an uncertain prognosis and are related with increased morbidity and mortality. The reported incidence is 2.1% to 14.6% [1–4]. The mortality rate was reported up to 50% [2, 4–7].

The traditional, standard approach to treat an anastomotic leak consists of conservative treatment with nil per mouth, abscess drainage, and surgical re-exploration with repair of the anastomosis. However, the high risk of operative morbidity and mortality is a major concern [5].

Fully covered self-expandable metal stents (FC-SEMSs) are one of the pillars of the palliative treatment of oesophageal cancer [8] and are useful for treating

numerous oesophageal diseases, including anastomotic leaks, strictures, perforations, and fistulas after gastroesophageal surgeries [9, 10]. However, despite improvements in design, the migration rates of FC-SEMSs are high [9, 11].

Various methods have been used to prevent stent migration. Proximal flare can be adhered to the oesophageal mucosa by using through-the-scope (TTS) endoclips [12], over the scope clips (OTSC) [10], or endoscopic suture devices [13]. Also it can be adhered to the earlobe or nose using the shim technique [14] and by using a polypectomy snare [15].

## Aim

The aim of the present study was to show that, as a different preventive method, anchoring of the distal

flare of the FC-SEMS to the jejunum by using TTS endoclips is feasible and effective for stent migration.

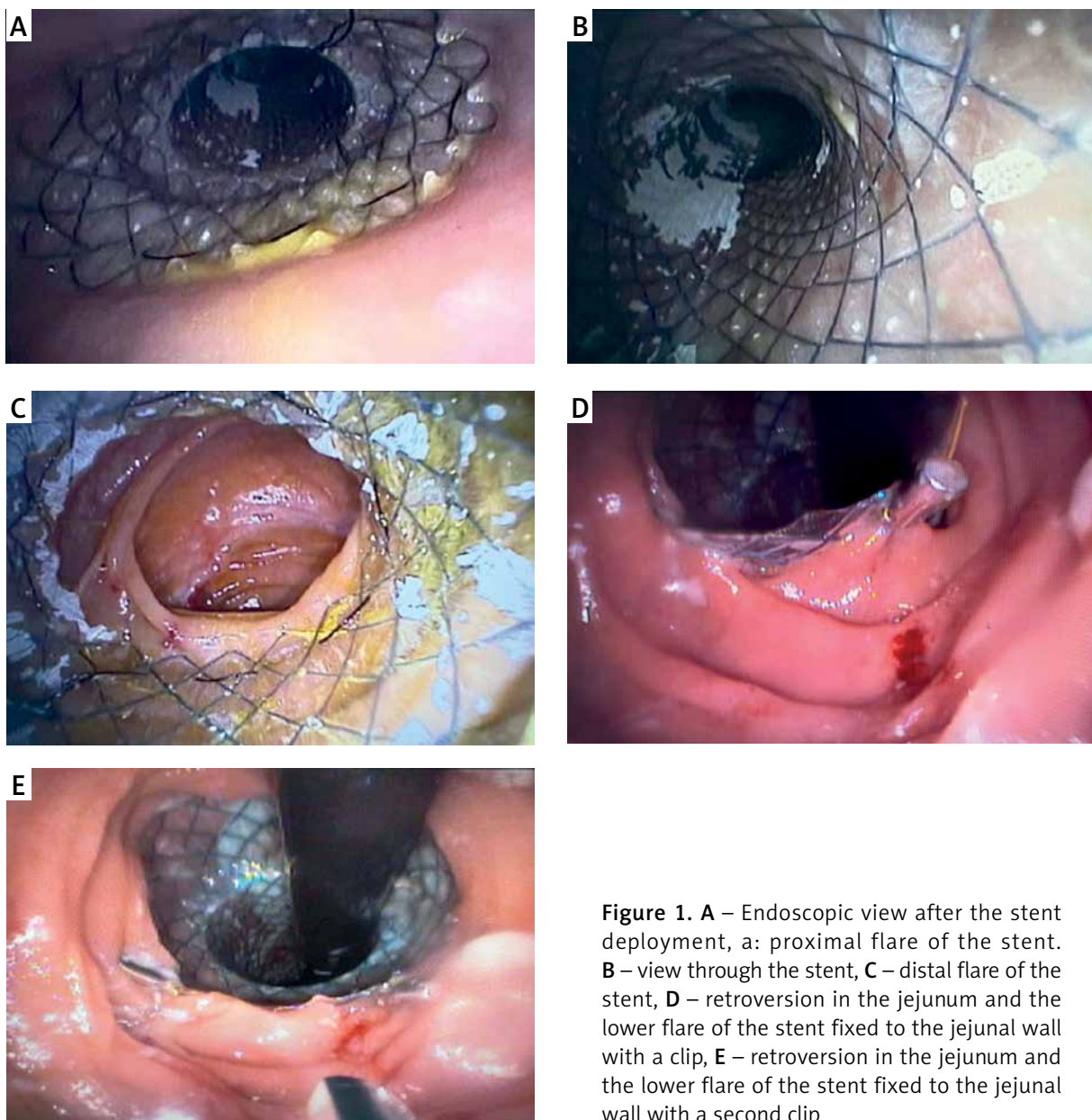
### Material and methods

From July 2020 to June 2022, we retrospectively reviewed the medical records of patients who received a FC-SEMS capable of being fixed to the jejunum by using TTS endoclips for anastomotic leak of the upper gastrointestinal tract, in the Surgical Clinic of Gastroenterology. A total of 7 patients were enrolled to the study. All procedures were performed by a single gastroenterological surgeon. Written informed consent was obtained from all patients before the procedures.

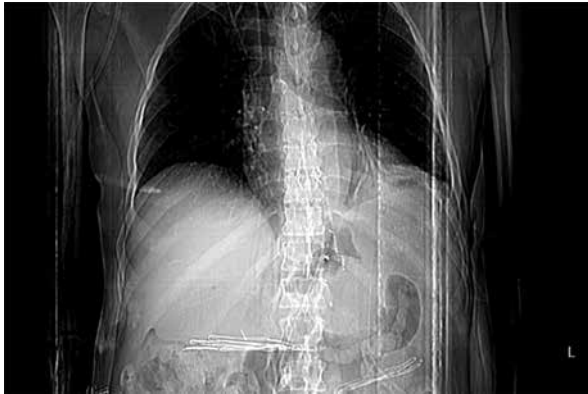The study was approved by the Local Ethics Committee (Number: 2022/6/4).

Their age, sex, body mass index (BMI), and American Society of Anesthesiologists (ASA) score were documented. Underlying causes, performed surgeries, stent indications, time interval between gastrectomy and stent insertion, stent migration, and stent extraction time were evaluated.

All data were recorded in a Microsoft Excel file. Categorical data of the patients are presented as mean  $\pm$  standard deviation. Continuous variables are expressed as number and percentage.



**Figure 1.** A – Endoscopic view after the stent deployment, a: proximal flare of the stent. B – view through the stent, C – distal flare of the stent, D – retroversion in the jejunum and the lower flare of the stent fixed to the jejunal wall with a clip, E – retroversion in the jejunum and the lower flare of the stent fixed to the jejunal wall with a second clip



**Figure 2.** Radiological control of stent position

### Patient management, endoscopic procedure for stent placement, and clipping

The diagnosis of a leak was made by performing a Gastrograffin swallow and endoscopy. Abdominal and chest computed tomography were performed to evaluate the presence of abnormal fluid collection or abscess in the abdominal or thoracic cavity.

The stenting procedure was performed at the operating theatre under general propofol-induced anaesthesia, with tracheal intubation in all cases. The endoscopes used were adult gastroscopes. The upper and lower distance of the fistular orifice was determined by measuring the distance to the incisors. The stents length were 4 to 6 cm longer than the fistular orifice.

After the guidewire was inserted, the delivery system of the stent was gently introduced and the stent deployed. The positioning of the stent was assessed endoscopically by measuring the distance from the distal flare of the stent to the incisors. The lower end of the stent was passed, and a retroversion was performed in the jejunum. The parts where the lower flare of the stent did not fit into the jejunal wall were fixed to the muco-

sa with 1 or 2 endoclips (Figure 1). The distal mobility of the stent was controlled by applying force in the distal direction with forceps. Twenty-four to 48 h after the stenting procedure X-ray imaging or abdominal and chest computed tomography were performed to check that the stent was correctly positioned. Patients with appropriate stent localization (Figure 2) without ileus findings were fed orally with a liquid diet and enteral nutrition.

All stent extractions were performed between 4 and 6 weeks after SEMS placement (Figure 3).

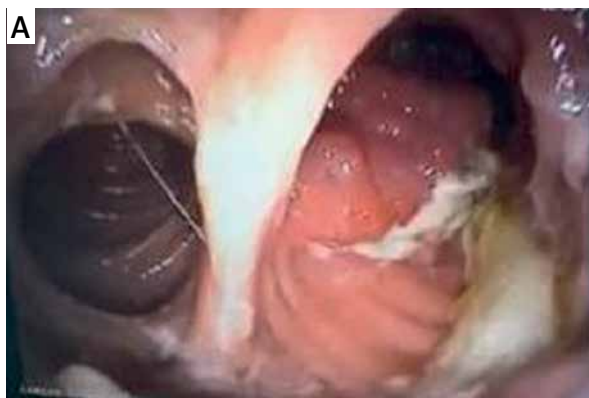## Results

A total of 7 patients (4 male and 3 female) underwent fully covered SEMS placement. The mean age of the patients was  $59 \pm 13.8$  years, and the mean body mass index was  $29.8 \pm 8.4$  kg/m<sup>2</sup>. The American Society of Anesthesiologists (ASA) score was ASA IV in 1 (14.3%) patient, ASA III in 3 (42.85%) patients, and ASA II in 3 (42.85%) patients. The underlying causes, performed surgeries, and stent indications are mentioned in Table I.

The time between gastrectomy and stent insertion was  $6.7 \pm 6.1$  days. Adequate positioning and stent deployment with complete bridging of the leak was achieved in all patients. Stent migration was not observed in any of the patients during the follow-up. One of the 7 patients died due to multiple organ failure and sepsis on postoperative day 5. Except for this case, all stents were removed between 4 and 6 weeks after placement – the mean time was  $37 \pm 4.6$  days. Complete resolution of the leak was achieved in 6 patients. Stent-related perforation, stent migration, and bleeding needing endoscopic intervention or transfusion were not observed (Table II).

## Discussion

Postoperative anastomotic leak after upper gastrointestinal surgery is a serious concern. The mortality



**Figure 3.** Removal of stent: **A** – endoscopic view of anastomosis, **B** – view of the anchored clips over the stent

**Table I.** Demographic and clinical characteristics

No.	Age [year, month]	Gender	Underlying cause	Performed surgery	Stent indication
1	58, 10	Male	Gastric cardia tumour	Total gastrectomy Roux-en-Y oesophagojejunostomy	Anastomotic leak
2	74, 7	Male	Gastric cardia tumour	Total gastrectomy Roux-en-Y oesophagojejunostomy	Anastomotic leak
3	66, 7	Female	Gastric cardia tumour	Total gastrectomy Roux-en-Y oesophagojejunostomy	Anastomotic leak
4	39, 9	Female	Morbid obesity	Roux-en-Y gastric bypass	Anastomotic leak
5	43, 7	Female	Morbid obesity	Roux-en-Y gastric bypass	Anastomotic leak
6	78, 5	Male	Gastric cardia tumour	Total gastrectomy Roux-en-Y oesophagojejunostomy	Anastomotic leak
7	51, 5	Male	Gastric ulcer bleeding	Total gastrectomy Roux-en-Y oesophagojejunostomy	Anastomotic leak

**Table II.** Properties of the applied stents and outcomes

No.	Interval time [day]	Type of stent	Length of stent [mm]	Complication	Migration	Re-stenting	Additional application	Outcome
1	10	Oesophageal fully covered	100	–	–	–	Clips	Alive
2	2	Oesophageal fully covered	80	–	–	–	Clips	Exitus
3	3	Oesophageal fully covered	80	–	–	–	Clips	Alive
4	18	Oesophageal fully covered	120	–	–	–	Clips	Alive
5	2	Oesophageal fully covered	120	–	–	–	Clips	Alive
6	2	Oesophageal fully covered	80	–	–	–	Clips	Alive
7	10	Oesophageal fully covered	100	–	–	–	Clips	Alive

rate is reported to be as much as 50% [2, 4–7]. The traditional standard approach to treat an anastomotic leak consists of abscess drainage and surgical re-exploration with repair of the anastomosis. The high mortality rate of reoperation [5] and, compared with surgical intervention, the FC-SEMS placement's minimal invasiveness, shorter procedure time, the possibility of early oral intake within 1 to 3 days, and the advantage of shorter hospitalization time [16], have made endoscopic stent deployment popular.

When the FC-SEMS is deployed, the nitinol component progressively recovers to its original shape, which results in maximal radial compression force in a period of 24 to 48 h [17]. During this time an increase in repeated oesophageal contractions with a decrease in lower oesophageal sphincter pressure [18, 19] may result stent migration. This requires repeat stenting,

makes the procedure less cost effective, and may result ulcers, bleeding, and perforation.

Several methods for preventing stent migration have been reported. Proximal flare can be adhered to the mucosa by using a TTS endoclip [12], over-the-scope clip (OTSC) [10], or endoscopic suture device [13]. Also, it can be adhered to the earlobe or nose with the shim technique [14] and by using a polypectomy snare [15].

A silk thread attached at the proximal end of the stent, fixed to the nose or ear lobe through the nose is called the shim technique [14]. However, this fixation has not received wide attention to date, and such stents are not easily available. Fixation of the oesophageal stent using a polypectomy snare and affixing it to the patient's earlobe [15] induces nasopharyngeal discomfort and requires hospital surveillance. Although data regarding OTS clipping devices [10] and endoscopic

full-thickness suturing [13] are promising, their use can increase procedural costs by ~\$300–\$800 [20].

So, what fixation technique should be used? Any method used to anchor a fully covered stent should be easy to handle, removable, and cost effective. TTS endoclips, the necessary material for our technique, are widely available in all interventional digestive endoscopic suites. A learning curve is not needed, and the cost is much lower.

The greater distensibility and mobility of the jejunum may facilitate migration of the stent, allowing retroversion with the endoscope. Also, the permanent infoldings of the mucous membrane, the plicae circulares, enable fixation of the stent by using TTS endoclips. Hence, we used TTS endoclips unconventionally for fixation of the distal flare to the jejunum instead of fixation of the proximal flare to the oesophagus. Adequate positioning and stent deployment with complete bridging of the leak was achieved in all patients. Stent migration was not observed in any of the patients during the follow-up.

There are some limitations of this study. First, the present study was retrospective in design. Second, the small sample size of our study may not allow for generalization of the study results.

## Conclusions

Our study shows that anchoring of the distal flare of the fully covered SEMS with TTS endoclips is feasible, and it may reduce the risk of stent migration. This inexpensive and safe technique may be proposed to patients with factors predictive of FC-SEMS migration. These results will of course have to be confirmed in the future by prospective randomized studies.

## Conflict of interest

The authors declare no conflict of interest.

## References

- Viklund P, Lindblad M, Lu M, et al. Risk factors for complications after esophageal cancer resection: a prospective population-based study in Sweden. *Ann Surg* 2006; 243: 204-11.
- Rutegard M, Lagergren P, Rouvelas I, et al. Intrathoracic anastomotic leakage and mortality after esophageal cancer resection: a population-based study. *Ann Surg Oncol* 2012; 19: 99-103.
- Isozaki H, Okajima K, Ichinona T, et al. Risk factors of esophagojejunal anastomotic leakage after total gastrectomy for gastric cancer. *Hepatogastroenterology* 1997; 44: 1509-12.
- Sierzega M, Kolodziejczyk P, Kulig J, et al.; Gastric Cancer Study Group. Impact of anastomotic leakage on long-term survival after total gastrectomy for carcinoma of the stomach. *Br J Surg* 2010; 97: 1035-42.
- Dasari BV, Neely D, Kennedy A, et al. The role of esophageal stents in the management of esophageal anastomotic leaks and benign esophageal perforations. *Ann Surg* 2014; 259: 852-60.
- Csendes A, Burgos AM, Braghetto I. Classification and management of leaks after gastric bypass for patients with morbid obesity: a prospective study of 60 patients. *Obes Surg* 2012; 22: 855-62.
- Kanaji S, Ohyama M, Yasuda T, et al. Can the intraoperative leak test prevent postoperative leakage of esophagojejunal anastomosis after total gastrectomy? *Surg Today* 2016; 46: 815-20.
- Spaander MC, Baron TH, Siersema PD, et al. Esophageal stenting for benign and malignant disease: European Society of Gastrointestinal Endoscopy (ESGE) Clinical Guideline. *Endoscopy* 2016; 48: 939-48.
- van Boeckel PG, Sijbring A, Vleggaar FP, et al. Systematic review: temporary stent placement for benign rupture or anastomotic leak of the oesophagus. *Aliment Pharmacol Ther* 2011; 33: 1292-301.
- Irani S, Baron TH, Gluck M, et al. Preventing migration of fully covered esophageal stents with an over-the-scope clip device (with videos). *Gastrointest Endosc* 2014; 79: 844-51.
- Yang J, Siddiqui AA, Kowalski TE, et al. Esophageal stent fixation with endoscopic suturing device improves clinical outcomes and reduces complications in patients with locally advanced esophageal cancer prior to neoadjuvant therapy: a large multicenter experience. *Surg Endosc* 2017; 31: 1414-9.
- Vanbiervliet G, Filippi J, Karimjee BS, et al. The role of clips in preventing migration of fully covered metallic esophageal stents: a pilot comparative study. *Surg Endosc* 2012; 26: 53-9.
- Kantsevov SV, Bitner M. Esophageal stent fixation with endoscopic suturing device (with video). *Gastrointest Endosc* 2012; 76: 1251-5.
- Shim CS, Cho YD, Moon JH, et al. Fixation of a modified covered esophageal stent: its clinical usefulness for preventing stent migration. *Endoscopy* 2003; 33: 843-8.
- Manes G, Corsi F, Pallotta S, et al. Fixation of a covered self-expandable metal stent by means of a polypectomy snare: an easy method to prevent stent migration. *Dig Liver Dis* 2008; 40: 791-3.
- van Halsema EE, van Hooft JE. Clinical outcomes of self-expandable stent placement for benign esophageal diseases: a pooled analysis of the literature. *World J Gastrointest Endosc* 2015; 7: 135-53.
- Barras C, Myers K. Nitinol – its use in vascular surgery and other applications. *Eur J Vasc Endo Surg* 2000; 19: 564-9.
- Burton PR, Brown W, Laurie C, et al. The effect of laparoscopic adjustable gastric bands on esophageal motility and the gastroesophageal junction: analysis using high-resolution video manometry. *Obes Surg* 2009; 19: 905-14.
- Braghetto I, Lanzarini E, Korn O, et al. Manometric changes of the lower esophageal sphincter after sleeve gastrectomy in obese patients. *Obes Surg* 2010; 20: 357-62.
- Law R, Baron TH. Choosing the appropriate esophageal stent for your patient. *Am J Gastroenterol* 2016; 111: 1669-71.

Received: 11.09.2022

Accepted: 27.09.2022