

QUIZ

WHAT IS YOUR DIAGNOSIS?

Case description

A 13-year-old girl without previous gynaecological history turned up at the emergency department with intense pelvic and abdominal pain, vomiting

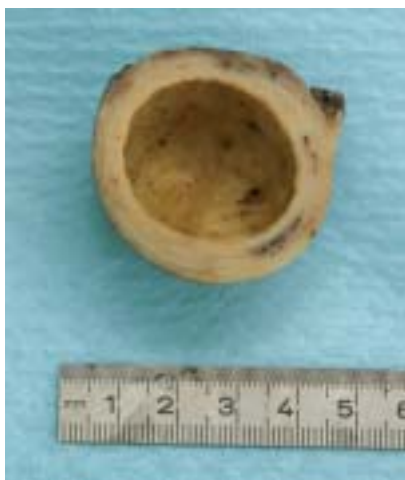

Fig. 1. The macroscopic picture of the material sent for pathological examination

and diarrhoea of two days' duration. On palpation her abdomen was tense and painful. USG demonstrated cystic mass replacing the right ovary. Leukocytosis (WBC) was 19.1×10^9 . Peripheral blood smear showed shift towards neutrophiles (neutrophiles 82%, lymphocytes 11%, monocytes 5%, myelocytes and metamyelocytes 1%). CA-125 level (100.1 U/ml) exceeded three times the reference level.

USG examination revealed normally-sized uterine corpus (4×2.5 cm). The right ovary was replaced by a cystic mass of 4 cm in diameter. The right fallopian tube was not dilated. The left adnexa appeared normal.

The diagnosis of ovarian cyst torsion was made. The patient was referred to the surgery department. The mass was excised and sent for histological examination. The macroscopic picture (Fig. 1) and microscopic findings of the mass (Fig. 2-5) are presented below.

What is your diagnosis?

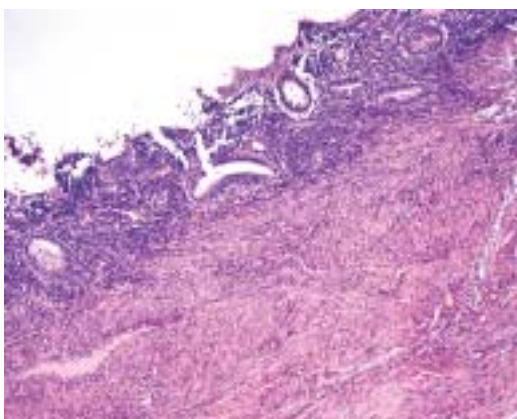
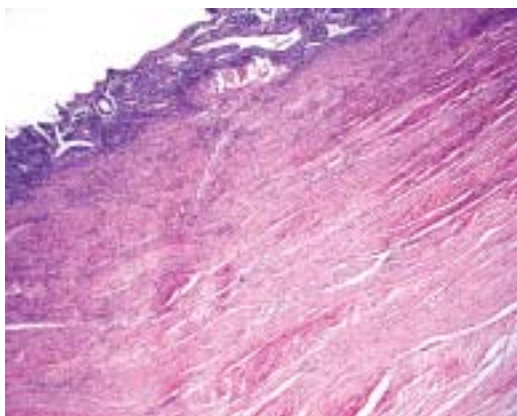


Fig. 2-3. Histological findings (haematoxylin-eosin)

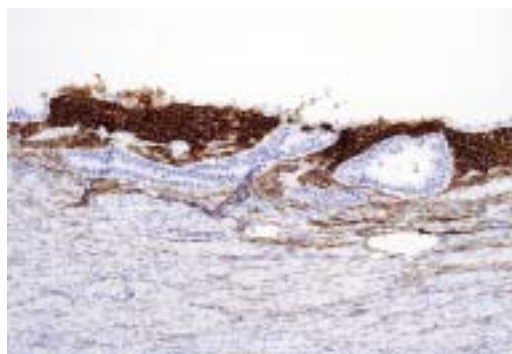


Fig. 4. Immunohistochemistry: CD10

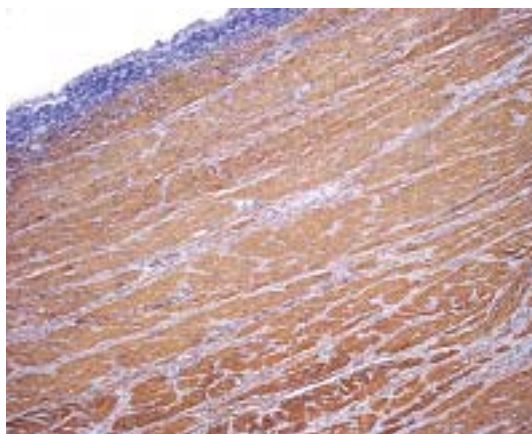


Fig. 5. Immunohistochemistry: SMA

Magdalena Białas¹, Jacek Pająk², Krzysztof Okoń¹, Dariusz Adamek¹

¹Chair and Department of Pathomorphology, Collegium Medicum, Jagiellonian University, Kraków,

²Chair and Department of Pathomorphology, Silesia University, Katowice, ul. Grzegórzecka 16

Answers should be sent to the Editorial Office by 30.09.2010. The correct answer will be announced in the next issue of the *Polish Journal of Pathology*. All participants with the highest number of correct answers to the quizzes published in vol. 61 (4 issues) will be entered into the prize draw for a book.