

# Effects of vitamin B<sub>12</sub> on isolated tubal torsion with ischaemia/reperfusion injury: evaluation with histological and biochemical parameters

Selçuk Kaplan<sup>1</sup>, Ahmet Türk<sup>2</sup>

<sup>1</sup>Department of Gynaecology and Obstetrics, School of Medicine, Adiyaman University Adiyaman, Turkey

<sup>2</sup>Adiyaman University School of Medicine, Department of Histology and Embryology, Adiyaman, Turkey

## Abstract

**Aim:** The aim of this study was to determine the histopathological and biochemical effects of vitamin B<sub>12</sub> on I/R injury in the rat isolated tubal torsion/detorsion model.

**Material and methods:** Twenty-eight rats were divided into a control group (group 1), torsion group (group 2), torsion + detorsion group (group 3), and torsion + detorsion + vitamin B<sub>12</sub> group (group 4). After the experimental procedure, histopathological evaluation was done. Superoxide dismutase (SOD) and glutathione peroxidase (GP-Px) enzyme activities were measured.

**Results:** As a result of histopathological evaluations, tuba uterina tissues were normal in group 1 and group 4. In group 2, epithelial degeneration and abnormal epithelial proliferation, cilia loss, and vascular congestion foci were observed. Histological examination of group 3 showed increased epithelial degeneration and abnormal epithelial proliferation and vascular congestion compared to group 2. There were findings of ischaemia and reperfusion injury in group 2 and group 3. In biochemical examinations, SOD and GSH-Px enzyme levels were significantly increased in group 1 and group 4 compared to group 3 ( $p < 0.05$ ).

**Conclusions:** It has been experimentally demonstrated that vitamin B<sub>12</sub> reduces I/R damage in an isolated tubal torsion rat model. This is the first study on the effectiveness of vitamin B<sub>12</sub> on I/R damage in ITT.

**Key words:** glutathione peroxidase, ischaemia/reperfusion injury, rats, superoxide dismutase, vitamin B<sub>12</sub>.

**Corresponding author:** Assist. Prof. Dr Selçuk Kaplan, Department of Gynaecology and Obstetrics, School of Medicine, Adiyaman University, Atatürk Blv. No: 411, 02200 Merkez/Adiyaman, Turkey, phone: +90-416-223 38 00, fax: +90-416 223 38 36, e-mail: kaplan\_2384@hotmail.com

## Introduction

Isolated tubal torsion (ITT) is characterised by the fallopian tube rotating around itself without the ipsilateral ovary. The incidence is 1 in 1,500,000 adults [1], and it appears less frequently in children and adolescents [2]. Predisposing factors are defined intrinsically and extrinsically for adults. Among these, intrinsic factors are hydrosalpinx, haemosalpinx, tubal neoplasm and abnormal tubal peristalsis; extrinsic factors are paraovarian or paratubal masses, postoperative adhesions, pregnancy, or tumour increase in uterine dimensions [3, 4] and sudden changes in body position [5]. Predisposing factors in children are congenital malformations such as congenital müllerian duct anomalies, long mesosalpinx, and hydatid cysts of Morgagni [6].

A complete rotation of the tubal tissue results in arterial, venous, and lymphatic obstruction [7]. This rotation primarily threatens venous and lymphatic outflow. Accordingly, tubal oedema develops. With the deterioration of arterial nutrition in the next stage, arterial ischaemia and necrosis develop [8].

ITT requires urgent surgical intervention. The current procedure is to detorsion the torsioned tissue, even if it is cyanotic [9]. The detorsioned tissue provides arterial feeding and starts the healing process. Although the return of arterial nutrition removes ischaemic damage, it initiates a new process that can lead to further complications and damage to the tubal tissue. This process is called reperfusion injury.

When ischaemic damage (I) occurs, the main pathophysiological process is an imbalance resulting from the energy requirement. Aerobic metabolism is deactivated, and related damage occurs. Many pathophysiological factors play a role in reperfusion injury (R). These are mainly events such as lipid peroxidation, protein dysfunction, cellular cytoskeletal disruption, cellular integrity disruption, and DNA damage. Free oxygen radicals (FOR) that develop as a result of these events, and cytokines and chemokines involved in the pathways, contribute to the process [10]. In mammals, there is a continuous loop between methionine synthase or betaine homocysteine methyl transferase (BHMT) enzymes, which are essential amino acids, and homocysteine. In this way, accumulation of homocysteine is prevented in the environment. It is known that homocysteine accumulates in many organs such as heart, brain, and kidney and causes ischaemia/reperfusion (I/R) damage [11–13].

The antioxidant properties of vitamin B<sub>12</sub> are due to the stimulation of methionine synthase activity [14], direct reaction with reactive oxygen and nitrogen types, protective effect thanks to the production of glutathione [15], and the effect of signal molecules on modification [16]. Vitamin B<sub>12</sub> and its derivatives (cobalamins) have been reported to exhibit significant antioxidant activity at pharmacological concentrations and provide significant cellular protection against oxidative stress [17]. However, there is no definitive information about the effectiveness of vitamin B<sub>12</sub> on I/R damage developing in ovarian tissue.

The aim of this study was to determine the histopathological and biochemical effects of vitamin B<sub>12</sub> on I/R injury in the rat isolated tubal torsion/detorsion model.

## Material and methods

The experiments in this study were carried out in accordance with the National Institutes of Health animal research guidelines and were approved by our Animal Ethics Committee (Ethics Committee no. 2019/063).

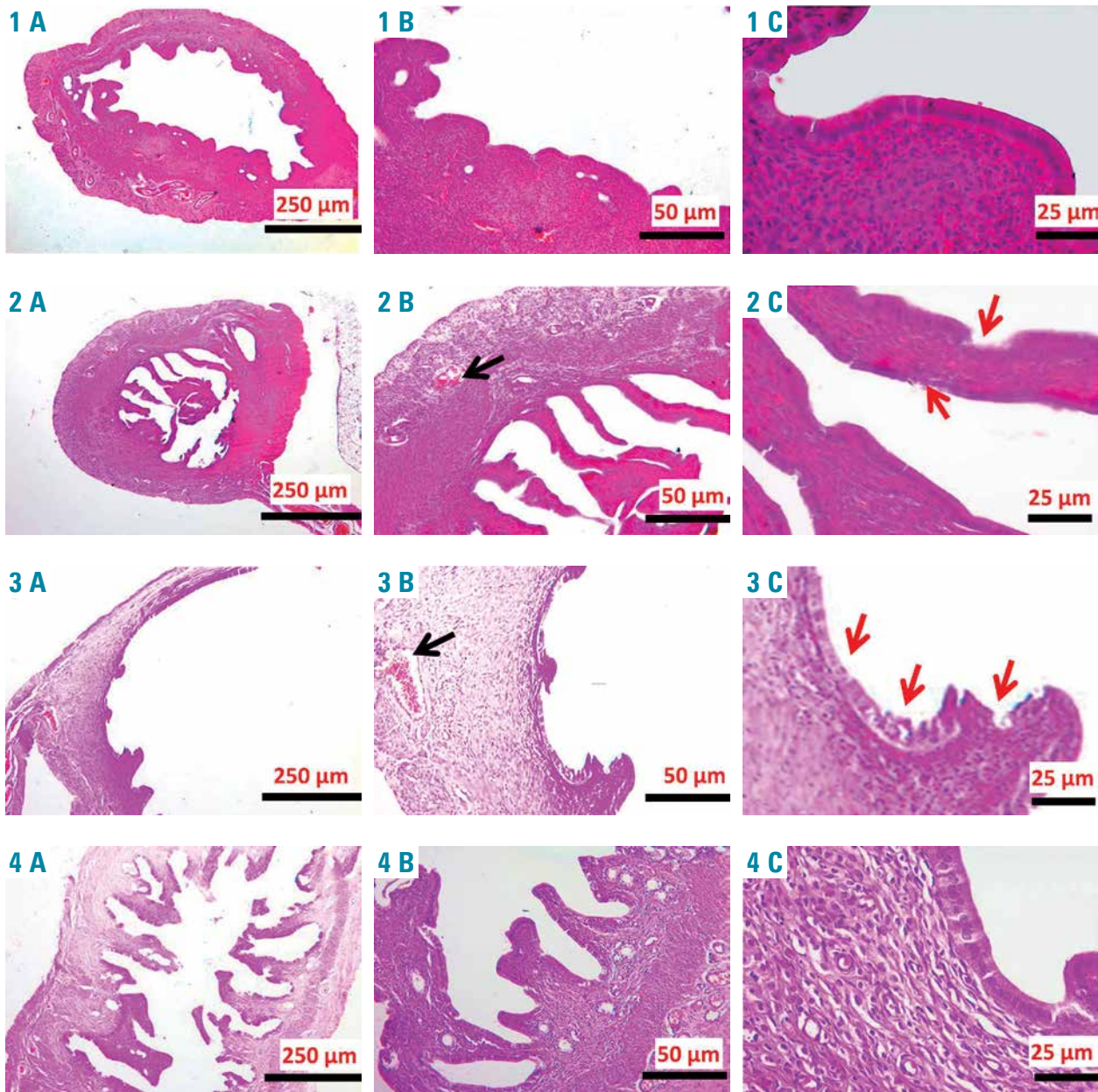
### Animals and experimental protocol

In our study, 28 Wistar albino female rats weighing between 250 and 280 g, 10–12 weeks old, were used in four groups, with seven animals in each group. No procedures were performed for seven days for the adaptation of animals in each group in cages. Rats were housed at 22 ± 20°C room temperature during the adaptation and experiment period, in rooms with 12 h light/12 h dark light cycle, with feed and water *ad libitum*. The live weights of the animals were determined at the beginning and at the end of the study, which would take a total of 4 h. The applications applied to the groups were as follows:

- Group 1 (Sham group) ( $n = 7$ ): after localising the adnex with the right and left uterine horns the abdominal wall was closed with 4-0 nylon sutures. Two hours later, the tubes were removed by relapa-rotomy. Then intra cardiac blood was taken to study oxidative stress parameters.
- Group 2 (torsion) ( $n = 7$ ): to create tubal torsion, vascular clamps were placed approximately 1 cm below the adnexal structure of the right and left tubing and the incision line was closed with 4-0 nylon. Two hours later, relaparotomy was performed and blood and tissue samples required for the study were taken as described in group 1.
- Group 3 (torsion + detorsion) ( $n = 7$ ): after 2 h of tubal torsion, vascular clamps were opened by relaparotomy and the incision line was closed with 4-0 nylon sutures. Reperfusion was allowed for 2 h. After the reperfusion phase, relaparotomy was performed and blood and tissue samples required for the study were taken as described in the group 1.
- Group 4 (torsion + detorsion + vitamin B<sub>12</sub>) ( $n = 7$ ): after 2 h of tubal torsion, vascular clamps were opened by relaparotomy and the incision line was closed, and a 4 mg/kg dose of B<sub>12</sub> was given intraperitoneally and reperfusion was allowed for 2 h. After the reperfusion phase, relaparotomy was performed and blood and tissue samples required for the study were taken as described in group 1. Decapitation was applied to the rats in all groups at the end of the experiment period, and the tissues mentioned in the project were taken and stored in suitable environments.

### Histopathological evaluation

After the experiment, the uterine of the anaesthetised rats were removed and fixed in 10% formaldehyde solution. Then the tissues were routinely inserted and passed through the series, embedded in paraffin blocks, 4–5 µm sections were taken and stained with haematoxylin-eosin. The prepared preparations were examined under a Leica DM500 microscope and semi-quantitatively evaluated and photographed (Leica DFC295) (Figure 1).



**Figure 1.** Epithelial degeneration and abnormal epithelial proliferation, cilia loss (red arrow) and vascular congestion foci were observed in group 2 (2 A–C). Histological examination of group 3 (3 A–C) showed that epithelial degeneration and abnormal epithelial proliferation (red arrow) increased and vascular congestion increased (black arrow) compared to group 2

### Biochemical examination

Fallopian tube tissue samples stored at  $-20^{\circ}\text{C}$ , glutathione peroxidase (GSH-Px), and superoxide dismutase (SOD) rat GSH-Px ELISA kit for enzyme activity (Rel Assay Diagnostics, Bursa, TURKEY, lot # 201903) and rat SOD ELISA kit (Assay Rel Diagnostics, Bursa, TURKEY, lot # 201903), respectively, were read as described above at 450 nm wavelength on an ELISA reader (BioTek ELISA ELX800, BioTek Instruments, USA). The results are expressed in ng/ml.

### Statistical analysis

SPSS software 22 was employed for the statistical analysis (SPSS Inc., Chicago, IL). Mean and standard deviation

descriptive statistical methods were used. The differences among the four groups were evaluated by one-way ANOVA (Tukey analysis) and Kruskal-Wallis (Tamhane analysis) test. A  $p < 0.05$  level was considered statistically significant.

## Results

### Histopathological findings

The tuba uterina tissue of the experimental groups stained with haematoxylin-eosin is shown in Figure 1 at different magnifications.

Tuba uterina tissues were normal in groups 1 and 4. In group 2, epithelial degeneration and abnormal epithelial

**Table I.** Glutathione peroxidase (GSH-Px) and superoxide dismutase (SOD) mean values and standard deviation rates are given

Group	SOD	GSH-Px	P-value
1	2.41 ±0.21	0.21 ±0.05	< 0.001
2	1.15 ±0.05	0.14 ±0.03	< 0.001
3	0.91 ±0.11	0.08 ±0.02	< 0.001
4	2.47 ±0.14	1.60 ±0.15	< 0.001

proliferation, cilia loss, and vascular congestion foci were observed. Histological examination of group 3 showed increased epithelial degeneration, abnormal epithelial proliferation, and vascular congestion compared to group 2 (Figure 1).

### Biochemical findings

GSH-Px values and SOD values are given in Table I. GSH-Px and SOD values were measured at the lowest level in group 2 and were increased in group 3. In group 4, these values were the highest (Figure 2). The values between the groups show statistically significant differences ( $p < 0.001$ ) (Table I).

When the relationship between SOD values between the groups was analysed statistically, the values between group 1 and group 3 were significantly different ( $p = 0.001$ ). In addition, SOD values between group 3 and group 4 showed a statistically significant difference ( $p < 0.001$ ) (Table II).

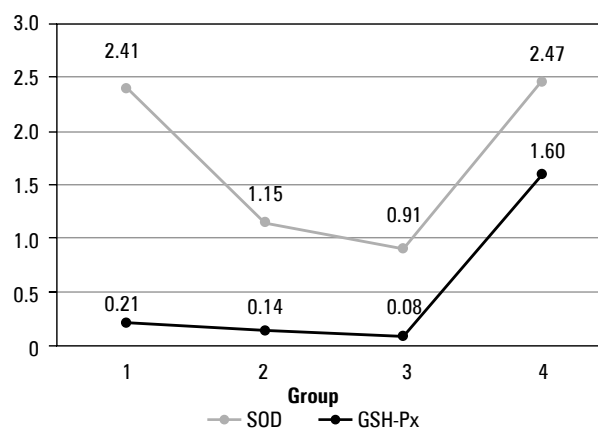
In the comparison of GSH-Px values according to the groups, there was a significant difference between group 1 and group 3 ( $p = 0.034$ ), group 3 and group 4 ( $p < 0.001$ ), and between group 2 and group 4 ( $p = 0.012$ ) (Table III).

**Table II.** Analysis of differences in superoxide dismutase (SOD) values between groups with Kruskal-Wallis  $H$  test

	Test statistic	Std. error	Std. test statistic	Sig.	Adj. sig.
Group 1–Group 4	-1.571	4.396	-0.357	0.721	1.000
Group 2–Group 3	7.000	4.396	1.592	0.111	0.668
Group 1–Group 2	9.714	4.396	-2.567	0.027	0.163
Group 2–Group 4	-11.286	4.396	-2.567	0.010	0.062
Group 1–Group 3	16.714	4.396	3.802	0.000	0.001
Group 2–Group 4	-18.286	4.396	-4.159	0.000	0.000

**Table III.** Analysis of differences in glutathione peroxidase GSH-Px values between groups with Kruskal-Wallis  $H$  test

	Test statistic	Std. error	Std. test statistic	Sig.	Adj. sig.
Group 1–Group 3	6.714	4.393	1.528	0.126	0.758
Group 1–Group 3	12.143	4.393	2.764	0.006	0.034
Group 3–Group 4	-20.286	4.393	-4.618	0.000	0.000
Group 1–Group 2	5.429	4.393	1.236	0.217	1.000
Group 2–Group 4	-13.571	4.393	-3.090	0.002	0.012
Group 1–Group 4	-8.143	4.393	-1.854	0.064	0.383

**Figure 2.** Line graph showing the change of superoxide dismutase (SOD) and glutathione peroxidase (GSH-Px) values by groups

### Discussion

In this study, antioxidant effects of vitamin B<sub>12</sub> were investigated in I/R damage in a rat ITT model. In histopathological examination, increased epithelial degeneration and abnormal epithelial proliferation in group 2 was indicative of vascular changes developing in torsioned tissue. In addition, epithelial degeneration, abnormal epithelial proliferation, and increased vascular congestion compared to group 2 in group 3 support the changes associated with reperfusion injury. In contrast, the histopathological data in group 4 are similar to those of group 1, which supports the positive effect of vitamin B<sub>12</sub> on histopathological findings.

In the biochemical analysis, GSH-Px and SOD values were the lowest in group 2 and the highest in group 4 in the analysis of GSH-Px values and SOD values. This is another indicator of the antioxidant effects of vitamin B<sub>12</sub>. In the evaluation of SOD values between the groups, the SOD values

in group 3 were significantly lower than those in group 1. This finding is a biochemical indicator of reperfusion injury caused by detorsion. Likewise, GSH-Px values were quite low in group 3 compared to group 1. Again, it was higher in group 4 compared to both group 2 and group 3. All these findings show the antioxidant effects of vitamin B<sub>12</sub> and support our hypothesis. According to the authors' knowledge, this study is the first study in which isolated tubal torsion was performed experimentally and antioxidant effects of vitamin B<sub>12</sub> were shown in I/R damage.

The first treatment option for isolated tubal torsion is surgical detorsion. Revascularization of tissue after ITT detorsion can trigger damage known as ischaemia/ reperfusion injury. Many events that cause tissue damage and cell death occur in tissues whose vascular supply has been lost. This loss in vascular nutrition decreases intracellular ATP levels and causes the accumulation of an-aerobic metabolism products. Accordingly, the use of anaerobic energy also increases. When reperfusion occurs, it can break the anaerobic cycle with blood coming into the tissue. However, reintroduction of oxygen and energy into the cell in which the anaerobic environment is formed can lead to cellular free radical formation, migration of cytokines and leukocytes, activation of the pro-apoptotic signal pathway, and consequently cell damage. All these processes are called ischaemia/ reperfusion injury [10].

In an *in vitro* study of aortic endothelial cells, cyano-co-balamin concentrations (B<sub>12</sub> supplement form) were shown to cause a decrease in SOD levels in mitochondria and cyto-plasm [18]. In a systematic evaluation of studies on vitamin B<sub>12</sub> and oxidative stress, vitamin B<sub>12</sub> deficiency was shown to be associated with both increased oxidants and decreased antioxidants compared to normal vitamin B<sub>12</sub> values [19].

Vitamin B<sub>12</sub> may increase SOR excretion by maintaining glutathione (GSH) levels [20]. Antioxidant enzymes SOD and GSH-Px activities have been shown to decrease in B<sub>12</sub> deficiency [21]. Many studies have shown that H<sub>2</sub>O<sub>2</sub> decreases in vitamin B<sub>12</sub> deficiency. SOD inhibits H<sub>2</sub>O<sub>2</sub>. It is stated that there is an accumulation of H<sub>2</sub>O<sub>2</sub> due to SOD decrease in vitamin B<sub>12</sub> deficiency [22–24]. In our study, the increase of SOD values in the group using vitamin B<sub>12</sub> supports this data.

GSH is an important antioxidant. It is a substrate for the GSH-Px enzyme that catalyses the detoxification of H<sub>2</sub>O<sub>2</sub> and other peroxides. In this way, it plays an important role in defending free oxygen radicals effectively [21]. In our study, the increase in GSH-Px activity in the rat group given vitamin B<sub>12</sub> shows the antioxidant effect of vitamin B<sub>12</sub> and supports these data.

## Conclusions

As a result, it has been experimentally demonstrated that vitamin B<sub>12</sub> reduces I/R damage in an isolated tubal torsion rat model. Wider clinical studies should be conducted to investigate the effectiveness of vitamin B<sub>12</sub> in the treatment of I/R damage of isolated tubal torsion. According to

the information of the authors, it is the first study on the effectiveness of vitamin B<sub>12</sub> on I/R damage in ITT.

## Conflict of interest

The authors declare no conflict of interest.

## References

- Shalini R, Shaili N, Neerja G. Fallopian tube torsion: a rare emergency. *J Gynecol Surg* 2011; 27: 41.
- Casey RK, Damle LF, Gomez-Lobe V. Isolated Fallopian tube torsion in pediatric and adolescent females: a retrospective review of 15 cases at a single institution. *J Pediatr Adolesc Gynecol* 2013; 26: 189-92.
- Youssef AF, Fayad MM, Shafeek MA. Torsion of the fallopian tube. *Acta Obstet Gynecol Scand* 1962; 41: 292-309.
- Provost RW. Torsion of the normal Fallopian tube. *Obstet Gynecol* 1972; 39: 80-82.
- Romano M, Di Giuseppe J, Serri M, et al. A possible association between sports and isolated fallopian tube torsion in children and adolescent females. *Gynecol Endocrinol* 2015; 31: 688-92.
- Bernardus RE, Van der Slikke JW, Roex AJ, et al. Torsion of the Fallopian tube: some consideration on its etiology. *Obstet Gynecol* 1984; 64: 675-8.
- Hiller N, Appelbaum L, Simanovsky N, Lev-Sagi A, Aharoni D, Sella T. CT features of adnexal torsion. *Am J Roentgenol* 2007; 189: 124-9.
- Abraham M, Keyser EA. Adnexal torsion in adolescents. *The American College of Obstetricians and Gynecologists* 2019; <https://www.acog.org/clinical/clinical-guidance/committee-opinion/articles/2019/08/adnexal-torsion-in-adolescents>.
- Huchon C, Fauconnier A. Adnexal torsion: a literature review. *Eur J Obstet Gynecol Reprod Biol* 2010; 150: 8-12.
- Wu MY, Yiang GT, Liao WT, et al. Current mechanistic concepts in ischemia and reperfusion injury. *Cell Physiol Biochem* 2018; 46: 1650-67.
- Caylak E, Aytakin M, Halifeoglu I. Antioxidant effects of methionine, α-lipoic acid, N-acetylcysteine and homocysteine on lead-induced oxidative stress to erythrocytes in rats. *Exp Toxicol Pathol* 2008; 60: 289-94.
- Calvert JW, Elston M, Nicholson CK, et al. Genetic and pharmacologic hydrogen sulfide therapy attenuates ischemia-induced heart failure in mice. *Circulation* 2010; 122: 11-9.
- Ren C, Du A, Li D, Sui J, Mayhan WG, Zhao H. Dynamic change of hydrogen sulfide during global cerebral ischemia-reperfusion and its effect in rats. *Brain Res* 2010; 1345: 197-205.
- McCaddon A, Regland B, Hudson P, Davies G. Functional vitamin B12 deficiency and Alzheimer disease. *Neurology* 2002; 58: 1395-9.
- Kräutler B. Vitamin B12: chemistry and biochemistry. *Biochem Soc Trans* 2005; 33: 806-10.
- Veber D, Mutti E, Gammella ET, Tredici G, Scalabrino G. Indirect down-regulation of nuclear NF-κB levels by cobalamin in the spinal cord and liver of the rat. *J Neurosci Res* 2008; 86: 1380-7.
- Birch CS, Brasch NE, McCaddon A, Williams JHH. A novel role for vitamin B12: cobalamins are intracellular antioxidants *in vitro*. *Free Radical Biol Med* 2009; 47: 184-8.
- Moreira ES, Brasch NE, Yun J. Vitamin B12 protects against superoxide-induced cell injury in human aortic endothelial cells. *Free Radic Biol Med* 2011; 51: 876-83.

19. Van de Lagemaat EE, Groot L, Heuvel E. Vitamin B12 in relation to oxidative stress: a systematic review. *Nutrients* 2019; 11: E482.
20. Karamshetty V, Acharya JD, Ghaskadbi S, Goel P. Mathematical modeling of glutathione status in type 2 diabetics with vitamin B12 deficiency. *Front Cell Dev Biol* 2016; 4: 16.
21. Bito T, Misaki T, Yabuta Y, Ishikawa T, Kawano T, Watanabe F. Vitamin B12 deficiency results in severe oxidative stress, leading to memory retention impairment in *Caenorhabditis elegans*. *Redox Biol* 2017; 11: 21-9.
22. Allan BD, Alessandra C, Christopher ML, Jennifer D. Evidence that amyloid beta-peptide-induced lipid peroxidation and its sequelae in Alzheimer's disease brain contribute to neuronal death. *Neurobiol Aging* 2002; 23: 655-64.
23. Allan BD, Christopher ML. Lipid peroxidation and protein oxidation in Alzheimer's disease brain: potential causes and consequences involving amyloid betapeptide-associated free radical oxidative stress. *Free Radic Biol Med* 2002; 32: 1050-60.
24. Jia MZ, Domenico P. Acceleration of brain amyloidosis in an Alzheimer's disease mouse model by a folate, vitamin B6 and B12-deficient diet. *Exp Gerontol* 2010; 45: 195-201.