

In the report the authors present changes in the masticatory organ in the case of a 9-year-old girl affected with Recklinghausen's disease. The characteristics included neurofibromatosis of the face, salivary gland and external ear in the form of an extensive tumour. The disease also resulted in acute right hemifacial hypertrophy. The computer-assisted tomography examination identified acute atrophy of the zygomatic bone, maxilla, mandible alveolar ridge and right base of the skull. The clinical intraoral examination of the patient revealed right buccal occlusion and lingual occlusion on the opposite side. The patient underwent functional orthodontic treatment of the co-existing malocclusion with an orthodontic appliance for the upper and lower jaw which was to prevent further mandible movement towards the right. According to researchers, neoplasia is an inherent characteristic of a phenotype seen in patients suffering from Recklinghausen's disease. Therefore, it is the main factor influencing the selection of a therapy. Although there are certain single attempts of pharmacological treatment of ganglioneurofibromas at their early development stage, it is agreed that, in fact, no preventive actions are possible. Hence, in the case of neurofibromatosis type 1, reconstruction and aesthetic procedures are widely applied in treating the disease.

Key words: orthodontic treatment, neurofibromatosis, functional appliances, hypertrophy of the mandible.

Changes in the masticatory organ in patients with Recklinghausen's disease – a case report

Przemysław Kopczyński, Rafał Flieger, Teresa Matthews-Brzozowska

Poznan University of Medical Sciences, Poznan, Poland

Introduction

Medical literature defines Recklinghausen's disease, also known as neurofibromatosis type 1 (NF1), as an autosomal dominant disease characterised by abnormalities affecting tissues derived from the neural crest. Researchers indicate that the disease is directly caused by mutation of the neurofibrin 1 gene located on chromosome 17q11.2 [1]. Studies carried out by doctors from France and Finland show that benign neurofibromatosis type 1 is connected with homozygosity of constitutional mutations in one of the genes responsible for DNA repair by way of deleting unpaired nucleotides such as MLH1, MSH2, MSH6 and PMS2 [2, 3]. Recklinghausen's disease is diagnosed when at least 2 out of the 7 following criteria are met: first degree relative afflicted with neurofibromatosis type 1, min. 6 café-au-lait spots with a diameter exceeding 5 mm (children) and 15 mm (adults), min. 2 neurofibromas of any type or one plexiform neurofibroma, freckles and/or discolouration found on covered parts of the body, optic nerve glioma, min. two Lisch nodules as well as characteristic bone lesion such as sphenoid wing dysplasia or thinning of the long bone cortex [4].

According to a study carried out in 2007, the differential diagnosis of NF1 should focus on excluding such disorders as rare mosaic or segmental neurofibromatosis type 1, neurofibromatosis type 2, schwannomatosis, Noonan syndrome, Watson phenotype, café-au-lait spots inherited as an autosomal dominant condition, autosomal dominant McCune-Albright syndrome, LEOPARD syndrome, Klippel-Trénaunay syndrome, Proteus syndrome, multiple lipomas, Bannayan-Riley-Ruvalcaba syndrome, fibromatosis, multiple endocrine neoplasia syndrome type 2B as well as homozygosity for one of the genes responsible for causing hereditary non-polyposis cancer of the colon [5].

The study aimed at identifying changes in the masticatory organ and specifying possibilities of orthodontic treatment of a patient suffering from Recklinghausen's disease.

Case study

The present study describes a case of a 9-year-old girl suffering from Recklinghausen's disease with neurofibromatosis of the face, salivary gland and external ear in the form of an extensive tumour. In consequence, acute right hemifacial hypertrophy was identified. The extraoral examination of facial features revealed that the central part of the chin had moved towards the unaffected side of the face, while the angle of the mouth lowered significantly towards the affected side of the face (Fig. 1A–C). The clinical intraoral examination of the patient revealed right buccal occlusion and lingual occlusion on the opposite side (Fig. 2). The computer-assisted tomography examination identified acute atrophy of the maxilla, zygomatic bone, mandible alveolar ridge and right base of the skull (Fig. 3A, B). Despite a number of surgical procedures aimed at removing the tumour (the first procedure was when the patient was

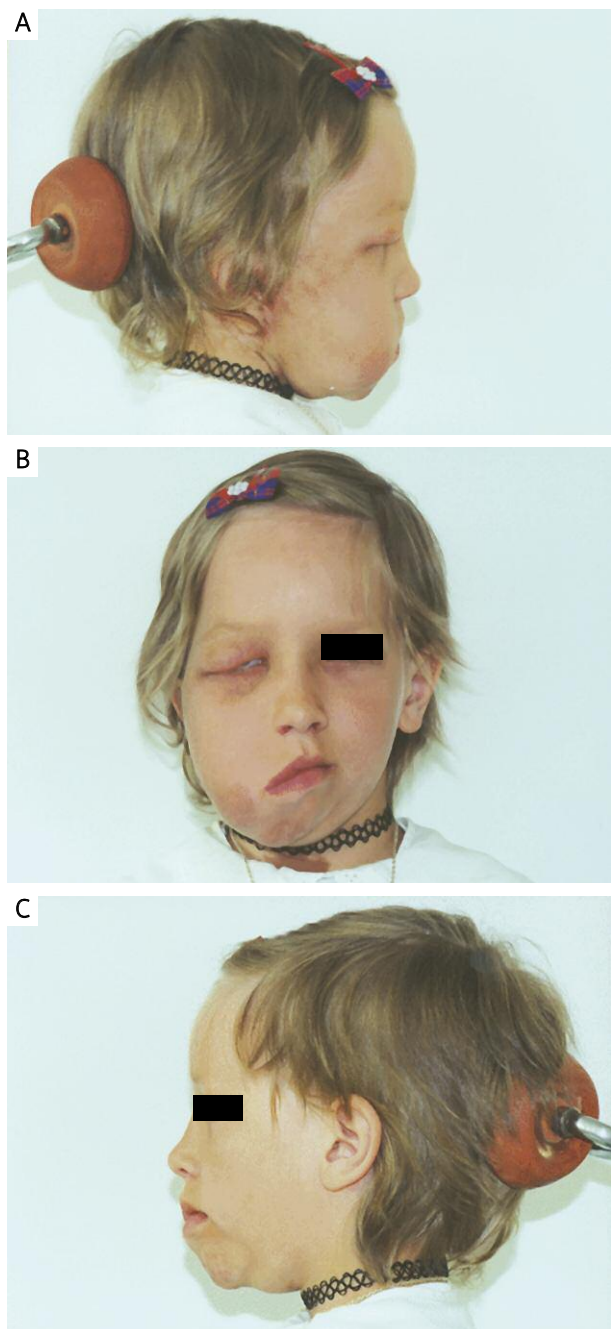


Fig. 1A–C. Extraoral photographs of the patient

6 years old), the tumour kept recurring. The patient received orthodontic treatment of the co-existing malocclusion which was to prevent further mandible movement towards the right-hand side of the face – a Metzelder appliance (removable orthodontic appliance for the upper and lower jaw) was used. Once placed in the mouth, this functional appliance forced proper placement of the mandible versus the maxilla. The proper spatial relation between the mandible and maxilla was specified and recorded with a construction bite. The treatment lasted 3 years, yet although the appliance was used conscientiously by the patient, no significant clinical improvement was identified.

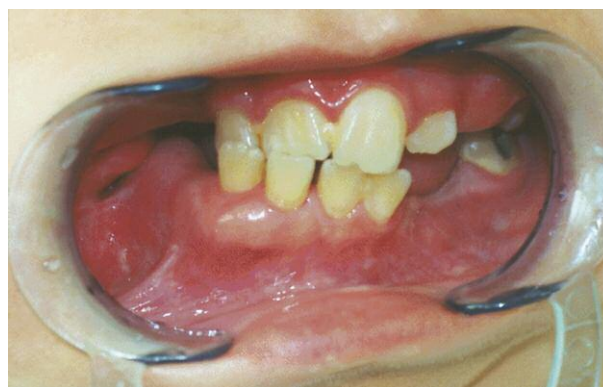

Fig. 2. Intraoral photograph of the patient

Discussion

According to researchers, neoplasia is an inherent characteristic of a phenotype seen in patients suffering from Recklinghausen's disease; therefore, it is the main factor influencing the selection of a therapy. Although there are certain single attempts of pharmacological treatment of ganglioneurofibromas at their early development stage, it is agreed that, in fact, no preventive actions are possible. Hence, in the case of neurofibromatosis type 1, reconstruction and aesthetic procedures are widely applied in treating the disease [6]. The aim of the orthodontic appliance used in the present case was, among others, to improve facial features by making a functional change in the position of the mandible.

Recklinghausen's disease in the oral cavity often manifests with gingival overgrowth, erosions, increased proneness to caries and to attachment loss due to problems with maintaining proper hygiene. Another phenomenon observed in the disease is a lack of teeth buds, teeth migration or intrusion. It is often underlined that until the skeletal development is complete, prosthetic restorations which could impact bone growth should not be used. The best solution seems to be the one offered by temporary restorations, the use of which should be consulted with an orthodontist. It was also suggested that in many cases orthodontic treatment suffices, as restoration may be combined with the treatment of existing malocclusion using orthodontic appliances. The appliances should be constructed with consideration to the missing teeth and they should restore them, prevent teeth migration, maintain space for erupting permanent teeth, restore correct articulation and occlusal conditions and stimulate maxilla and mandible bone development [7]. In the case of the described patient, orthodontic treatment with the removable appliance prevented further intensification of the malocclusion and it was not necessary to introduce any other elements to the Metzelder appliance.

Surgical treatment of a patient with a hemimandibular hyperplasia was conducted in the Maxillo-Facial Surgery Department in Poznań. The 18-year-old patient with right hemimandibular hyperplasia underwent (based on pre-operative and operative measurements) a correction procedure – sagittal mandibular osteotomy at the side of the hyperplasia combined with dissection of the inferior alveolar nerve and genioplasty. Additionally, sagittal split osteotomy of the mandible was conducted on the opposite side. The correction of the occlusion involved Le Fort I osteotomy [8].

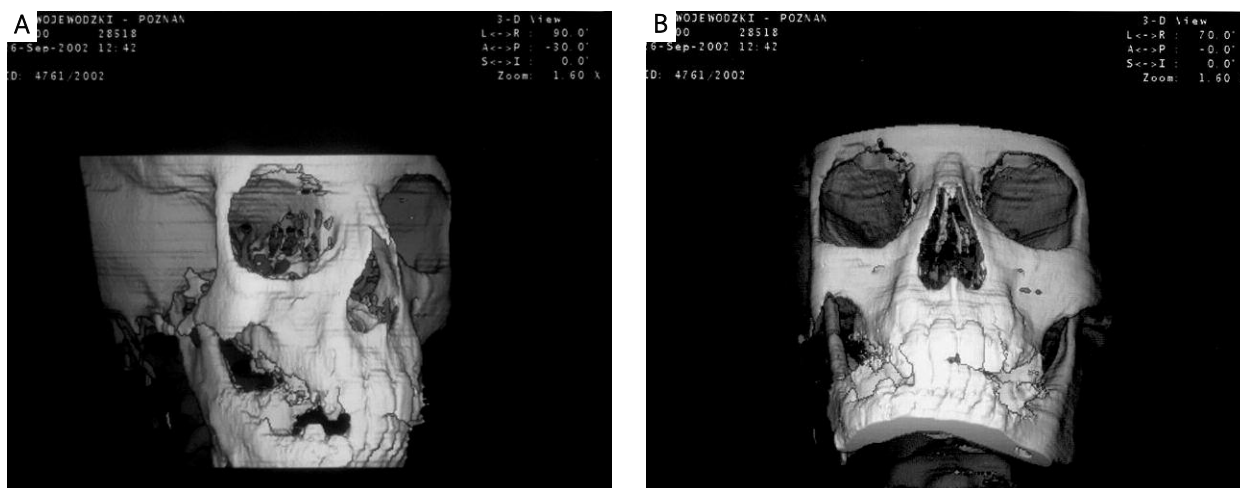


Fig. 3A, B. Computer-assisted tomography image of patient's skull

In the analysed case, the hyperplasia was caused by a neoplastic tumour. The surgical action consisted in its enucleation, but despite the procedure relapses occurred requiring repeated surgical procedures.

Studies conducted in 2007 suggested that in the case of children suffering from Recklinghausen's disease deciduous teeth erupt earlier. Researchers explained this phenomenon by the activity of osteoclasts, which are more prone to migrate and proliferate in comparison with the cells of healthy individuals. This leads to a faster alveolar process of bone resorption around deciduous teeth buds and thus earlier eruption of the teeth [9]. The applied orthodontic appliance, owing to its construction, could be used by the patient during the entire process of the functional treatment, regardless of the presence of particular teeth during the teeth replacement stage and did not inhibit the functioning of the masticatory organ. During visits to the orthodontic surgery, special surfaces in the acrylic mass of the appliance were prepared to enable uninhibited eruption of permanent teeth.

Finnish scientists made a groundbreaking discovery of a sex-dependent characteristic in the case of patients suffering from neurofibromatosis type 1. Based on an analysis of pantomographic images of 55 patients (29 women and 26 men), the scientists proved that cement dysplasia around lower teeth root apices affects only women. Additionally, they also pointed to the fact that 85% of cases showed enlargement of the mandibular foramen and canal. Although the changes often accompany plexiform tumours located in this area, it is a characteristic of Recklinghausen's disease and may be taken into consideration in differential diagnostics also in cases in which neoplastic changes are not present in those anatomical areas [10]. Radiological testing of the patient showed no dysplastic cement changes around teeth roots, but it did show slightly enlarged mandibular foramina and canals.

Summary

Considering the malocclusion they are suffering from, children diagnosed with Recklinghausen's syndrome should undergo orthodontic consultation and, if necessary, should

be treated using removable appliances, so that the malformation of the masticatory organ does not intensify.

The authors declare no conflict of interest.

References

- Wallace MR, Marchuk DA, Andersen LB, Letcher R, Odeh HM, Saulino AM, Fountain JW, Brereton A, Nicholson J, Mitchell AL, et al. Type 1 neurofibromatosis gene: identification of a larger transcript disrupted in three NF1 patients. *Science* 1990; 13: 181-6.
- Puisieux A. HNPCC syndrome, microsatellite instability and NF1 gene alteration. *Bull Cancer* 1999; 86: 812-4.
- Raevaara TE, Gerdes AM, Lönnqvist KE, Tybjaerg-Hansen A, Abdel-Rahman WM, Kariola R, Peltomäki P, Nyström-Lahti M. HNPCC mutation MLH1 P648S makes the functional protein unstable, and homozygosity predisposes to mild neurofibromatosis type 1. *Genes Chromosomes Cancer* 2004; 40: 261-5.
- Pinson S, Wolkenstein P. Neurofibromatosis type 1 or Von Recklinghausen's disease. *LaRevue de Médecine Interne* 2005; 26: 196-215.
- Karwacki M, Woźniak W. Włóknakiowatość – wrodzona, genetycznie uwarunkowana choroba predysponująca do nowotworzenia. *Medycyna Wieku Rozwojowego* 2006; 10: 923-46.
- Ferner RE. Neurofibromatosis 1. *Eur J Hum Genet* 2007; 15: 131-8.
- Bączkowski B, Wojtyńska E, Niestuchowska M, Mierzińska-Nastalska E. Leczenie protetyczne pacjentów młodocianych z chorobą Recklinghausena. *Opis przypadku. Protet Stomatol* 2006; 56: 300-4.
- Osmola K. Rozszerzona osteotomia strzałkowa w leczeniu połowicznego przerostu żuchwy – opis przypadku. *Czas Stomatol* 2006; 59: 799-804.

Address for correspondence

Rafał Flieger

Bukowska 70

60-812 Poznań

e-mail: gabinet6@op.pl

Submitted: 12.04.2011

Accepted: 28.03.2012