

Mesentery fibromatosis, also called abdominal desmoid, is a rare clinical entity. It is part of the clinical-pathologic spectrum of so-called deep fibromatoses. The deep fibromatoses encompass a group of benign fibroproliferative processes that are locally aggressive; they may infiltrate the adjacent organs or recur, but do not create distant metastatic lesions. The small bowel mesentery is the most common site of intraabdominal fibromatosis. However, the omentum, ileocolic mesentery, transverse or sigmoid mesocolon, or ligamentum teres may be the site of origin for intraabdominal fibromatosis. Mesenteric fibromatosis occurs in a wide age range of patients, and has no gender or race predilection. Most cases of abdominal fibromatosis occur sporadically. In this article we would like to present a case report of a patient who was admitted to the clinic due to severe abdominal pain with clinically advanced peritoneal signs. The intraoperative findings were astonishing; we found a giant desmoid which originated in the mesentery. The tumor oppressed the ileum, leading to its obstruction.

Key words: acute abdomen, mesentery fibromatosis, abdominal desmoid.

Contemp Oncol (Pozn) 2013; 17 (5): 468–469
DOI: 10.5114/wo.2013.37224

Giant mesentery fibromatosis presenting as acute abdomen – case report

Piotr Misiak, Łukasz Piskorz, Szymon Wciśło, Sławomir Jabłoński, Marian Brocki

Department of Chest Surgery, General and Oncological Surgery, University Hospital No. 2, Medical University of Lodz, Poland

Introduction

Mesentery fibromatosis, also called intraabdominal fibromatosis or abdominal desmoid, is a rare clinical entity. This kind of tumor is usually benign but locally aggressive. It is notorious if surgical resection is incomplete. The tumor may infiltrate the adjacent organs but does not create distant metastatic lesions. This histologically benign tumor belongs to the fibrous variety of primary solid tumors of the mesentery. In the early stages the disease is asymptomatic; however, the constantly enlarging tumor leads to compression of the adjacent gut, which ends up usually as an ileus. Most intraabdominal desmoids arise in the mesentery of the small bowel [1–3] but fibromas have been reported in the gastro-hepatic and gastro-splenic ligaments, omentum and mesocolon [1, 4, 5]. Surgical treatment is in most cases curative but some authors recommended also medical therapy with antiestrogens, nonsteroidal antiinflammatory drugs or even cytotoxic chemotherapy [1, 2, 6–8].

Case report

The patient, a well-nourished 36-year-old man, was admitted to our clinic due to intermittent mid-abdominal pain of one day's duration. Pain was accompanied by nausea, vomiting and stoppage of bowel movements. The physical examination revealed severe flatulence coexisting with marked peritoneal signs. The important physical finding was a firm mass palpable in the periumbilical region. All laboratory data were within normal limits. There was no history of previous operations or any abdominal trauma. A contrast-enhanced abdominal computerized tomography scan demonstrated the presence of a solid tumor measuring 10 × 9 × 8 cm lying medially to the descending colon in the peri-umbilical area. The tumor caused the ileus of the small intestine. Therefore, the patient was qualified for urgent laparotomy. On laparotomy we found a 10-cm round tumor in the mesentery of the ileum. There were no firm adhesions or shared blood supply and the mass did not invade the serosal layer of the bowel so enucleation was performed. The mesentery of the small intestine was intact (Fig. 1, 2). On section the tumor was firm and fibrous. It was composed of stellate fibroblastic cells embedded in a collagenous stroma without evidence of muscular or neural differentiation. Immunohistochemical analysis showed that the tumor cells expressed vimentin and actin. Cell markers CD 34, CD 117 and also desmin were negative.

The patient was discharged on the 7th postoperative day. Twelve-month follow-up revealed no recurrence of tumor.

Discussion

Mesenteric fibromatosis, also referred to as desmoid tumor of the mesentery, is a locally aggressive, benign proliferative process that may occur spo-

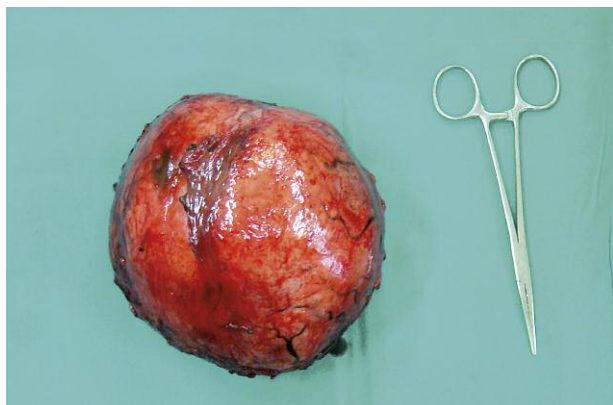


Fig. 1. Tumor after resection

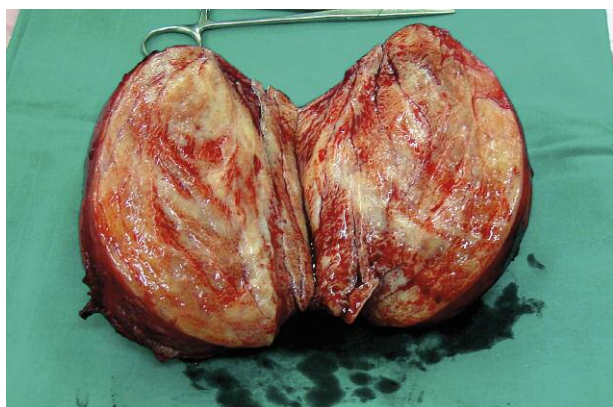

Fig. 2. Dissection of the tumor

radically or in association with familial adenomatous polyposis (FAP) (e.g. Gardner's syndrome variant of FAP). The other predisposing factors are pregnancy, previous abdominal surgery or trauma, and estrogen therapy [1, 2, 5, 7, 8]. It is a rare clinical entity; the estimated incidence is 3.7 new cases per million people per year [1, 2]. The incidence of abdominal wall and mesenteric desmoids in patients with Gardner's syndrome ranges from 4 to 29% [2].

Mesentery fibromatosis is more common in women of child-bearing age, as hormonal influence is implicated [5, 8], but some sources say that there is no gender or race predilection [1]. The deep fibromatoses are classified by anatomic location, the first group usually originating intraabdominally (mesenteric, pelvic, retroperitoneal fibromatosis), the second arising from the deep soft tissues of the abdominal wall (abdominal fibromatosis), and the third originating within extraabdominal soft tissues (extraabdominal fibromatosis) [1–4, 8].

Most intraabdominal desmoids arise in the mesentery of the small bowel; they are the most common primary tumor of the mesentery. We should differentiate them from other solid tumors which may be present in this location: lipomas, fibromyomas, leiomyomas, xanthogranulomas, neurofibromas and their malignant derivatives [1, 3, 4, 6, 7]. They may also simulate lymphoma, lymphangioma, metastatic disease, or soft-tissue sarcoma [9].

Most patients with mesenteric fibromatosis are clinically asymptomatic. The patient may present to a physician because of a palpable mass or abdominal pain, or come to

clinical attention due to complications such as gastrointestinal bleeding, small bowel obstruction, bowel perforation or fistula formation [1, 2]. At diagnosis desmoids are usually larger than 5 cm, and they may be larger than 15 cm. In 10–15% of cases they may be multiple [1–3].

The treatment of mesenteric fibromatosis is usually surgical. The type of surgical procedure depends on the tumor location. Extended bowel resection is necessary if the mass is closely attached to the abdominal organs (usually small and large bowel or enteric vessels).

Complete excision of the tumor is usually curative but incomplete resection may lead to recurrence and reoperation, which may be associated with significant morbidity, especially in patients with mesenteric fibromatosis coexisting with FAP, where the rate of recurrence is higher (25–50%). In these particular situations some authors recommend medical therapy with antiestrogens, cytotoxic chemotherapy or radiation therapy [1, 4, 5, 8].

The authors declare no conflict of interests.

References

1. Levy AD, Rimola J, Mehrotra AK, Sobin LH. Benign fibrous tumors and tumorlike lesions of the mesentery: radiologic-pathologic correlation. *RadioGraphics* 2006; 26: 245-64.
2. Faria CS, Iyer RB, Rashid A, Ellis L, Whitman GJ. Desmoid tumor of the small bowel and the mesentery. *AJR* 2004; 183: 118.
3. Brown JD, Day GM. Neurofibromatosis of the mesentery. *Proc R Soc Med* 1971; 64: 1218-9.
4. Smith EB. Giant fibroma of the mesentery. *J Natl Med Assoc* 1969; 61: 319-20.
5. Guatam A, Khatri AK, Pandey M, Arya NC, Shukla VK. Mesenteric mass in a 28-year-old woman. *Postgrad Med J* 1997; 73: 121-2.
6. Wiancko KB, MacKenzie WC. Primary tumours of the small bowel and its mesentery. *Can Med Assoc J* 1963; 88: 1225-30.
7. Vaswani BA, Shah M, Shah PM, Parikh BJ, Anand AS, Sharma GL. Giant mesenteric fibromatosis in Gardner's syndrome. *Indian J Cancer* 2011; 48: 140-2.
8. Polat C, Aktepe F, Turel S, Yazicioglu B, Ozkececi T, Arıkan Y. A giant mesenteric fibromatosis case presenting with mechanical intestinal obstruction and successfully resected with partial duodeno-jejunojejunectomy and right hemicolectomy. *Clinics (Sao Paulo)* 2010; 65: 110-3.
9. Herman J, Jurczyszyn D, Majewski P, Szmęja J, Drews M. Mesenteric cystic lymphangioma presenting as acute peritonitis. *Przegl Gastroenterol* 2011; 6: 51-4.

Address for correspondence

Piotr Misiak, MD, PhD
ul. Długa 35, Chechło I,
95-082 Dobroń
tel. +48 510 115 108
e-mail: pitmis@interia.pl

Submitted: 4.01.2012
Accepted: 18.10.2012