

## Tactical aspects of bullet wounds of the chest in peace time – own experience

Pakhomov G. Lvovic<sup>1</sup>, Djumabaev E. Satkułowic<sup>2</sup>, Karimov S. Niemadovic<sup>2</sup>

<sup>1</sup>Republican Specialized Centre of Surgery named after academician V. Vahidov, Uzbekistan

<sup>2</sup>Andijan branch of Republican Specialized Centre of Urgent Medical Help, Uzbekistan



Kardiochirurgia i Torakochirurgia Polska 2009; 6 (2): 187–190

### Abstract

**Introduce:** Damage to the chest is one of the most critical problems in urgent surgery. Chest traumas occupy the third place in requiring urgent surgical intervention, and have many purulent-septic complications and high mortality.

**Aim:** Here we present our own experience with patients suffering from chest trauma due to gunshot wounds.

**Material and Methods:** Three patients with gunshot wounds underwent emergency video-assisted thoracic surgery (VATS). In one patient the wounds of the lung and diaphragm were stitched. Two resections of damaged lung tissue were performed. One patient with extensive damage of the chest and abdomen also underwent upper-middle laparotomy.

**Results:** All patients survived and were discharged home.

**Conclusions:** The operation of choice in patients with chest trauma is VATS, which usually saves the life of the patients, reduces the operation time period, and leads to fast recovery of patients in the postoperative period. Nowadays there is applied the damage control (DC) concept, representing a fundamental and vitally necessary strategy for patients with a complex trauma.

**Key words:** chest trauma, bullet wound, damage control concept.

### Introduction

Diagnostics and treatment of damage to the chest continues to remain one of the most critical problems in modern urgent surgery. The data of many authors [1-3] show that traumas of the chest occupy the third place after traumas of the extremities and craniocerebral traumas, making up 10-20% in the structure of hospitalization. Up to 25% of chest traumas have complex damage, requiring urgent surgical intervention, described as significant duration of treatment and rehabilitation, many purulent-septic complications (up to 20%) and high mortality (from 17 to 30%) [4].

According to the statistical data, among patients deceased from chest traumas 15% of them have no absolutely fatal damage and the outcome of treatment of these injuries in many cases is determined not by the severity of the wound, but with the inability of the surgeon to diagnose its character and complications and to choose the optimal tactics of treatment in a short interval of time. Diagnostic mistakes make up 16-56% when only clinical, laboratory and X-ray examinations are used [4]. The difficulties of diagnostics of chest wounds lead to unreasonably long supervision, using

conservative treatment, whereas there is required active surgical intervention. At the same time the frequency of unreasonable thoracotomies in traumas of the chest varies from 10 to 56% [2, 5].

Against this background the application of VATS is a perspective which allows one to reveal attributes of a lung bruise, to make careful sanitation of the pleural cavity with evacuation of blood clots and necrotic tissue, to achieve proof of aerohaemostasis and restraining of lung by adequate assessment of drainage under visual control and to avoid unnecessary thoracotomies.

The performance of thoracoscopic operations in patients with a chest trauma in a severe condition is considered as the operation of choice, which allows one not only to make operative intervention in complete volume, but also frequently saves the life of the patient, since it is considered as less traumatic, reduces the time of operative intervention, and promotes fast activation of patients in the postoperative period [6, 7].

Here we would like to present our own experience with patients suffering from bullet wounds obtained during peace time.

**Adres do korespondencji:** Karimov Sheroz Niemadovic, MD, Uzbekistan, Andijan, Babur-shoch St. 55/23, tel.: +99 87 423 52 090, Email: sheroz-s\_mx@mail.ru

### Patient no. 1

A 20-year old male with a bullet wound sustained 14 hours earlier was admitted to the hospital. After draining the pleural cavity there was still bleeding at a volume of 100 ml/hour. It was decided to perform diagnostic thoracoscopy and to determine further surgical tactics.

The patient was positioned on the right side. The procedure was performed under local anaesthesia and the thoracoport was entered into the 5<sup>th</sup> intercostal space on the midaxillary line. Revision: left lung collapsed on 2/3 volumes, light pink colour, lung tissue in area C-9 of the low lobe of crimson colour with presence of a wound and bleeding, and in diaphragmatic dome the linear bleeding defect was revealed. Under general endotracheal anaesthesia, mini-thoracotomy was made up to 5 cm in the 6th intercostal space and 300 ml of fluid blood and clots were removed from the pleural cavity. In the low lobe (C 8-9) bleeding lesions of the lung of the sizes 3 × 2 and 2 × 1 cm were found.

There was bleeding injury of the diaphragmatic dome up to 4 cm in length, terminating in the diaphragm muscle (Fig. 1) and not penetrating the abdominal cavity. There was revealed and removed a foreign body from this area – a splinter (metal object 2 × 0.5 cm with a pointed edge). The defect of the lung and diaphragmatic wounds were sewn and drainage of the pleural cavity was performed. The patient was discharged from hospital after 7 days in a satisfactory condition.

### Patient no. 2

A 40-year old female, with a bullet wound of the left side of the chest, presenting with marked paleness of skin and cyanosis of lips, was admitted to the unit. The onset time of damage was no more than 1.5 hours earlier. The condition of the patient was unstable with arterial blood pressure 60/40 mm Hg, weak filling pulse and heart rate 120-130 per minute but consciousness was kept. The air entry at the left side was reduced. The blood was free aspirated by thoracocentesis on the left midaxillary line in the 4<sup>th</sup> intercostal

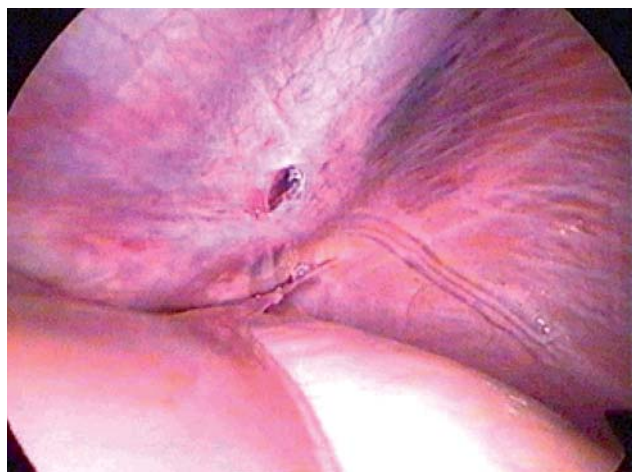

Fig. 1. Injury of the diaphragmatic dome presented through the thoracoscope

space but aspiration of air was not present. An entrance aperture of a bullet wound in a projection of the 6<sup>th</sup> intercostal space on the anterior axillary line, and target aperture of injury canal of large size (4 × 3 cm) in the 7<sup>th</sup>-8<sup>th</sup> intercostal space on the left paravertebral line were found.

Because the condition of the patient was worsening, the decision was made to perform left side thoracotomy. In the pleural cavity 700-1000 ml of blood with clots and inferior lobe connected tightly with the thoracic wall were found. The wound of the left lung had through passage character with extensive damage of 8 and 9 segments with intensive bleeding. The bleeding was temporarily stopped by pressing the wound channel. Pneumolysis and lung ligament destroying were performed. Further, a source of profuse bleeding was found – extensive defect of 6-9 ribs in the costovertebral joint. Haemostasis was performed by tamponading with sponges moistened with a hot saline solution; the tampon was left inside and the end of it was deduced through a target aperture for further removal. The destroyed segments were resected by applying staples “Ta-premium-90”, careful haemostasis and aerostasis. After 36 hours after the first operation rethoracotomy was required. The tampon was removed; the bleeding from defect of crises of ribs was stopped by coagulation, and additional sutures on a line of the seams for final aerostasis were added. The patient was discharged home after 14 days in a satisfactory condition.

### Patient no. 3

A 34-year old male was delivered to the operation room with multiple bullet wounds of the right side of the chest and right buttock. The time from receiving the wounds was about 2 hours before. The patient was unconscious, in a critical general condition, with arterial blood pressure 60/00 mm Hg, the pulse on peripheral arteries not present, the weakened pulse hardly defined on the carotid artery, respiratory rate up to 36 per minute, superficial breathing and no breath sounds at the right side of the chest present.

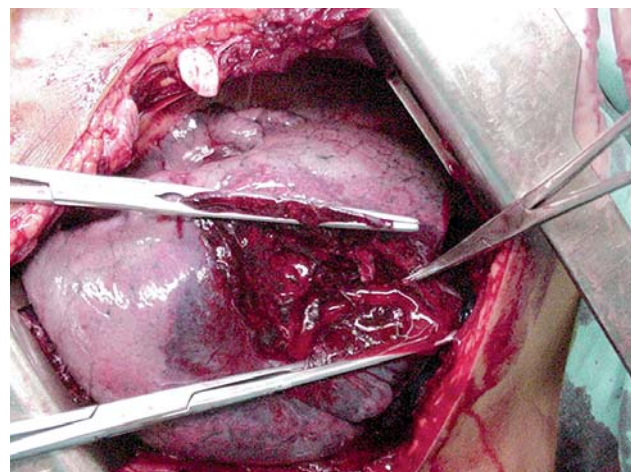


Fig. 2. Extensive damage of the right lower lobe

There was intensive bleeding from a set of bullet wounds in the area of the right shoulder and chest.

We could not perform X-ray examination due to the critical, severe condition of the patient. There was received blood during control thoracocentesis in the right pleural cavity in the 4<sup>th</sup> intercostal space on the anterior axillary line. During the operation the extensive damage of the lower and middle lobe of the right lung (Fig. 2), right diaphragmatic dome, liver, gunshot fracture of 6 ribs, and continuing intrapleural bleeding were revealed. It was decided to perform marginal resection of the low lobe of the right lung, suture of a wound of the middle lobe and diaphragmatic dome, and suture of the diaphragmatic surface of the right side of the liver. The bleeding from the bone defect of fractures of 3-8 ribs of diffuse character was tightly tamponaded. Next, we performed an upper middle laparotomy, in addition to suture of the gunshot damage of the right side of the liver. Final haemostasis did not reveal other damage in the abdominal cavity.

Rethoracotomy on the right side was performed 24 hours after the first operation. Tampon from defect of ribs was removed and the renewed bleeding was stopped by coagulation. A line of seams of resection was in addition tightened by central sutures, final aerostasis. In the pleural cavity approximately 300 ml curtailed haemothorax and 200 ml of liquid clotted blood. The right lung is well ventilated, completely occupies the volume of the hemithorax. The pleural cavity was repeatedly sanitized by solutions of furacillin and dioxidin. Recovery took 21 days.

## Discussion

Today one of the most discussed concepts in the world medical literature is that of damage control (DC), which is used in surgery of injury associated with severe marked paleness of skin and cyanosis of lips, and not only within the framework of urgent abdominal surgery, but also in other cases of urgent traumatological care. The DC concept corresponds to earlier existing representations about the necessity of minimally invasive operative intervention in severe, menacing life traumas and the differential stage-by-stage principle in treatment of these patients.

The first description of DC was by Rotondo and Schwab [8]. In 1993 they presented a principle of 3-stage treatment of patients with severe damage of abdominal cavity organs.

According to the DC concept, the first stage rendering the emergency operative intervention was directed at stopping bleeding. The second stage is the intensive therapy against traumatic shock in the intensive care unit with the purpose of restoration of physiological processes of the organism. It consists of a complex of measures on correction of water-electrolytic disturbances, hypoxia, body temperature, condition of the blood clotting system, etc. The third stage, which corresponds to the period 24-36 hours after trauma, involves performing the further "final" operative intervention, which consists of removal of haemostatic bandages, and carrying out reconstructive operations where necessary.

The further development of the DC concept has derived from the works of Johnson, who added a fourth stage, and which appearing as the initial phase was named as a point of readout ("ground zero") [9]. By this means Johnson has accented the potential necessity for complex medical measures of DC in the pre-hospitalization period. The "ground zero" period includes the fast transportation of the injured person to the medical unit, performance of complex measures on preparation of massive transfusion therapy, prevention of hypothermia and simple measures of temporary bleeding control.

The performance of medical measures should begin at once after a trauma has happened to a patient, before development of life-threatening physiological processes of the organism. The performance of principles of the given concept is most justified in patients with severe traumatic damage, hypothermia, acidosis, and if it is necessary to perform massive transfusion therapy. The emergency surgical intervention in patients of this group should be as short as possible (duration no more than 1 hour).

The preliminary decision on the necessity of application of DC principles can be accepted in situations of massive injuries by fire damaging agents having high velocity and energy, and explosive damage, in the presence of limited resources of rendering qualified medical aid.

The experience of these days shows that extensive damage of the chest is accompanied by expressed haemodynamic disturbances, particularly for bullet wounds by modern automatic weapons, which requires the performance of urgent thoracotomy. In the data submitted in the monograph of E. A. Vagner [2] 60.3% of the injured died from severe traumas of the chest directly at the place of the incident and 22.4% during transportation [1]. In most cases penetrating bullet wound of the chest is a lacerated-contused wound of the lung with massive pneumohaemothorax, when there is one correct decision – wide thoracotomy and resection of the lung. Therefore, in suturing of the lung, particularly in extensive breaks and bullet wounds, it is recommended to use mechanical sewing devices. Their application will allow in the shortest time to impose a linear two-lower chess seam by tantal brackets. It is expedient to perform immediate and complete haemostasis in case of massive bleeding from a wound of an arterial or venous vessel. The loss of time on surgical haemostasis in insignificant superficial bleeding in the given situation is inadmissible; in such cases there must be performed firm tamponading of the source of bleeding. Due to this procedure it is possible to considerably reduce the duration of intervention.

A necessary task is restoration of the level of haemostatic factors; this is achieved by transfusion of thrombocyte components, preparations of plasma, cryoprecipitate and VIIa factor preparations of the plasma.

## Conclusions

Diagnostic thoracoscopy allows one to perform high-grade revision of organs of the chest, to adequately

estimate the character and volume of intrathoracic damage, excluding doubts in the diagnosis and “the period of waiting” up to the establishment of the final diagnosis, and to define the indications for VATS or thoracotomy.

The DC concept represents a fundamental and vitally necessary strategy of treating patients with a severe trauma. The performance of medical measures should begin at once after receipt of a severe trauma by the patient, before development of life-threatening disturbances of physiological processes of the organism. The performance of principles of the given concept with reference to the injured persons with severe traumatic damage of the chest, in particular in cases of bullet wounds by modern automatic weapons, will allow the results of emergency thoracotomies to be significantly improved. However, surgical intervention in the patients of this group should be as short in duration as is reasonable under the circumstances. The operation should be performed quickly, not restricting time in order to restore all damaged structures, being limited by restoration of haemostasis and treatment of severe shock.

## References

1. Brusov PG, Urazkovsky NY. Rendering of the urgent surgical help at fire penetrating wounds of a chest. *Milit Med J* 2001; 2: 29-39.
2. Vagner EA. Surgery of damages of a chest. *Medicine*. Moscow, 1981.
3. Oransky IF, Halafian IA. Videothoracoscopy at damages of a chest. *J Endoscop Surg* 1999; 3: 56-57.
4. Jestkov KG, Shapovalianc SG, Arhipov DM. Emergency endosurgery of traumas of a chest: Surgical tactics and techniques. *J Endoscop Surg* 1999; 2: 21-25.
5. Porhanov VA, Polyakov IS, Kononenko VB, Bodnya VN, Mezerya AL, Krasnoslobodceva GL. Videothoracoscopy in treatment of the patients with traumatic damages of chest. *Ann J Surg* 2001; 2: 44-50.
6. Forster R, Storck M, Schafer R, Lang G, Liewald F. Thoracoscopy versus thoracotomy: a prospective comparison of trauma and quality of life. *Langenbecks Arch Surg* 2002; 387: 32-36.
7. Mineo TC, Ambrogi V, Cristino B, Pompeo E, Pistolese C. Changing indications for thoracotomy in blunt chest trauma after the advent of videothoracoscopy. *J Trauma* 1999; 47: 1088-1091.
8. Rotondo MF, Schwab CW, McGonigal MD, Phillips GR 3<sup>rd</sup>, Fruchterman TM, Kauder DR, Latenser BA, Angood PA. 'Damage control': an approach for improved survival in exsanguinating penetrating abdominal injury. *J Trauma* 1993; 35: 375-382.
9. Johnson JW, Gracias VH, Gupta R, Guillaumondegui O, Reilly PM, Shapiro MB, Kauder DR, Schwab CW. Hepatic angiography in patients undergoing damage control laparotomy. *J Trauma* 2002; 52: 1102-1106.