

## Intraoperative conversion of coronary bypass grafting from cardio-pulmonary bypass to off-pump procedure forced by antithrombin III deficiency – a case report

Śródoperacyjna wymuszona zmiana sposobu operacji rewaskularyzacji mięśnia sercowego z udziałem techniki krążenia pozaustrojowego na zabieg na bijącym sercu spowodowana niedoborem antytrombiny III – opis przypadku

Andrzej Banyś<sup>1</sup>, Sławomir Jander<sup>2</sup>, Justyna Grychowska<sup>1</sup>, Ryszard Jaszewski<sup>2</sup>

<sup>1</sup>Department of Anaesthesiology and Cardiac Intensive Care, 1<sup>st</sup> Chair of Cardiology and Cardiac Surgery, Medical University of Lodz

<sup>2</sup>Department of Cardiac Surgery, 1<sup>st</sup> Chair of Cardiology and Cardiac Surgery, Medical University of Lodz

Kardiochirurgia i Torakochirurgia Polska 2010; 7 (4): 427–430

### Abstract

The essential condition of safe application of cardio-pulmonary bypass (CPB) is to obtain a proper level of heparinization in the operated patient, measured by activated clotting time (ACT). The present paper is a case report of forced intraoperative change of technique of surgical myocardial revascularization in a 78-year-old woman caused by antithrombin III deficiency. **Key words:** myocardial revascularization, heparinization, antithrombin III.

### Introduction

The essential condition of safe application of cardio-pulmonary bypass (CPB) during coronary artery bypass grafting (CABG) is to obtain a proper level of heparinization in the operated patient. In clinical practice the level of heparinization is measured by activated clotting time (ACT) and its value that allows one to safely start CPB is over 450–470 seconds [1]. In most cases this reference level can be easily reached by the administration of 3 mg/kg of heparin intravenously directly before cannulation. In the present case, however, in spite of giving a double dose of heparin (360 mg vs 180 mg), the highest level of ACT hardly reached 300 seconds. Urgent measurement of plasma antithrombin III (AT III) revealed a level of 36.4%, while the normal range is between 75 and 125%.

### Streszczenie

Podstawowym warunkiem bezpiecznego zastosowania techniki krążenia pozaustrojowego podczas zabiegu rewaskularyzacji mięśnia sercowego jest uzyskanie referencyjnego, bezpiecznego poziomu heparynizacji krwi operowanego pacjenta, mierzonego jako aktywowany czas krzepnięcia (ang. *activated clotting time* – ACT). W pracy przedstawiono przypadek wymuszonej śródoperacyjnej zmiany sposobu operacji rewaskularyzacji serca u 78-letniej chorej, spowodowany niedoborem antytrombiny III.

**Słowa kluczowe:** rewaskularyzacja mięśnia sercowego, heparynizacja krwi, antytrombina III.

The described situation forced the team to change the planned strategy of revascularization from CABG on CPB to off-pump coronary artery bypass (OPCAB) although the purse-string sutures had already been applied and the lines had been taken from the perfusionist.

### Case report

A 78-year-old woman was admitted to the department of cardiology of a regional hospital on 16 Apr 2010 due to acute coronary syndrome, with transient ST segment elevation over the anterior wall. Troponin levels rose during 3 days from 0.29 ng/ml to 26.94 ng/ml. It was her first episode of angina and the pain persisted throughout 3 hours in spite of administration of intravenous nitroglycerine and morphine. The patient had a 10-year history of controlled

**Adres do korespondencji:** Andrzej Banyś, Department of Anaesthesiology and Intensive Cardiological Care, 1<sup>st</sup> Chair of Cardiology and Cardiac Surgery, Medical University of Lodz, Sterlinga St 1/3; 91-425 Lodz, Poland, Email: andrzej.banys@umed.lodz.pl

arterial hypertension. Resting ECG from 16 Apr showed levogram, regular sinus rhythm of 60 beats per minute, elevation of ST segments in leads V1-V3, and lowering of ST segments of 2 mm in leads II, III, aVF and V4-V6. On coronary angiography taken on 16 Apr a significant stenosis of the distal left main stem of 80-90% spreading into proximal portions of the left anterior descending (LAD) branch and circumflex (Cx) branch was found. The dominant right coronary artery (RCA) had some non-significant lesions in its proximal and middle portion and it gave a trace of retrograde collateral inflow into the distal LAD. Echocardiography showed akinesis of the distal and middle segment of the anterior heart wall with hypokinesis of the apex and antero-septal portion of the myocardium. However, global systolic function of the left ventricle was good with ejection fraction of 50%. The echocardiography also revealed trivial to moderate mitral insufficiency. During hospitalization, the patient was given clopidogrel orally on 16 Apr, and Integrilin intravenously in infusion until 19 Apr. The patient was presented to a cardiac surgeon and was qualified for surgical revascularization of the myocardium with calculated operative risk of 7.18 according to the EUROSCORE. On 26 Apr, the patient was admitted to the Department of Cardiac Surgery, Medical University of Lodz, and she was scheduled for a CABG procedure on CPB for 28 Apr, with the following target vessels: LAD and one of the circumflex artery branches.

### **The operation**

The preoperative routine coagulometry did not show any abnormalities, with APTT of 39 s, TT of 18 s, fibrinogen of 4.4 g/L and INR of 0.86. The baseline basic life parameters were as follows: arterial pressure – 125/85 mm of mercury, regular sinus rhythm of 75 beats per minute and saturation of 98%. On induction of general anaesthesia the patient was given intravenously 3.15 µg/kg of fentanyl, 0.21 mg/kg of Hypnomidate and 0.06 mg/kg of pancuronium. After endotracheal intubation the arterial pressure was 130/80 mm of mercury and heart rate 80 per minute. Medication during the maintenance of anaesthesia was as follows: fentanyl in continuous intravenous infusion in a dose of 0.087 µg/kg/min, midazolam 1.75 µg/kg/min, interrupted doses of pancuronium, ventilation with 45% oxygen with 2%vol sevoflurane after the skin incision. After prep and drape the chest was opened through median sternotomy and the anaesthesiologist was asked to administer heparin. Then, after opening of the pericardial sac, the preparation for standard CPB connection was made and the lines were taken from the perfusionist. Simultaneously, a portion of the saphenous vein was harvested. Deliberately, the decision was made not to harvest the left intrathoracic artery (LITA) because of the advanced age of the patient and in order to avoid some potentially dangerous complications of the pleural cavity opening. After the administration of an initial dose of heparin (3 mg/kg = 180 mg) ACT achieved 300 seconds and stopped, so an additional dose of heparin (90 mg) was injected, but it did not make ACT rise over

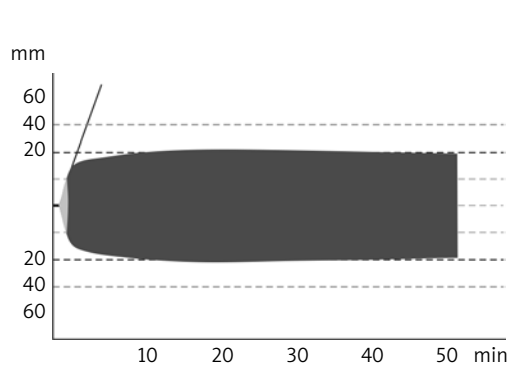
295 seconds. Another dose of heparin (90 mg) which doubled the calculated starting dose was also ineffective in elongation of ACT over 450 seconds, which is considered to be a safe level before connecting the CPB. Urgent measurement of AT III showed its level at 36.4% (normal range: 75-125%). In such circumstances the decision was made to operate without connecting the CPB, on the beating heart. The LAD was exposed using pericardial stitches and stabilized with a MEDTRONIC OCTOPUS device without causing any adverse haemodynamic consequences. Arteriectomy of the LAD was performed in its middle portion and a shunt of 2.5 mm diameter was inserted. The distal anastomosis was accomplished using monofilament non-absorbable PROLENE 7,0 suture. The idea of grafting the marginal branch was given up mainly because it was a small recessive vessel of diameter less than 1.5 mm. Besides, there was a poor haemodynamic reaction to attempts to expose the lateral heart wall. The ascending aorta was side clamped and the proximal anastomosis was made with PROLENE 6,0 and the graft was de-aired. Since ACT at the end of the procedure was shorter than baseline (180 vs. 190 seconds) protamine was not administered. After having checked haemostasis carefully, two chest tubes were inserted and the chest was closed with steel wires. Then the skin was sutured, a sterile dressing was applied to the wound and the patient was uneventfully transferred to the ICU. The early postoperative course at the ICU was uncomplicated with minimal drain production. Thrombelastography performed within the first postoperative hour confirmed a state of hypercoagulability (Fig. 1) and the patient was given 7600 IU of nadroparin subcutaneously. The patient was circulatory and respiratory sufficient, with no arrhythmia and no fever. She was extubated 6 hours after the operation. Then she was administered orally 75 mg of ASA and 75 mg of clopidogrel. The patient was discharged from the ICU on the second postoperative day.

### **Discussion**

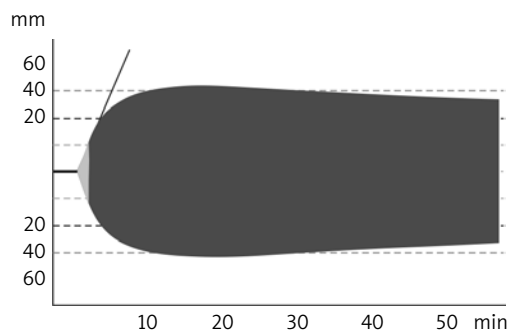
Thrombin is the key enzyme of the coagulation cascade, having a great impact on intraoperative haemostasis [2]. The plasmatic activity of thrombin depends on the baseline concentration of prothrombin, the rate of conversion of prothrombin to thrombin, and the process of thrombin inactivation, which occurs due to reaction with its inhibitor – antithrombin (AT). Thrombin and AT form equimolar protein complexes – thrombin-antithrombin (TAT) [2, 3], which are markers of thrombin activation [4, 5]. While a proper balance between thrombin and antithrombin is preserved, there is little risk of thrombotic complications [2]. Antithrombin III (AT III) is a glycoprotein produced in the liver. It is a serine protease inhibitor and an active factor of coagulation. AT III plays a potent role in prevention of thrombogenesis through inhibition of thrombin activity (IIa), factor Xa [6] and IXa and XIIa. Heparin is a direct inhibitor of thrombin, decreasing its enzymatic activity 5-fold [6]. Additionally it increases the activity of AT III, inhibits the activity of factor Xa, reducing the transformation rate from prothrombin

Institute  
Location

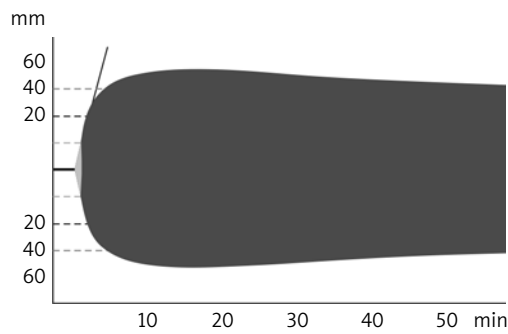
ROTEM Analyser, Pentapharm  
2226



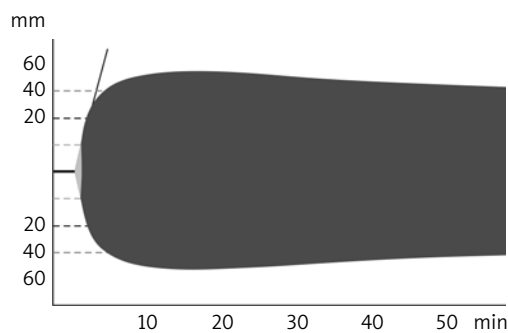
FIBTEM		2305		4	
RT:	00:52:24	ST:	2010-04-28 T 12:37:15		
CT	: 59 s	MAXV	: 26	G	: 3570
CFT	: 55 s	MAXV-t	: 91 s	AS	: 35 mm
$\alpha$	: 79 °	AUC	: 4131	A15	: 41 mm
A10	: 39 mm	MCE	: 71	A25	: 41 mm
A20	: 42 mm	MCF-t	: 1103 s	A30	: 41 mm
MCF	: 42 mm	CFR	: 81 °	ARS	: 273 mm <sup>2</sup>
ML	:* 8 %	LOT	: s	AR10	: 642 mm <sup>2</sup>
LI30	: 98 %	CLR	: °	AR15	: 1041 mm <sup>2</sup>
LI45	: 94 %	LT	: s	AR20	: 1455 mm <sup>2</sup>
LI60	: %	ACF	:* 38 mm	AR25	: 1872 mm <sup>2</sup>



HEPTEM		2305		3	
RT:	00:57:47	ST:	2010-04-28 T 12:31:37		
CT	: 204 s	MAXV	: 18	G	: 8442
CFT	: 70 s	MAXV-t	: 223 s	AS	: 50 mm
$\alpha$	: 76 °	AUC	: 6229	A15	: 63 mm
A10	: 60 mm	MCE	: 169	A25	: 61 mm
A20	: 63 mm	MCF-t	: 922 s	A30	: 59 mm
MCF	: 63 mm	CFR	: 77 °	ARS	: 322 mm <sup>2</sup>
ML	:* 16 %	LOT	: 3136 s	AR10	: 880 mm <sup>2</sup>
LI30	: 95 %	CLR	: °	AR15	: 1497 mm <sup>2</sup>
LI45	: 87 %	LT	: s	AR20	: 2125 mm <sup>2</sup>
LI60	: %	ACF	:* 53 mm	AR25	: 2744 mm <sup>2</sup>



INTEM		2305		2	
RT:	01:00:44	ST:	2010-04-28 T 12:27:58		
CT	: 188 s	MAXV	: 32	G	: 13 700
CFT	: 38 s	MAXV-t	: 209 s	AS	: 64 mm
$\alpha$	: 82 °	AUC	: 7167	A15	: 73 mm
A10	: 71 mm	MCE	: 274	A25	: 71 mm
A20	: 73 mm	MCF-t	: 855 s	A30	: 69 mm
MCF	: 73 mm	CFR	: 83 °	ARS	: 455 mm <sup>2</sup>
ML	:* 15 %	LOT	:* 3346 s	AR10	: 1138 mm <sup>2</sup>
LI30	: 94 %	CLR	: °	AR15	: 1864 mm <sup>2</sup>
LI45	: 88 %	LT	: s	AR20	: 2595 mm <sup>2</sup>
LI60	: %	ACF	:* 62 mm	AR25	: 3313 mm <sup>2</sup>



EXTEM		2305		1	
RT:	01:02:46	ST:	2010-04-28 T 12:25:06		
CT	: 66 s	MAXV	: 28	G	: 13 121
CFT	: 46 s	MAXV-t	: 101 s	AS	: 66 mm
$\alpha$	: 81 °	AUC	: 7153	A15	: 72 mm
A10	: 72 mm	MCE	: 262	A25	: 71 mm
A20	: 72 mm	MCF-t	: 918 s	A30	: 69 mm
MCF	: 72 mm	CFR	: 82 °	ARS	: 460 mm <sup>2</sup>
ML	:* 17 %	LOT	:* 3239 s	AR10	: 1158 mm <sup>2</sup>
LI30	: 95 %	CLR	: 9 °	AR15	: 1879 mm <sup>2</sup>
LI45	: 88 %	LT	: s	AR20	: 2602 mm <sup>2</sup>
LI60	: 83 %	ACF	:* 60 mm	AR25	: 3318 mm <sup>2</sup>

Fig. 1. Thrombelastography performed within the first postoperative hour confirmed a state of hypercoagulability

to thrombin, inhibits the aggregation of platelets, and is also an inhibitor of factors VIIa, IXa, Xa and XIIIa. Patients with AT III deficiency have resistance to heparin [7]. Together with decreasing inhibitory activity of antithrombin and increasing thrombinogenesis, the risk of thrombosis significantly rises [2]. In the case of large AT III deficiency the use of heparin is ineffective [7-9]. The present paper is a case report of a forced intraoperative change of technique of surgical myocardial revascularization in a 78-year-old woman caused by antithrombin III deficiency. In this patient a conversion from CABG on CPB to OPCAB was possible due to the type of lesions in coronary arteries (left main stem stenosis with recessive circumflex artery). What is more, it seems that this conversion had no alternative, because according to Slaughter et al. [9], the administration of AT III concentrate in patients during CABG does not affect the process of TAT complex formation. Some current studies confirm that AT III is important but not the only inhibitor of coagulation. Other significant factors playing a great role in the prevention of hypercoagulability are: protein C system, tissue plasminogen activator (t-PA), its inhibitor – plasminogen activator inhibitor (PAI-1), and thrombin activatable fibrinolysis inhibitor (TAFI) [10-12].

## References

1. Banyś A, Iwaszkiewicz A, Janowska E. Znieczulenie chorych do zabiegów rewaskularyzacji mięśnia sercowego. W: Zastónka J, Domański C, Iwaszkiewicz A, Jaszewski R, Okoński P (red.). Polska skala ryzyka operacyjnego leczenia choroby niedokrwiennej mięśnia sercowego. Medycyna Plus, Warszawa 2006; 27-46.
2. Stępień E, Plicner D, Branicka A, Stankiewicz E, Pazdan A, Śnieżek-Maciejewska M, Górkiewicz I, Kapelak B, Sadowski J. Factors influencing thrombin generation measured as thrombin-antithrombin complexes levels and using calibrated automated thrombogram in patients with advanced coronary artery disease. *Pol Arch Med Wewn* 2007; 117: 297-305.
3. Cugno M, Nussberger J, Biglioli P, Giovagnoni MG, Cardinali M, Agostini A. Cardiopulmonary bypass increases plasma bradykinin concentration. *Immunopharmacology* 1999; 43: 145-147.
4. Philippou H, Davidson SJ, Mole MT, Pepper JR, Burman JF, Lane DA. Two-chain factor VIIa generated in the pericardium during surgery with cardiopulmonary bypass: relationship to increase thrombin generation and heparin concentration. *Arterioscler Thromb Vasc Biol* 1999; 19: 248-254.
5. Walter T, Helber U, Bail D, Heller W, Hoffmeister HM. Influence of ACE inhibition on myocardial damage, the kallikrein-kinin system and hemostasis during cardiopulmonary bypass surgery. *Thorac Cardiovas Surg* 2002; 50: 150-154.
6. Wondman RC, Barker LA. Bleeding complications associated with cardiopulmonary bypass. *Blood* 1999; 76: 1680-1685.
7. Stoelting RK, Dierdorf SF (eds.). *Anesthesia and Co-Existing Disease*. 4<sup>th</sup> ed. Churchill Livingstone, New York 2002; 489-504.
8. Petrovitch CT, Drummond JC. Hemotherapy and hemostasis. In: Barash PG, Cullen BF, Stoelting RK (eds.). *Clinical Anesthesia*. 4<sup>th</sup> ed. Lippincott, Williams & Wilkins, Philadelphia 2001; 201-236.
9. Slaughter TF, Mark JB, El-Moalem H, Hayward KA, Hilton AK, Hodgins LP, Greenberg CS. Hemostatic effects of antithrombin III supplementation during cardiac surgery; results of a prospective randomized investigation. *Blood Coagul Fibrinolysis* 2001; 12: 25-31.
10. Undas A, Plicner D, Stępień E, Drwila R, Sadowski J. Altered fibrin clot structure in patients with advanced coronary artery disease; a role of C-reactive protein, lipoprotein (a) and homocysteine. *J Thromb Haemost* 2007; 5: 1988-1990.
11. Niccoli G, Basucci LM, Biscione C, Buffon A, Siviglia M, Conte M, Porto I, Graziani F, Liuzzo G, Crea F. Instability mechanisms in unstable angina according to baseline serum levels of C-reactive protein. The role of thrombosis, fibrinolysis and atherosclerotic burden. *Int J Cardiol* 2008; 131: 134-135.
12. Żekanowska E, Kotschy M, Rość D, Missima M, Ogorzeja W, Kotschy D. Thrombin-antithrombin III (TAT) complexes during coronary artery bypass grafting with and without extracorporeal circulation. *Folia Cardiol* 2004; 11: 839-845.