

Applying vertical rectus abdominis muscle (VRAM) flap in surgical treatment of extensive chest wall injury after deep infection of the sternotomy wound

Zastosowanie płata VTRAM (*vertical transverse rectus abdominis muscle flap*) w leczeniu operacyjnym rozległego uszkodzenia ściany klatki piersiowej w przebiegu głębokiego zakażenia rany po sternotomii

Magdalena Kołaczowska¹, Jerzy Jankau², Sebastian Batkiewicz¹, Maria Michałkiewicz³, Stanisław Rzymiski⁴, Piotr Siondalski¹

¹Cardiac Surgery Department, Medical University of Gdansk, Poland

²Plastic Surgery Department, Medical University of Gdansk, Poland

³The National Centre of Hyperbaric Medicine in Gdynia, Poland

⁴Cardiac Surgery Department Multidisciplinary City Hospital name Józefa Strusia, Poznan, Poland

Kardiochirurgia i Torakochirurgia Polska 2011; 8 (3): 387–390

Abstract

Sternotomy wound infection may be a very serious, potentially fatal complication of cardiac surgical procedures. Deep infection of the wound with mediastinitis requires intensive care which involves removing the cause of infection and often reconstructing largely injured chest wall.

This paper presents treatment of serious complications of sternotomy wound healing. The large chest wall defect which resulted from the multi-stage treatment caused severe respiratory failure in the patient, which required several months of mechanical ventilation. Intraoperatively, after the excision of the infected tissues and sternum bone material, the chest wall defect was filled with pedicled omentum majus flap and VRAM (vertical rectus abdominis muscle flap).

The initial result of the procedure was satisfactory with a few weeks of improved respiratory functions after the surgery, when the time of self-sustained, successful breathing without the respirator was gradually prolonged. However, a few months after the procedure, the patient expired due to systemic fungal infection.

Key words: infection, sternotomy, omentum majus, VRAM (vertical rectus abdominis muscle flap).

Streszczenie

Zakażenie rany po sternotomii może stać się bardzo ciężkim powikłaniem po operacji kardiochirurgicznej, a nawet doprowadzić do zgonu pacjenta. Głębokie zakażenie rany z zapaleniem śródpiersia wymaga intensywnej terapii polegającej na usunięciu źródła zakażenia i często naprawie ściany klatki piersiowej, która nierzadko podlega znacznej destrukcji. W pracy przedstawiono przebieg leczenia ciężkiego powikłania gojenia się rany po sternotomii. Powstały w przebiegu wieloetapowego leczenia rozległy ubytek ściany klatki piersiowej doprowadził do ciężkiej niewydolności oddechowej u chorej z koniecznością kilkumiesięcznej terapii respiratorem. Śródoperacyjnie po wycięciu zakażonych tkanek i kości mostka ubytek ściany klatki piersiowej ostatecznie zaopatrzone, używając uszypułowany płat sieci większej oraz VTRAM (ang. *vertical transverse rectus abdominis muscle flap*). Uzyskano zadowalający wstępny wynik operacji, wyrażający się trwającą przez kilka tygodni po operacji poprawą sprawności oddechowej pacjentki polegającą na stale wydłużającym się czasie samodzielnego i sprawnego oddychania, bez pomocy respiratora. Jednakże po kilku miesiącach po operacji doszło do zgonu chorej w przebiegu ogólnego zakażenia grzybiczego.

Słowa kluczowe: zakażenie, sternotomia, sieć większa, VRAM.

Introduction

Deep wound infection with mediastinitis is a rare, but extremely dangerous complication. Among patients predisposed to complications by various factors, the need

is emphasised to perform cardiac surgical procedures with utmost care. It is particularly important to avoid damage to the bones and vascularisation of the sternum, and to use secure suturing techniques. In the selected group of

Address for correspondence: Magdalena Kołaczowska, Cardiac Surgery Department, Medical University of Gdansk, Dębinki 7, 80-211 Gdansk, Tel. +48 58 349 24 75, E-mail: magdak@gumed.edu.pl

patients it is also possible to stabilise the sternal edges with the use of the technique described by Robicsek. Moreover, it is crucial to individualise the treatment of patients predisposed to wound healing complications and to apply sternum sewing bands, antibiotic sponges or bone cement at the sternum. If wound healing irregularities are suspected after a cardio-surgical procedure, the wound should be closely monitored and wise medical decisions are essential.

If wound infection is suspected, an appropriate, intensive and multidirectional treatment should be applied. Such a treatment consists of a surgical procedure called debridement, the scope of which depends on the area of healing complications and the antibiotics administered. Hyperbaric oxygen treatment is also an option. The surgical procedure includes opening the wound, applying dressing with antiseptics, applying vacuum dressing, as well as extensive removal of infected tissues from the mediastinum, applying high-volume flow drainage and renewed suturing of the sternal bones. In some cases, excessive sternal damage or chronic bone infection develop. In these patients, as a consequence of the necessary, excessive surgery, significant loss of tissue in the anterior chest wall and the related respiratory failure occur. This requires surgical reconstruction of the anterior chest wall. In such a procedure, pedicled, well supplied with blood omentum majus flap, thoracic or abdominal muscles are used [1, 2]. Additionally, healing is facilitated with the immunological and regenerative features of the omentum [3, 4].

Case description

The patient, female, aged 59, diagnosed with coronary vascular disease, COPD, obesity, type 2 diabetes, steroid induced adrenal insufficiency, thyroid insufficiency, underwent coronary artery bypass grafting with two venous grafts: to the anterior descending branch and obtuse marginal branch. Standard prophylactic antibiotic therapy was administered, namely second generation cephalosporin for three days after the procedure. No

complications were observed in the post-operative period until the seventh day after the procedure, when dehiscence was found of the sternotomy wound, and the culture of the effusion grew single colonies of methicillin-resistant skin *Staphylococcus MRCNS*. The patient had no fever. On the 8th day the patient was discharged to the rehabilitation hospital in a good general condition. The following day she returned with dehiscence and sternal instability. The day after, mediastinum was surgically opened, the effusion and necrotic tissues were removed, Braunovidol irrigation (10 ml in 500 ml saline) and renewed closure of the sternal edges were performed. Tissue and effusion cultures grew *Enterobacter cloacae* ESBL colonies. Targeted antibiotic therapy with ciprofloxacin was administered. Mechanical ventilation was performed. Regardless of the treatment, the wound reopened. Another surgery was suggested to the patient. In this reoperation, the mediastinum was lined with gauze strips with antiseptics and the wound was left unclosed. Additional antibiotic therapy with clindamycin was administered. Numerous cultures of wound smears, as well as bacteriological tests of blood, bronchial washing and vascular catheters were performed. Depending on the results of these tests, the antibiotic therapy was modified. After 2 weeks of mechanic ventilation, tracheotomy was performed. Vacuum assisted closure (VAC) was applied. The infection of mediastinum caused excessive tissue necrosis, which resulted in anterior chest wall instability and made it impossible for the patient to breathe sufficiently without support. The patient remained conscious and was mechanically ventilated.

Figure 1 shows the wound around three months after the first surgery. In the mid chest between the breasts, at the level of the body and xiphoid process of the sternum, round wound can be seen, approximately 20 cm in diameter, surrounded by a thick cicatricial band with traces of the removed sutures. The wound bed is covered with reddish-pink granulation tissue, yellowish-green fibrin and serous effusion. In the right part of the wound cicatrized pectoralis major muscle is visible. In the bottom and top areas of the wound, pouches with serous effusion are shown.

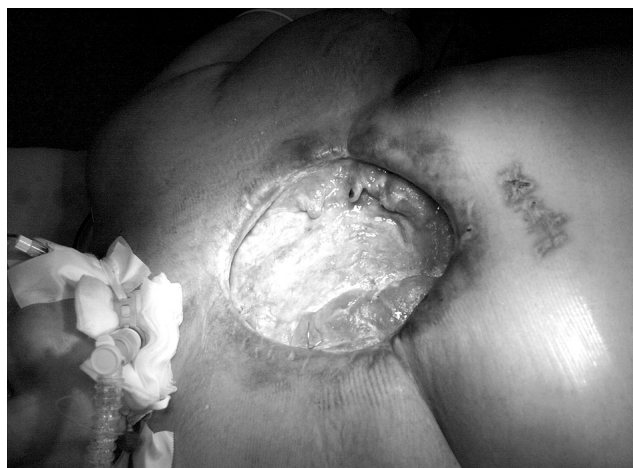

Fig. 1. The wound around three months after the first surgery

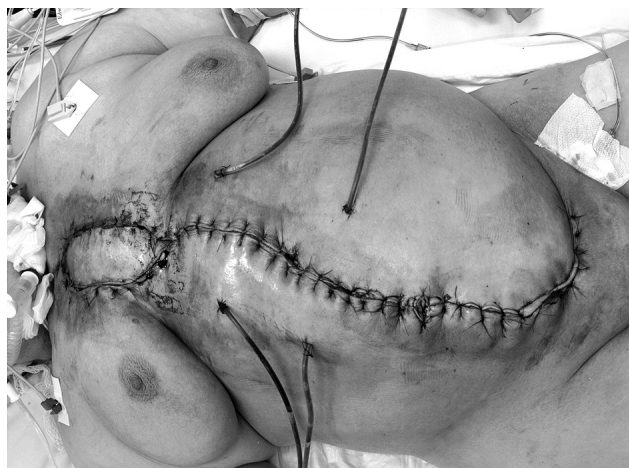


Fig. 2. The wound one day after the last surgery

In this situation, reoperation was suggested to the patient, after seven days of hyperbaric oxygen therapy. This improved the general condition of the patient and negative culture results were obtained.

The procedure consisted of removing necrotic tissues, stump ribs and sequesters within the remnants of the sternal bone. Then the wound was rinsed with 3 litres of warm saline solution of an iodine antiseptic. After extending the incision towards the upper abdominal midline, the omentum majus flap was accessed. During the omentum preparation numerous adhesions were found that resulted from previous abdominal surgeries. A rupture of the spleen capsule occurred, which necessitated spleen removal – due to haemorrhage. Prepared well supplied with blood omentum majus flap was transposed to mediastinum to fill the space where tissues were removed. There still remained a significant loss of skin, muscle and bone tissues of the chest wall. This space was filled with the pedicled, rotated by 180° myocutaneous flap of the right rectus abdominis muscle. The right and left pectoralis major muscles were mobilised to the depth of approximately 8 cm from the chest wall in order for these myocutaneous flaps to be sutured, with fascial suture, to the rotated flap of the rectus muscle (VRAM) that filled the defect (Fig. 2). Concluding the procedure, Redon drains were left in the abdominal cavity and under the muscle flaps. Skin sutures were tied without tension.

Four days post-operatively, the distal fragment of the VRAM became necrotic in the skin and subcutaneous tissue, and was therefore removed. On the 16th day post-operatively, hyperbaric oxygen treatment was applied again.

Post-operatively, gradual improvement of the patient's respiratory efficiency was observed. The patient underwent active respiratory rehabilitation. After three weeks the patient was able to breathe without support for 9 hours a day. On the 23rd day post-operatively the patient refused further treatment with hyperbaric oxygen. After further three weeks a skin transplant was performed around the distal segment of the VRAM.

In the following three months of hospitalisation the general condition of the patient gradually deteriorated due to the development of an infection of the lung tissue. As a consequence, respiratory insufficiency increased and permanent ventilation was necessary. Laboratory test results showed decreased antibody level. Around 4 months after the last surgery and 7 months after the primary surgery the patient died due to fungal sepsis.

Discussion

Applying the pedicled, myocutaneous flap of TRAM (transverse rectus abdominis muscle) was first described in the 1980s by C. Hartrampf *et al.* [5, 6]. Since then, it has become a golden standard in thoracic reconstruction procedures where patient's own tissues are used.

The advantage is the well provided with blood island of skin and adipose tissue, vascularised by perforators from superior and inferior epigastric vessels that anastomose at the level of the navel.

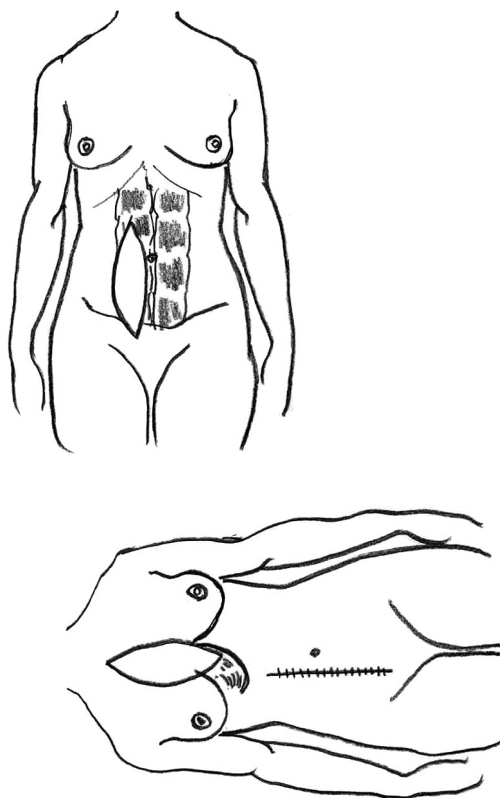


Fig. 3. Vertical rectus abdominis muscle (VRAM) flap

Due to the long pedicle that consists of the rectus abdominis muscle, the flap has a high potential for rotation and constitutes a perfect material not only to reconstruct the anterior chest wall structures but also a resistant material for significant wall defect closures. In a classical thoracic reconstruction, the pubic attachment of the rectus abdominis muscle is cut and the prepared island of skin and adipose tissue is supplied with blood by superior epigastric vessels that arise from internal thoracic vessels.

In this case, with internal thoracic vessels preserved, it was possible to transfer the island of skin and adipose tissue on one rectus abdominis muscle with the axis of the island of skin and adipose tissue parallel to the rectus abdominis muscle – the so called VRAM (vertical rectus abdominis muscle) flap [7-9]. The extensive tissue loss around sternum required the use of the largest possible surface area of the flap (Fig. 3). The defect of the mediastinum tissues below the layer of the muscle fascia was filled with the pedicled omentum majus flap, transposed from the abdominal cavity. The advantage of this type of flaps is that the omentum actively limits infections and wound effusion.

The advantage of using VRAM in surgical closure of extensive chest tissue injuries is the use of the rectus abdominis muscle as the layer that stabilises the edges of pectoral muscles. This allowed, in the described case, to improve significantly the anterior chest wall stability and, as a result, the patient's respiratory efficiency. Furthermore, the island of skin and adipose tissue may act as dressing,

well supplied with blood, which closes the surface of the wound [10].

Conclusions

1. Although the treatment of the patient after coronary revascularisation, which lasted more than 7 months, ended tragically, all stages of surgical treatment of patients with cardiac conditions are important.
2. Simultaneous use of both the VRAM and omental flaps is feasible and safe to stabilise the chest and fill extensive tissue loss.

References

1. Jones G, Jurkiewicz MJ, Bostwick J, Wood R, Bried JT, Culbertson J, Howell R, Eaves F, Carlson G, Nahai F. Management of the infected median sternotomy wound with muscle flaps. The Emory 20-year experience. *Ann Surg* 1997; 225: 766-776.
2. Schroeyers P, Wellens F, Degrieck I, De Geest R, Van Praet F, Vermeulen Y, Vanermen H. Aggressive primary treatment for poststernotomy acute mediastinitis: our experience with omental- and muscle flaps surgery. *Eur J Cardiothorac Surg* 2001; 20: 743-746.
3. Collins D, Hogan AM, O'Shea D, Winter DC. The omentum: anatomical, metabolic, and surgical aspects. *J Gastrointest Surg* 2009; 13: 1138-1146.
4. Kitano M. Omentoplasty in thoracic surgery. *Gen Thorac Cardiovasc Surg* 2008; 56: 483-489.
5. Schefflan M, Hartrampf CR, Black PW. Breast reconstruction with a transverse abdominal island flap. *Plast Reconstr Surg* 1982; 69: 908-909.
6. Hartrampf CR Jr. The transverse abdominal island flap for breast reconstruction. A 7-year experience. *Clin Plast Surg* 1988; 15: 703-716.
7. Baumann DP, Butler CE. Component separation improves outcomes in VRAM flap donor sites with excessive fascial tension. *Plast Reconstr Surg* 2010; 12: 1573-1580.
8. Nelson RA, Butler CE. Surgical outcomes of VRAM versus thigh flaps for immediate reconstruction of pelvic and perineal cancer resection defects. *Plast Reconstr Surg* 2009; 123: 175-183.
9. Erdmann D, Küntschner M, Petravic A, Sauerbier M, Menke H, Schirren J, Dienemann H, Germann G. Plastic surgery coverage of osteocutaneous defects of the sternum area with the vertical and transversal rectus abdominis muscle (VRAM/TRAM) flap. [Article in German]. *Chirurg* 2000; 71: 1156-1160.
10. Quiroga Martínez J, Gualis Cardona J, Gregorio Crespo B, Cabanyes Candela S, Cilleruelo Ramos A, Duque Medina JL. Utility of omentoplasty for poststernotomy mediastinitis secondary to myocardial revascularization surgery. [Article in Spanish]. *Arch Bronconeumol* 2008; 44: 113-115.