

Use of gentamicin-collagen sponges prior to sternal closure may lower the risk of sternal wound infection: a single center experience

Użycie gąbek kolagenowych z gentamycyną przed zamknięciem mostka może obniżyć ryzyko infekcji rany mostka: doświadczenia jednego ośrodka

Júlia Čanádyová, Vojtěch Kurfiršt, Aleš Mokráček

Cardiac Surgery Department, Hospital České Budějovice, Czech Republic

Kardiochirurgia i Torakochirurgia Polska 2012; 9 (4): 415–419

Abstract

Despite improvements in prophylactic strategies, sternal wound infection following cardiac surgery still remains a significant complication, associated with prolonged hospitalization, high costs, patient discomfort and significant mortality. The aim of this study was to evaluate whether the local application of collagen-gentamicin sponges (GMCS) placed between the sternal halves before closure may decrease the incidence of median sternotomy wound infection. Between April 2008 and December 2009, 236 patients were enrolled in the study. We compared 120 consecutive patients whose wounds were closed with the use of collagen-gentamicin sponges (GMCS group) with 116 consecutive patients whose wounds were closed without the use of local antibiotic prophylaxis (non-GMCS group). All postoperative sternal wound complications were referred back to the Cardiac Surgery Department. The three-month incidence of any wound healing complication was the main outcome criterion. The use of GMCS significantly reduced the rate of wound infection to 8.3% vs. 19.8% in the non-GMCS group ($p < 0.0197$). The patients whose wounds were closed without the use of local antibiotic prophylaxis had a higher risk of infection-related complications compared with patients in whom GMCS were used prior to closure (OR = 2.95, 95% CI: 1.29–6.71). Our study demonstrated the benefit of using GMC in reducing the rate of sternal wound infection.

Key words: cardiac surgery, surgical wound infection, gentamicin-collagen.

Streszczenie

Mimo rozwoju strategii profilaktycznych, infekcja rany mostka po operacji kardiologicznej wciąż pozostaje znaczącą komplikacją związaną z długą hospitalizacją, wysokimi kosztami, dyskomfortem pacjenta i znaczącą śmiertelnością. Celem niniejszej pracy była ocena, czy miejscowe stosowanie gąbek kolagenowych z gentamycyną (GMCS), umiejscawianych pomiędzy połowami mostka przed zamknięciem, może zmniejszyć występowanie infekcji rany po przecięciu mostka. Pomiędzy kwietniem 2008 r. a grudniem 2009 r. badanie objęło 236 pacjentów. Porównano 120 kolejnych pacjentów, u których rany zamknięto za pomocą gąbek kolagenowych z gentamycyną (grupa GMCS), ze 116 kolejnymi pacjentami, których rany zamknięto bez użycia miejscowej profilaktyki antybiotykowej (grupa non-GMCS). Wszystkich pacjentów z pooperacyjnymi komplikacjami rany mostka przekazano z powrotem do Katedry Kardiologii. Wystąpienie jakiegokolwiek komplikacji gojenia się rany w ciągu 3 miesięcy było głównym kryterium wyniku. Użycie GMCS znacząco zmniejszyło współczynnik infekcji ran do 8,3%, w porównaniu z 19,8% w grupie non-GMCS ($p < 0,0197$). Pacjenci, u których rany zamknięto bez użycia miejscowej profilaktyki antybiotykowej, byli bardziej narażeni na komplikacje infekcyjne w porównaniu z pacjentami, u których przed zamknięciem użyto GMCS (OR = 2,95, 95% CI: 1,29–6,71). W niniejszej pracy wykazano korzyści płynące z używania GMC w celu zmniejszenia występowania infekcji ran mostka.

Słowa kluczowe: kardiologia, infekcja rany operacyjnej, kolagen z gentamycyną.

Address for correspondence: Júlia Čanádyová, M.D., Cardiac Surgery Department, Hospital České Budějovice, B. Němcové 54, 37001 Czech Republic, Fax: 00420387874201, E-mail: canadyova.julia@gmail.com

Introduction

Despite growing interest in minimally invasive procedures in cardiac surgery, median sternotomy is still the most common approach for open-heart surgery. Notwithstanding the improvements in available prophylactic strategies (i.e. perioperative antibiotic prophylaxis, aseptic surgical technique, and careful postoperative wound management), sternal wound infection continues to be a major and serious problem following cardiac surgery, as it is associated with prolonged hospitalization, patient discomfort, and increased hospital costs [1, 2]. In previous studies, risk factors associated with an increased rate of sternal wound infection were identified [3, 4]. They include patient-related risk factors such as female gender, obesity, insulin-treated diabetes mellitus, smoking, peripheral vascular disease, and chronic obstructive pulmonary disease [3]. Perioperative risk factors include sternotomy, bilateral mammary graft harvesting, excessive coagulation, excessive use of bone wax, and duration of extra-corporal circulation [3, 4]. Postoperative risk factors include re-exploration for bleeding and/or tamponade, higher consumption of blood products, and prolonged lung ventilation [3, 4]. Because the onset of sternal wound infection is often delayed and occurs after the discharge from the hospital, long-term follow-up and cooperation with referring physicians is necessary. The aim of this study was to compare sternal closure with collagen-gentamicin sponge (GMCS) implantation between the sternal halves plus routine intravenous (IV) antibiotics with standard closure plus routine IV antibiotics.

Material and methods

From April 2008 to December 2009, 1171 open-heart operations were performed at the Cardiac Surgery Department, České Budějovice Hospital, Czech Republic. They included routine coronary surgery, valve procedures and complex aortic procedures excluding cardiac transplantation. All postoperative sternal wound complications were referred back to the Cardiac Surgery Department, as this is the only hospital in the region at which cardiac procedures are performed. The catchment area comprises approximately 725 000 people and between 650 and 700 cardiac procedures are undertaken annually.

Two hundred and thirty-six patients were prospectively enrolled in this study, of whom 120 consecutive patients were closed with GMCS (GMCS group) and compared with 116 consecutive patients who were closed normally without the use of local antibiotics (non-GMCS group). Standard perioperative antibiotic prophylaxis with cefazolinum natrium (2 g) was administered intravenously before skin incision and repeated every 8 hours for the first postoperative day.

GMCS consists of a flat absorbable equine collagen sponge containing gentamicin sulfate. A 10 × 10 × 0.5 cm sponge contains 280 mg of collagen and 130 mg of gentamicin. The sponges were cut into three equal sections; two sections of the implant were placed between the sternal halves in one layer immediately before sternal closure after their short wetting in saline. The remaining section of

the sponge was divided in half and placed behind the sternum at the proximal and distal end (Fig. 1). During the study, we adhered to ethical principles based on patients' rights and interests.

Three senior surgeons performed all cardiac operations in the study group of patients. The same assistant surgeon closed the sternum in all enrolled patients, in order to minimize individual differences in closure techniques. It was considered very important to achieve stable sternal approximation.

Patients were followed for the occurrence of any kind of sternal wound infection for 90 days after surgery. Classification of postoperative wound infection was made on the basis of the modified CDC classification described in the work of Friberg [5, 6]. Superficial infections were defined as infections involving skin or subcutaneous tissue. Deep infections were defined as infections involving superficial fascia, wires and bone, with signs of unstable sternum, osteomyelitis, or positive mediastinum culture (Fig. 2). The diagnosis of infection was confirmed by positive bacterial culture results.

Statistical analysis

Standard descriptive statistics are provided. The basic preoperative and intraoperative data between the patient groups were compared statistically using the Mann-Whitney test. Differences in (absolute) frequencies between patients with and without GMCS (with respect to sample size) were analyzed using the Pearson chi-square test. A *p*-value of less than 0.05 was considered to be statistically significant. We also estimated the effect of the two sternal closure techniques on sternal wound infection occurrence by odds ratio and 95% confidence interval (CI).

Results

Baseline demographic and preoperative data for the 236 enrolled patients are presented in Table I. The two groups of patients (the GMCS group and the non-GMCS group) were comparable in terms of attendant risk factors. There were similar




Fig. 1. Collagen – gentamicin sponges between sternal halves

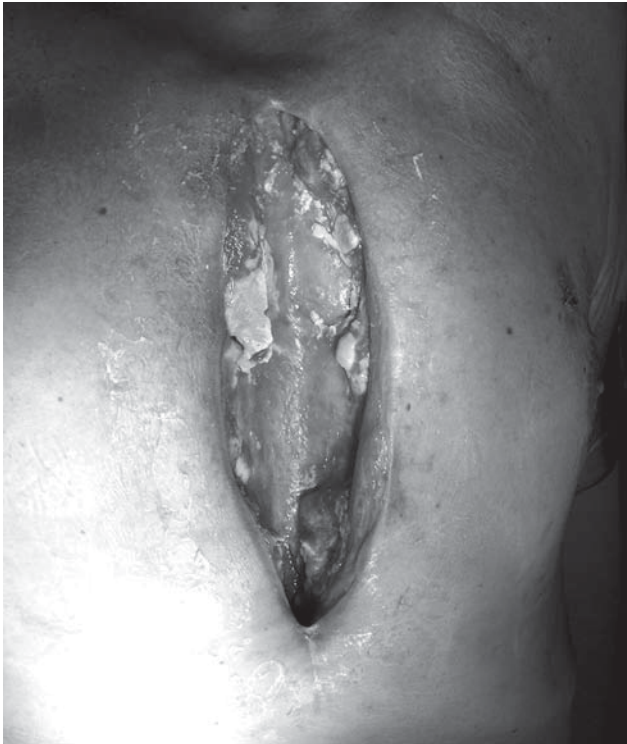

Fig. 2. Deep sternal wound infection

rates of COPD in the two groups and patients had comparable preoperative renal function and left ventricular function. One third of patients in both groups had diabetes mellitus (DM). In the GMCS group, there was a higher proportion of female subjects (39.2% vs. 25.9%, $p = 0.041$) and the patients in this group also had a slightly higher BMI (29.4 vs. 28.1, $p = 0.037$). In the perioperative and early postoperative period, the only difference between the study groups was a higher volume of blood loss in patients in the non-GMCS group (877.5 ml vs. 800 ml, $p = 0.036$). Duration of extra-corporeal circulation (ECC) and cross clamping (Cx) was similar in both groups (Table II).

From the total of 1171 patients operated on between April 2008 and December 2009 sternal wound healing complications occurred in 145 patients (12.4%). In this study, we enrolled 236 patients (20.2% of all patients operated on in this period). The incidence of total infection in the study group during the follow-up period was significantly higher in patients without local antibiotic prophylaxis. Twenty-three patients (19.3%) in the non-GMCS group developed an infection vs. 10 patients (8.3%) in the GMCS group (OR = 2.95, 95% CI: 1.29-6.71) ($p < 0.001$). The rate of superficial sternal infection was higher in the non-GMCS group (73.9%) compared to that observed in the GMCS group (50%). One patient in the non-GMCS group died of mediastinitis 50 days after the primary operation. There was a trend towards later manifestation of infection in patients in the GMCS group; however, this was not statistically significant ($p = 0.6235$). The median time between the operation and the signs of clinical infection was 16 days (3-35 days) for patients in the non-GMCS group compared with 18 days (7-71 days) for patients in the GMCS group.

Tab. I. Baseline characteristics of 236 enrolled patients

Parameter	Non-GMCS	GMCS	P-value
No. of patients	116	120	
Female gender	30 (25.9%)	47 (39.2%)	0.041
Age	65.5	66.9	NS
BMI	28.1	29.4	0.037
COPD	17 (14.7%)	11 (9.2%)	NS
Creatinine	105	97	NS
DM (%)	41 (35.3%)	40 (30.3%)	
Insulin	17 (41.5%)	15 (37.5%)	NS
PAD	15 (36.6%)	15 (37.5%)	
Diet	9 (22%)	10 (25%)	
EF (%)	57.2	59.9	NS

COPD – chronic obstructive pulmonary disease; DM – diabetes mellitus; PAD – peroral antidiabetic

Tab. II. Intra-operative data of 236 enrolled patients

Parameter	Non-GMCS	GMCS	P-value
No. of patients	116	120	
ECC (min)	73.7	71.4	NS (0.19)
Cx (min)	48.8	54.8	NS (0.09)
Ø Blood loss (ml)	877.5	800	0.036
Ø No. of blood products	2.6	3.3	NS (0.98)

ECC – extra-corporeal circulation; Cx – cross clamp; Ø Blood loss – mean volume of blood loss; Ø No. of blood products – mean number of blood products

Many causative microorganisms were isolated in the bacterial cultures. *Staphylococcus aureus* was the predominant cause of infection (50%) in the GMCS group. The five other isolated organisms were coagulase-negative *Staphylococcus* (10%), *Escherichia coli* (10%), *Enterobacter cloacae* (10%), *Enterococcus faecalis* (10%), and *Morganella morganii* (10%).

In the non-GMCS group, coagulase-negative *Staphylococcus* was the most common cause of infection (39.1%). Other organisms responsible for sternal wound infection in this group were *Staphylococcus aureus* (17.4%), *Staphylococcus epidermidis* (13%), *Corynebacterium* species (8.7%), and *Proteus mirabilis* (4.3%). Additionally, a polymicrobial culture was found in one specimen.

Discussion

Wound complications following open-heart surgery represent a significant cause of patient morbidity and mortality. The reported incidence of surgical site infections in the medical literature ranges from 0.9% to 20.0% [3]. The incidence of serious mediastinitis varies between 1 and 2%, and is often a fatal complication, with mortality rates of up to 30% [3]. Reported mortality for deep sternal wound infection varies from 9.8% to 14% [1, 3, 7].

In this prospective study, sternal infections after cardiac surgery occurred in 23 out of 116 patients (19.8%) in the non-GMCS group and in 10 out of 120 patients (8.3%) in the GMCS group during the 3-month follow-up period.

There are several methods by which we can improve the prevention of sternal dehiscence and sternal wound healing complications. These include patient weight reduction prior to surgery and optimizing glycemic control prior to and during the operation, as well as in the early postoperative period – with particular care to be taken during the first month. Zerr *et al.* [8] demonstrated a correlation between higher levels of mean blood glucose in the first 48 hours after surgery and deep sternal wound infection development. Furnary *et al.* [9] in a prospective study observed that intensive glycemic control with continuous intravenous insulin leads to better glucose control and decreased rates of deep sternal infection relative to subcutaneous insulin regimens. Our results confirm that patients with insulin treated DM, compared to patients without DM or DM treated with oral antidiabetic drugs and diet, had a 2.8 times higher risk of developing sternal wound infection (OR = 2.8, 95% CI: 1.13-6.92).

Other ways in which sternal complications can be avoided include improving topical wound antimicrobial preparations, reduction of bone wax, cauterization, and, last but not least, stable and rigid sternal fixation. Different techniques of sternal reinforcement and biomechanical testing of the various sternal wire techniques using *ex vivo* sternal models have been described in the literature [10, 11]. These include the simple wire technique with different numbers of single wires; the original and modified Robicsek closure using two longitudinal, parasternal wires on both sides of the sternum; the interlocking figure-of-8 closure; double crisscross sternal wiring and using sternal bands in high-risk patients [12, 13].

Combining the aforementioned techniques with use of a higher number of single wires (usually 8-10) and especially careful reinforcement of the lower sternum is our preferred approach (Fig. 3). In high-risk patients with osteoporotic bone, or in cases of non-midline sternotomy, we use parasternal wires in combination with the figure-of-8 wire technique and GMCS implantation. Friberg *et al.* concluded that antibiotic prophylaxis with local GMCS was associated with a significant reduction in superficial and deep sternal wound infection [6]. Based on the results of their first randomized trial, local application of GMCS between the sternal halves was associated with a 53% relative reduction (4.7% absolute reduction) in the incidence of sternal wound infection after sternotomy in an unselected cardiac surgery patient population [5].

Our approach to reducing the risk of postoperative sternal wound infection consists in intensive glycemic control with continuous postoperative intravenous administration of insulin, rigid sternal fixation with a higher number of single wires, and (in high-risk patients) the implantation of GMCS before sternal closure.

There are some concerns that the dipping of GMCS in saline for a few seconds prior to application may lead to the leaching of gentamicin from the sponge into the saline, which in turn may reduce efficacy. As a result we have changed our approach and we currently implant dry GMCS

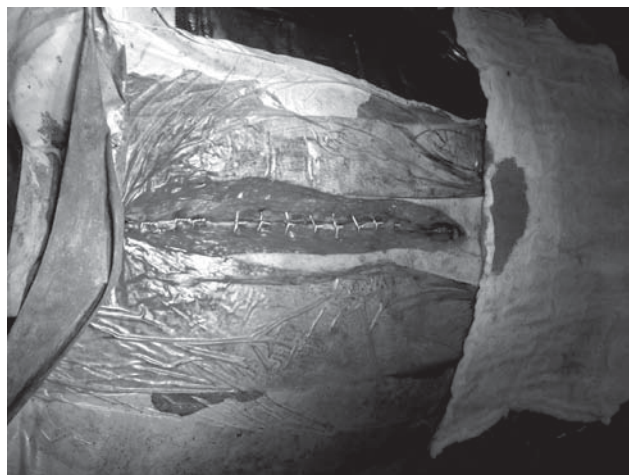

Fig. 3. Sternal fixation with higher number of single wires

between the sternal halves, and to aid manipulation we only moisten the surgical gloves [14].

Conclusions

The aim of our prospective study was to compare sternal closure with collagen-gentamicin sponge implantation between the sternal halves with standard closure without local antibiotics. Between April 2008 and December 2009, 236 patients were enrolled in this study, of whom 120 consecutive patients were closed with local antibiotics. The results of our prospective study have demonstrated the benefit of the GMCS implant in reducing the rate of sternal wound infection in enrolled patients (8.3% vs. 19.8%).

Literature

1. Matros E, Aranki SF, Bayer LR, McGurk S, Neuwalder J, Orgill DP. Reduction in incidence of deep sternal wound infections: random or real? *J Thorac Cardiovasc Surg* 2010; 139: 680-685.
2. Vos RJ, Yilmaz A, Sonker U, Kelder JC, Kloppenburg GTL. Vacuum-assisted closure of post-sternotomy mediastinitis as compared to open packing. *Interact CardioVasc Thorac Surg* 2012; 14: 17-20.
3. Ridderstolpe L, Gill H, Granfeldt H, Ahlfeldt H, Rutberg H. Superficial and deep sternal wound complications: incidence, risk factors and mortality. *Eur J Cardiothorac Surg* 2001; 20: 1168-1175.
4. Losanoff JE, Richman BW, Jones JW. Disruption and infection of median sternotomy: a comprehensive review. *Eur J Cardiothorac Surg* 2002; 21: 831-839.
5. Friberg O, Svedjeholm R, Soderquist B, Granfeldt H, Vikerfors T, Källman J. Local gentamicin reduces sternal wound infections after cardiac surgery: a randomized controlled trial. *Ann Thorac Surg* 2005; 79: 153-161.
6. Friberg O, Dahlin LG, Källman J, Kihlstrom E, Soderquist B, Svedjeholm R. Collagen-gentamicin implant for prevention of sternal wound infection, long-term follow-up of effectiveness. *Interact CardioVasc Thorac Surg* 2009; 9: 454-458.
7. Borger MA, Rao V, Weisel RD, Ivanov J, Cohen G, Scully HE, David TE. Deep sternal wound infection: risk factors and outcomes. *Ann Thorac Surg* 1998; 65: 1050-1056.
8. Zerr KJ, Furnary AP, Grunkemeier GL, Bookin S, Kanhere V, Starr A. Glucose control lowers the risk of wound infection in diabetics after open operations. *Ann Thorac Surg* 1997; 63: 356-361.
9. Furnary AP, Zerr KJ, Grunkemeier GL, Starr A. Continuous intravenous insulin infusion reduces the incidence of deep sternal wound infection in diabetic patients after cardiac surgical procedures. *Ann Thorac Surg* 1999; 67: 352-362.

10. Schimmer CH, Reents W, Berneder S, Eigel P, Sezer O, Scheld H, Sahraoui K, Gansera B, Deppert O, Rubio A, Feyrer R, Sauer C, Elert O, Leyh R. Prevention of sternal dehiscence and infection in high-risk patients: a prospective randomized multicenter trial. *Ann Thorac Surg* 2008; 86: 1897-1904.
11. Casha AR, Yang L, Kay PH, Saleh M, Cooper GJ. A biomechanical study of median sternotomy closure techniques. *Eur J Cardiothorac Surg* 1999; 15: 365-369.
12. Dahlin LG, Granfeldt H, Hultkvist H. A multimodal approach for reducing wound infections after sternotomy. *Interact CardioVasc Thorac Surg* 2004; 3: 206-210.
13. Dasila UK, Trumble DR, Magovern JA. Lower sternal reinforcement improves the stability of sternal closure. *Ann Thorac Surg* 2003; 75: 1618-1621.
14. Corn T. Treating sternal wound infections after cardiac surgery with an implantable gentamicin-collagen sponge. *Letter. J Am Med Assoc* 2010; 304: 2123.