

Successful management of a retrosternal goiter in a patient with Bernard-Soulier syndrome

Massine el Hammoumi, el Hassane Kabiri

Department of Thoracic Surgery, Mohammed V Military Teaching Hospital, Rabat, Morocco

Kardiocirurgia i Torakochirurgia Polska 2022; 19 (2): 102



A 45-year-old man presented to our department with a one-year history of dyspnea. Physical examination revealed a huge goiter in the neck. Computed tomography (CT) scan confirmed the diagnosis of a huge plunging goiter (25 cm × 10 cm) (Figures 1 A–C). The preoperative biological data were normal except for thrombocytopenia of 145,000/mm³. This thrombocytopenia was not important to investigate other biological data especially with normal coagulation data (prothrombin and activated partial thromboplastin time). A cervico-sternotomy was performed but abnormally diffuse tissue bleeding was observed. Blood loss was estimated at 1200 ml. An initial transfusion of two units of blood and two units of platelets (total of 12) resulted in relative control of the bleeding. It was decided to continue transfusion of platelets (10 pellets) and one frozen plasma pellet to maintain hemostasis. Surgical removal of the goiter was ultimately successful with the use of fusion/division energy. On the first postoperative day, the diagnosis of Bernard-Soulier syndrome (BSS) was obtained after a blood smear showing macro-thrombocytopenia. Continuous platelet transfusion was therefore indicated to maintain a correct platelet level. Tranexamic acid was not indicated because of the patient's obesity and the associated cardiac risk. The postoperative course was uneventful.

The patient was discharged from the hospital 3 days after surgery and transferred to the hematology unit for further follow-up. He was discharged 2 days later. This very rare BSS thrombocytopathy is related to inherited defects in the platelet glycoprotein complex Ib/V/IX, large platelets and thrombocytopenia. Major surgery is challenging for patients with coagulopathies, especially BSS. In this case, we successfully performed thyroidectomy under perioperative platelet transfusion. Consensus guidelines are necessary to better manage this bleeding coagulopathy to prevent diagnostic complications. Scheduled high-risk surgery should always be associated with strict normal biological data [1–3].

Disclosure

The authors report no conflict of interest.

References

1. Riffat F, Del Pero MM, Fish B, Jani P. Radiologically predicting when a sternotomy may be required in the management of retrosternal goiters. *Ann Otol Rhinol Laryngol* 2013; 122: 15-9.

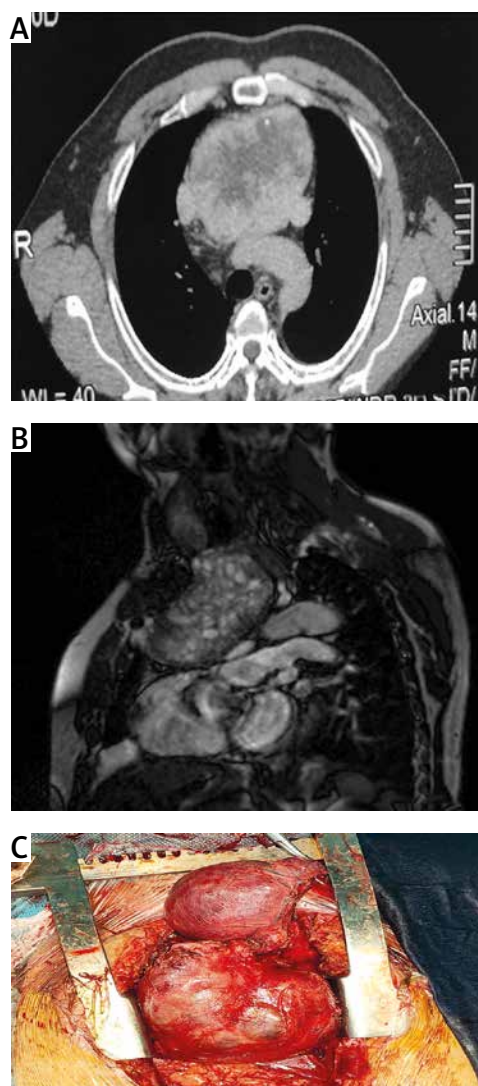


Figure 1. A – Transversal view of a CT scan showing the huge plunging goiter. B – Sagittal view of a CT scan showing the huge retrosternal goiter. C – Perioperative view of the cervical and thoracic part of the goiter extirpated via a cervico-sternotomy

- Lin YS, Wu HY, Lee CW, Hsu CC, Chao TC, Yu MC. Surgical management of substernal goitres at a tertiary referral centre: A retrospective cohort study of 2,104 patients. *Int J Surg* 2016; 27: 46-52.
- Tang AL, Falciglia M, Yang H, Mark JR, Steward DL. Validation of American Thyroid Association ultrasound risk assessment of thyroid nodules selected for ultrasound fine-needle aspiration. *Thyroid* 2017; 27: 1077-82.

Address for correspondence: Prof. Massine el Hammoumi, Department of Thoracic Surgery, Mohammed V Military Teaching Hospital, Rabat, Morocco, e-mail: hamoumimassine@hotmail.fr

Received: 2.11.2021, **accepted:** 28.02.2022.