

Zenker's diverticulum: aetiopathogenesis, symptoms and diagnosis. Comparison of operative methods

Piotr Nehring¹, Ireneusz W. Krasnodębski²

¹Students' Scientific Group at Department of General, Gastroenterological and Oncological Surgery, Medical University of Warsaw, Poland

²Department of General, Gastroenterological and Oncological Surgery, Medical University of Warsaw, Poland

Prz Gastroenterol 2013; 8 (5): 284–289

DOI: 10.5114/pg.2013.38729

Key words: fiberoptic endoscopy, diverticulum, Zenker's.

Address for correspondence: Prof. Ireneusz W. Krasnodębski MD, PhD, Department of General, Gastroenterological and Oncological Surgery, Medical University of Warsaw, 1 A Banacha St, 02-097 Warsaw, Poland, phone: +48 22 599 22 57, fax: +48 22 599 20 57, e-mail: gastrochirurgia@wum.edu.pl

Abstract

Zenker's diverticulum is an alimentary tract pouch localized in the area of the upper esophageal sphincter. Treatment procedure complications and coexisting diseases constitute a serious diagnostic and therapeutic problem. Characteristic symptoms and signs facilitate differential diagnosis, simultaneously being real patient maladies. There are many treatment procedures leading to pouch septum reduction and decrease of upper esophageal sphincter pressure. After years of experience in operating and endoscopic treatments we found it necessary to compare these different methods.

Introduction

Zenker's diverticulum (ZD) was first described in 1877 by German pathologists Friedrich Albert von Zenker and Hugo Wilhelm von Ziemssen. However, the first observation was made by Abraham Ludlow in 1679 [1–3]. Zenker's diverticulum is a rare condition, but it is the most common diverticulum in the upper gastrointestinal tract. Less common locations are midesophageal and supradiaphragmatic [1]. The incidence rate is 0.01–0.11% in the American population and it occurs more often in men with the peak incidence between the 7th and 9th decade of life [1, 4–6].

Zenker's diverticulum is commonly located on the posterior pharyngeal wall within the upper esophageal sphincter (UES) between the lower pharynx and esophagus [7, 8]. It may occur above the UES in the lower pharyngeal sphincter muscle suture line, less commonly in the lateral or posterolateral esophageal wall. There are also a few case reports on double diverticulum occurrence in these localizations [4].

The length of ZD may reach up to 15 cm, but diverticula of that size are very rare [9]. More frequently ZD are less than 4 cm in length. According to Morton-Bartney's classification, diverticula are divided into small (less than 2 cm), medium (between 2 cm and 4 cm),

and large (more than 4 cm) [4]. Other classifications compare the length of the diverticulum to the cervical spine vertebrae indicated on the radiograms. According to these classifications, small diverticula are shorter than one vertebra, whereas large ones are longer than three vertebrae [4]. Histologically, ZD is composed of all esophageal wall layers: mucosa membrane, submucosal membrane, muscle layer and adventitia [1, 4–6, 10].

The most common muscle structure where ZD is located is Killian's triangle. It is a space on the posterior esophageal wall limited by the thyropharyngeal muscle at the top, and cricopharyngeal muscle fibers at the bottom that compose the UES [4, 5]. Killian's triangle is the location of the highest susceptibility to create diverticula (*locus minoris resistentiae*). The second location of lower resistance in the esophageal wall is Killian-Jemison's space. For pouches in this location the lateral position of the diverticulum is characteristic [5].

In relation to the esophageal lumen, ZD may occur in different positions (Figure 1). Most commonly ZD occurs with the fundus at the bottom and the entrance at the top, which makes the highest risk of retention of ingesta [7].

Zenker's diverticulum occurrence is the consequence of esophageal mucosa membrane weakening with

coexisting increase in UES tension. The increase in pressure during ingesta swallowing pushes esophageal tissue layers outside the esophagus to the mediastinum retropharyngeal space, forming a pouch with gates limited by muscles [1]. Increase in pressure of the cricopharyngeal muscle results in decreased UES relaxation and subsequent further increase in pressure within the sphincter. The described mechanism results in the creation of an alternative route for ingesta [1, 4]. Individual susceptibility to diverticula occurrence is caused by fibrosis and histologically described inflammation within Killian's triangle muscles fibers [5, 11].

The muscle dysfunction may be the consequence of diseases causing esophagus contraction, e.g. achalasia. In other cases the reason may be gastro-esophageal reflux disease with cricopharyngeal muscle cramp [12].

A genetic predisposition to ZD occurrence has not been proven so far. The existence of such a predisposition is possible due to described congenital UES muscle weakness [11]. Zenker's diverticulum is located more often on the left side of the esophageal wall, which has given rise to the suggestion that ZD occurrence may be dependent on whether the individual is right- or left-handed. In right-handed patients diverticulum more often occurs on the left side of the esophagus [4].

Diagnosis

Zenker's diverticulum manifests itself with characteristic symptoms and signs. The first and most common symptom is a gradually increasing dysphagia [5, 7, 13]. In consequence of regurgitations the aspiration of ingesta into the bronchial tree may appear and subsequent dyspnea due to Mendelson's syndrome. Characteristic are loud swallowing of liquids, cough and

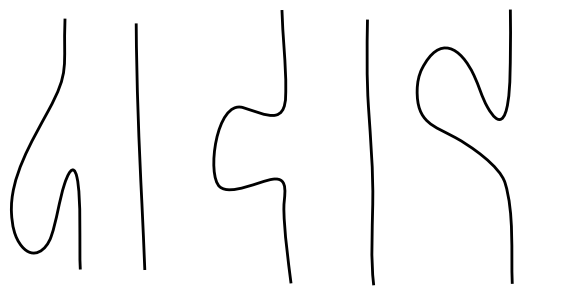


Figure 1. Ways of emptying Zenker's diverticulum to digestive tract lumen

Table I. Selected presenting complaints of patients with Zenker's diverticulum [5, 7, 13]

Dysphagia	80–90%
Regurgitation	60%
Cough	30–40%
Loud swallowing of liquids	30%
Hoarseness	20%
Loss of body weight	20%
Foreign body in throat sensation	20%

hoarseness [5]. Over time the diverticulum grows and patients complain of dysphagia due to esophagus constriction by the filled diverticulum. Voice alteration and halitosis may also occur (Table I).

Zenker's diverticulum may be perceptible in physical examination as a tumor in the neck. During palpation Boyce's sign may be triggered – a noise of splashing fluid accumulated in the diverticulum. The diagnosis is based on a radiogram with barite that reveals a diverticulum filled with contrast on the side of the esophagus [14].

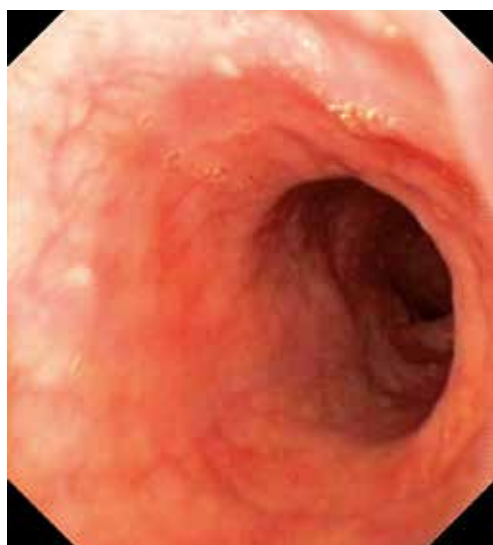


Figure 2. Normal esophagus

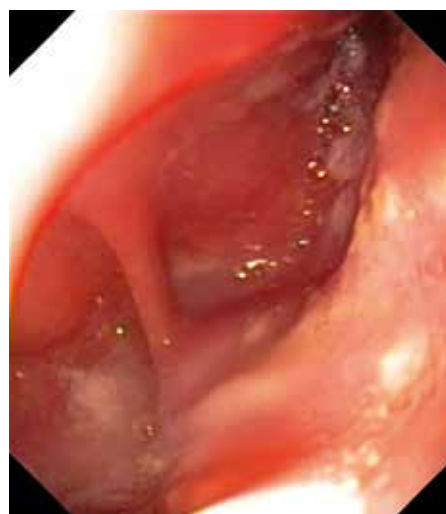

Figure 3. Typical medium sized Zenker's diverticulum

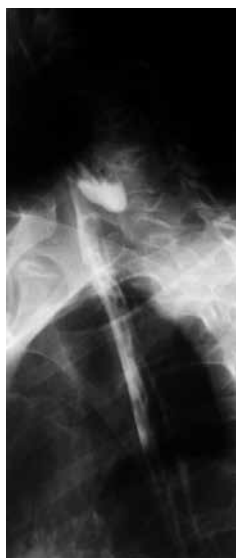

Figure 4. Corresponding radiological image of Zenker's diverticulum

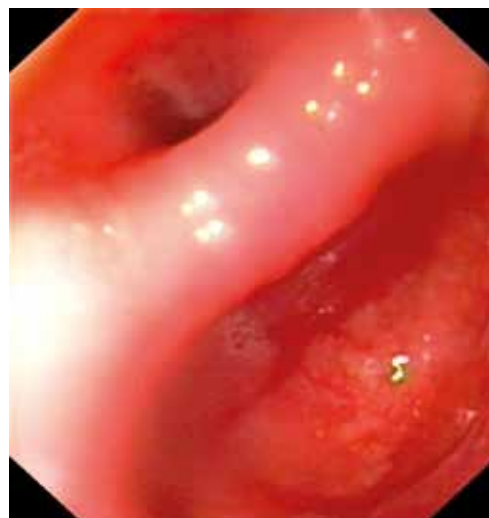

Figure 5. Septum between diverticulum (right) and esophageal lumen (left)

Esophagogastroduodenoscopy may be useful in ZD and operation conditions assessment (Figures 2–5). Another valuable, but technically difficult examination is UES manometry. Manometry is not useful in the routine diagnostic approach due to, among others, catheter dislocation during examination impeding the proper analysis.

Treatment

The decision on the therapeutic approach depends on diverticulum size and clinical manifestation. Usually, ZD that are less than 1 cm in length, asymptomatic and incidentally revealed are disqualified from intervention. In such cases, ZD is treated conservatively, until symptoms occurrence or diverticulum enlargement. For ZD larger than 5 cm in length, the classic operating method is preferred, whereas diverticula less than 2 cm long are usually treated with endoscopic methods [10]. Some centers prefer treatment with fiberoptic endoscopy irrespectively of diverticulum size. The endoscopic approach should be considered in those patients who are disqualified from general anesthesia, or due to age and coexisting conditions are unable to undergo an operation.

There are several therapeutic approaches concerning open and endoscopic treatment. Open surgery may be performed in combination with cricomyotomy, or, less commonly, without myotomy.

Conservative treatment is adapted in case of contraindications to surgery. The best therapeutic effect is achieved by using calcium channel antagonists and nitrates. In some centers injections with botulinum toxin within UES is implemented in order to decrease sphincter tension [15].

Diverticulopexy consists of anchorage of the diverticular pouch to the posterior pharyngeal wall or to the prevertebral fascia. It is commonly performed in combination with cricopharyngeal myotomy, resulting in decrease of muscular tension within the UES.

Diverticulectomy is a total diverticular pouch resection performed commonly in combination with cricomyotomy. This method is still the most common therapeutic approach. The open surgery is performed through left cervical incision [1, 15, 16]. Open surgery is recommended for small or very large ZD or in patients at low surgical risk.

Endoscopic treatment with a rigid Weerda diverticuloscope consists of dividing the septum between the diverticula and the esophageal wall simultaneously with suturing the diverticular and esophageal walls using a laparoscopic stapler. During septotomy, the anterior wall of the ZD and the posterior wall of the esophagus are sealed with a double row of staples [4, 10, 15, 17–21].

The endoscopic approach with a fiberoptic endoscope is similar to treatment with a Weerda diverticuloscope concerning diverticulostomy as a therapeutic aim. The approach to the operating area and obtaining a good view of the septum are very easy using a flexible endoscope. Dividing the septum between the esophagus lumen and the diverticulum using a fiberoptic endoscope is valuable in elderly patients at high surgical risk or with other contraindications [2]. In this method, there is no need to obtain deep head pronation to insert a rigid endoscope. The endoscopic approach is assisted with three main techniques: argon plasma coagulation

(APC) or the CO₂-laser, needle-knife incision, and monopolar forceps coagulation.

Using monopolar forceps, a part of the septum between the diverticulum and the esophagus is caught with forceps and an incision is made with coagulation. Christiaens *et al.* [13] suggested that this method is tolerated very well due to limited endoscope manipulations. All manipulations are performed with instruments entered through the endoscope biopsy working channel. The procedure is commonly assisted with a nasogastric tube not only to better visualize the area of septum incision but also to protect the anterior esophageal wall against thermal injury during diverticulostomy.

The endoscopic procedure assisted with needle-knife may be performed both from the diverticulum and esophagus lumen depending on the individual variability [2, 5]. The incision is performed from the septum edge towards the fundus of the diverticulum with a 2–3 cm tissue margin left [2]. Due to better incision area exposure, a cap inserted on the endoscope is commonly used. This method is preferred in individuals whose septum between the diverticulum and esophageal lumen and ZD is easily endoscopically visualized. In order to protect against esophagus perforation, endoclips are applied on the septum tissue remains. The endoclips protect against incision enlargement. The recurrence of symptoms is observed in up to 20% of patients who undergo this procedure and the incision with the needle-knife was not sufficiently extended [5].

Argon plasma coagulation and CO₂-laser are non-contact methods. The incision with APC is performed starting from the lowest desired point of the septum near the ZD fundus towards the edge of the septum between the diverticulum and esophageal lumen. There is also a possibility to start the incision on the septum and moving towards the fundus of the diverticulum. In some cases, two procedures are performed to obtain full septotomy. Usually two procedures are performed with a 2-day interval leading to separate diverticular and esophageal lumens gradually [5].

In the postoperative period, some clinicians recommend performing chest radiography in order to exclude pneumomediastinum and subcutaneous emphysema. The presence of air in the mediastinum is diagnosed in up to 23% of patients [2, 22]. Another severe complication of ZD treatment is bleeding into the gastrointestinal tract, occurring in 0–10% of cases. The site of bleeding may be treated with APC, endoclips, epinephrine injection, biopsy forceps or with needle-knife coagulation [5] (Figure 6–8).

There is no need of special postoperative treatment in patients treated endoscopically. The first liquid meals

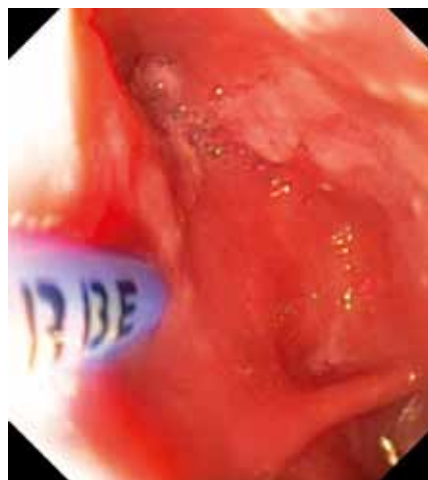


Figure 6. APC catheter at position before starting cutting the septum

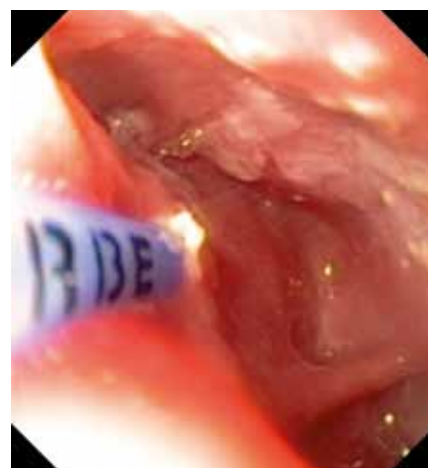


Figure 7. Beginning of coagulation using APC catheter

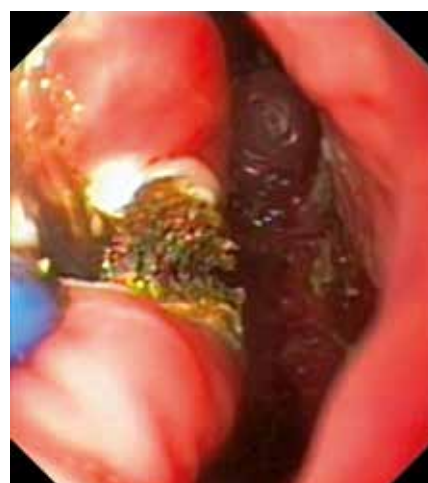

Figure 8. The septum is now partially cut from the upper part

Table II. Comparison of fiberoptic endoscopic procedures. Arithmetic mean value of original research outcomes [2, 22, 24–28]

Technique	Bleeding [%]	Emphysema [%]	Number of procedures (mean)	Recurrences [%]	Symptoms relief [%]
APC [24, 25]	1.6	10.5	2.4	17	97.5
Needle-knife [2, 22, 26, 27]	5.45	14	1.33	15	86.7
Monopolar forceps coagulation [28]	0	0	3	No data	No data

are provided parenterally as early as 1–2 days after the procedure under condition of perforation, pneumomediastinum or bleeding presence exclusion. Solid meals are incorporated gradually into the diet.

The surgical approach, in comparison with stapler-assisted endoscopic treatment, is associated with a longer period of hospitalization (5–6 days) and feeding through a nasogastric tube in order to facilitate the pharyngotomy wound healing process. Oral feeding is implemented after 5–6 days in comparison with 2 days after the stapler-assisted procedure [10, 15]. There are also differences in procedures length. According to Smith, Genden and Urken, the mean surgical operation lasts 87.6 ± 35.1 min [15]. There are no significant differences in costs between open and endoscopic approaches; however, surgically treated patients stay longer in hospital, increasing total expenses [10, 15, 19]. Studies showed no differences in clinical recovery between patients treated surgically and endoscopically [15]. Costantini *et al.* presented studies showing higher symptoms relief frequency after open surgery in comparison with stapler-assisted treatment in groups with ZD < 3 cm long (98% vs. 57%) and with ZD > 3 cm long (96% vs. 80%) [10]. Studies suggest that the frequency of reoperations is higher in the group of patients treated endoscopically. This percentage is higher probably due to the shorter septum incision in the endoscopic approach (usually 1.5–2.0 cm) and/or because of the safeness and easiness of this procedure, in comparison with surgical treatment which is performed less willingly [2, 10].

Patients are hospitalized longer and oral feeding is implemented later in the case of diverticulum resection with or without myotomy compared to all endoscopic procedures and classic myotomy with or without ZD anchorage [23]. The time of hospitalization and time of oral food implementation are shorter in patients treated with the stapler-assisted method in comparison with fiberoptic endoscopic methods [3, 23].

There are several differences between rigid endoscope and fiberoptic endoscope procedures. In the rigid endoscope approach, the operation is conducted

by a surgeon and performed under general anesthesia with deep head pronation. Fiberoptic endoscope assisted technique is performed with a standard endoscope by a gastroenterologist. The patient is usually under deep sedation or general anesthesia. The comparison of fiberoptic endoscopic septotomy techniques aims to evaluate therapeutic effects using the frequency of symptoms demonstrated in point scales assessed before and after the procedure (Table II).

Complications

During a flexible upper endoscopy there is a risk of ZD perforation. The magnitude of this risk is difficult to assess because small diverticula are mostly undiagnosed during endoscopy in patients with unrelated symptoms. An undiagnosed ZD may make endoscopy difficult and, due to manipulations in the diverticulum lumen, lead to gastrointestinal tract perforation. Attempts to examine the ZD with the endoscope are also at risk of perforation. Diverticula filled with undigested food usually displace the esophagus lumen, and in consequence promote endoscope insertion. Endoscopes with axial and lateral optics are at risk of diverticulum perforation, because the moment of endoscope insertion through the UES is performed blind. The difficulty in endoscope insertion is an indication to interrupt the procedure [4]. In order to avoid undiagnosed ZD perforation, chest X-ray with barium contrast may be performed prior to flexible upper endoscopy.

The most frequent complications of ZD are bezoar formation, foreign body presence, fistula between the diverticulum and trachea lumen formation, vocal cords paralysis due to the impact of undigested food, fistula to the prevertebral ligament formation with cervical vertebrae malacia, ventricular ulceration formation and bleeding into the gastrointestinal tract [29].

Patients with ZD are at risk of neoplasia in the diverticulum. The most common is a squamous planoepithelial carcinoma, present in 0.4–1.5% of individuals [4, 5]. Squamous planoepithelial carcinoma is most often located in the 2/3 lower part of the pouch. The risk of neoplasia occurrence is higher in the group with ZD due

to the presence of chronic inflammation inside the diverticulum as a consequence of undigested food degradation. The biopsy of pouch fundus mucosa should be routinely performed for neoplasia exclusion. In patients with ZD there were more often described tumors of the plain muscles and of thyroid cartilage [5].

Although characteristic symptoms of ZD are less frequently present in patients comparing to dyspepsia, gastroesophageal reflux disease or irritable bowel syndrome, its presence should be always taken into consideration during differential diagnosis of diseases of the digestive tract [30].

Summary

Zenker's diverticulum is a rare upper gastrointestinal tract condition. The possibility of its presence should always be considered in clinical practice not only due to the severe consequences, but also due to the existence of effective therapeutic methods when diagnosed. There is substantial progress in endoscopic techniques for ZD treatment; however, the effectiveness needs further consideration and assessment in comparison to the open surgery approach.

References

- Lerut T, Coosemans W, Decaluwe H, et al. Zenker's diverticulum. *Multimedia Manual of Cardiothoracic Surgery* 2009; 224: 2881.
- Vogelsang A, Preiss C, Neuhaus H, Schumacher B. Endotherapy of Zenker's diverticulum using the needle-knife technique: long-term follow-up. *Endoscopy* 2007; 39: 131-6.
- Coticello S, Giordano C, Succo G, et al. Endoscopic diverticulotomy for the treatment of Zenker's diverticulum. *International Congress Series* 2003; 1240: 901-6.
- Siddiq MA, Sood S, Strachan D. Pharyngeal pouch (Zenker's diverticulum). *Postgrad Med J* 2001; 77: 506-11.
- Ferreira LEVV, Simmons DT, Baron TH. Zenker's diverticula: pathophysiology, clinical presentation, and flexible endoscopic management. *Dis Esophagus* 2008; 21: 1-8.
- Watemberg S, Landau O, Avrahami R. Zenker's diverticulum: reappraisal. *Am J Gastroenterol* 1996; 91: 1494-8.
- Silverstein FE, Tytgat GNJ. Atlas of gastrointestinal endoscopy. *Medycyna Praktyczna, Krakow* 1998; 30-2.
- Błachut K, Poniewierka E, Kempieński R. Clinical importance of upper digestive tract diverticula. *Gastroenterol Pol* 2004; 11: 355-64.
- Grabowski K, Milnerowicz S, Taboła R. Large Zenker's diverticulum as a cause of high obstruction of the esophagus. *Gastroenterol Pol* 2005; 12: 545-7.
- Constantini M, Zaninotto G, Rizzetto C, et al. Oesophageal diverticula. *Best Pract Res Clin Gastroenterol* 2004; 18: 3-17.
- Cook IJ, Blumbergs P, Cash K, et al. Structural abnormalities of the cricopharyngeus muscle in patients with pharyngeal (Zenker's) diverticulum. *J Gastroenterol Hepatol* 1992; 7: 556-62.
- Veenker EA, Andersen PE, Cohen JJ. Cricopharyngeal spasm and Zenker's diverticulum. *Head Neck* 2003; 25: 681-94.
- Christiaens P, Roock De W, Olmen V, et al. Treatment of Zenker's diverticulum through a flexible endoscope with a transparent oblique-end hood attached to the tip and a monopolar forceps. *Endoscopy* 2007; 39: 137-40.
- Stemerma DH, Mercader V, Kramer G, et al. An unusual presentation of Zenker's diverticulum. *Clin Imaging* 1996; 20: 112-4.
- Smith SR, Genden EM, Urken ML. Endoscopic stapling technique for the treatment of Zenker diverticulum vs standard open-neck technique. *Arch Otolaryngol Head Neck Surg* 2002; 128: 141-4.
- Minneci PC, Mathisen DJ. Minor challenges: modified diverticulectomy and myotomy for recurrent Zenker diverticulum. *J Thorac Cardiovasc Surg* 2003; 125: 969-71.
- Collard JM, Otte JB, Kestens PJ. Endoscopic stapling technique of esophagodiverticulostomy for Zenker's diverticulum. *Ann Thorac Surg* 1993; 56: 573-6.
- Dohlman G, Mattsson O. The endoscopic operation for hypopharyngeal diverticula. *Arch Otolaryngol* 1960; 71: 744-52.
- Bonavina L, Bona D, Abraham M, et al. World J Gastroenterol 2007; 13: 2586-9.
- Vogelsang A, Schumacher B, Neuhaus H. Therapy of Zenker's diverticulum. *Dtsch Arztebl Int* 2008; 105: 120-6.
- Maune S. Carbon dioxide laser diverticulostomy: a new treatment for Zenker diverticulum. *Am J Med* 2003; 115: 172-4.
- Costamagna G, Iacopini F, Tringali A, et al. Flexible endoscopic Zenker's diverticulotomy: cap-assisted technique vs diverticuloscope-assisted technique. *Endoscopy* 2007; 39: 146-52.
- Gutschow CA, Hamoir M, Rombaux P, et al. Management of pharyngoesophageal (Zenker's) diverticulum: which technique? *Ann Thorac Surg* 2002; 74: 1677-83.
- Mulder CJ. Zapping Zenker's diverticulum: gastroscopic treatment. *Can J Gastroenterol* 1999; 13: 405-7.
- Rabenstein T, May A, Michel J, et al. Argon plasma coagulation for flexible endoscopic Zenker's diverticulotomy. *Endoscopy* 2007; 39: 141-5.
- Ishioka S. Endoscopic incision of Zenker's diverticula. *Endoscopy* 1995; 27: 433-7.
- Hashiba K, de Paula AL, de Silva JG, et al. Endoscopic treatment of Zenker's diverticulum. *Gastrointest Endosc* 1999; 49: 93-7.
- Mulder CJ, den Hartog G, Robijn R, et al. Flexible endoscopic treatment of Zenker's diverticulum: a new approach. *Endoscopy* 1995; 27: 438-42.
- Sen P, Kumar G, Bhattacharyya AK. Pharyngeal pouch: associations and complications. *Eur Arch Otolaryngol* 2006; 263: 463-8.
- Ziółkowski BA, Pacholec A, Kudlicka M, et al. Prevalence of abdominal symptoms in the Polish population. *Prz Gastroenterol* 2012; 7: 20-5.

Received: 29.11.2011

Accepted: 23.05.2012