

Recurrent atypical giant meningioma in the third ventricle of a child

Song-Ping Zheng, Chao You, Yan Ju

Department of Neurosurgery, West China Hospital of Sichuan University, Chengdu, China

Neuropsychiatria i Neuropsychologia 2016; 11, 1: 35–38

Address for correspondence:

Yan Ju
Department of Neurosurgery
West China Hospital of Sichuan University
No. 37, Guoxue Alley, Chengdu
Sichuan Province, China, 610041
e-mail: 13618088051@163.com

Abstract

This article reports the first case of recurrent atypical meningioma in the third ventricle of a 12-year-old boy. As tumor invasion into cerebral tissues signifies a higher recurrence rate, complete excision of the tumor under the microscope without injury to normal cerebral tissues is essential. Follow-up examinations must be conducted for a sufficient length of time to detect early recurrence and provide timely treatment.

Key words: atypical meningioma, third ventricle, recurrence, pediatric.

Introduction

Meningioma originates from arachnoid cap cells and represents approximately 3% of primary intracranial tumors in children (Bhatoe *et al.* 2006). Most meningiomas are benign and occur by the side of the cerebral falx, on the cerebral convex, and on the sphenoidal ridge. Intraventricular meningiomas, especially of the third ventricle, are rare. This article reports and discusses a case of recurrence of a giant atypical meningioma in the third ventricle of a child.

Case report

A 12-year-old boy sought medical treatment in our hospital after suffering from headache for one and a half months, aggravated and accompanied by vomiting, and one week of gait dysfunction. A nervous system test found ataxia in the patient, and no other positive signs were present. Laboratory examinations found no significant abnormal conditions. Cerebral enhanced MRI showed a giant spherical space-occupying lesion in the third ventricle measuring 4.5 cm × 4 cm × 3 cm. The lesion entered the lateral ventricle upward and the anterior brain stem downward. The tumor showed low and high signals at T1 and T2, respectively, and was significantly

homogeneously enhanced after injection of gadolinium. Tumor excision was performed via a right frontal transcortical-transventricular approach. During surgery, the tumor was observably grey in color, tenacious, and had a sufficient blood supply. Borders with peripheral cerebral tissues were unclear. Total removal of the tumor under a microscope was successfully completed. The type of tumor could not be determined from an intraoperative frozen section. The postoperative pathological report showed that the tumor was atypical meningioma (WHO II), and r-knife treatment was supplemented. The condition of the patient significantly improved, and he was discharged. Nineteen months after surgery, the patient was readmitted to our hospital for headache and vomiting. Cerebral enhanced MRI indicated a homogeneous enhanced nodule in the third ventricle measuring approximately 2 cm × 2 cm × 2 cm, causing mild hydrocephalus (Fig. 1). Tumor excision via the same incision approach was performed once more. The recurrent tumor wrapped around the right middle cerebral artery; hence, subtotal removal was performed. The condition of the patient improved after surgery, and he was transferred to the Department of Oncology for whole-brain radiotherapy.

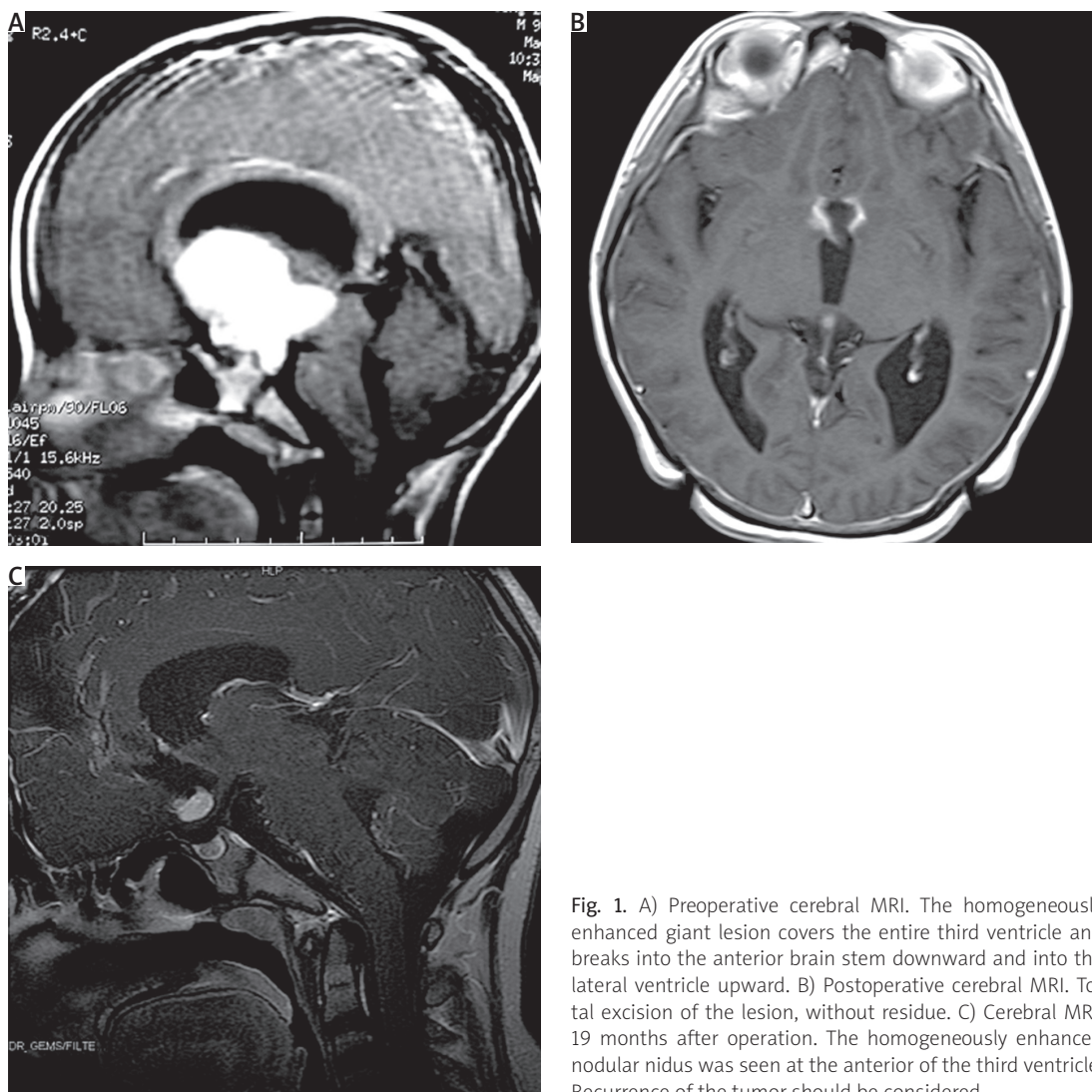


Fig. 1. A) Preoperative cerebral MRI. The homogeneously enhanced giant lesion covers the entire third ventricle and breaks into the anterior brain stem downward and into the lateral ventricle upward. B) Postoperative cerebral MRI. Total excision of the lesion, without residue. C) Cerebral MRI, 19 months after operation. The homogeneously enhanced nodular nidus was seen at the anterior of the third ventricle. Recurrence of the tumor should be considered

Discussion

Meningioma of the third ventricle usually obstructs the circulation of cerebrospinal fluid, resulting in hydrocephalus, which increases intracranial pressure. Vision loss, endocrine diseases, and ataxia could also occur as the tumor oppresses peripheral structures (Buetow *et al.* 1991; Hug *et al.* 2000). Similar to most benign meningiomas, the reported atypical meningioma in the third ventricle presented a homogeneously enhanced nidus in cerebral CT and MRI and caused varying degrees of hydrocephalus in the child. Although such cases are rare, the possibility of meningioma should be considered preoperatively.

Given that the lateral ventricle was enlarged significantly and the tumor broke into the lateral ventricle, excision of the tumor in the third ventricle via a right frontal transcortical-transventricular approach was performed under

a microscope. The peripheral structure of the third ventricle is important. The blood supply of the tumor mainly originates from the medial posterior choroidal vessels. The essence of surgical removal is to protect normal nervous tissues around the lesion, to perform intratumoral excision carefully while avoiding traction, and to conduct border separation.

Pathologically, with reference to earlier studies of the WHO, the likelihood of recurrence of meningiomas with brain invasion is significantly high. During the latest re-grading of meningiomas by the WHO, “invasion into cerebral tissues” was added as one of the diagnostic criteria for atypical meningiomas (Huang *et al.* 1993). In the pathological section of the present case, tumor invasion into the cerebral parenchyma was seen (Fig. 2). With hematoxylin and eosin and phosphohistone-H3 staining, abnormal karyomitosis was observed to occur in less than

4 per 10 high-power fields. Immunohistochemical analysis indicated the following results: tumor cells GFAP(-), S100(-), Syn (-), EMA(-), 5% positive rate of Ki67. Tumor invasion into the cerebral parenchyma was observed in focal areas. Therefore, the case was diagnosed as an atypical meningioma (WHO level II).

In the existing English literature, only two cases of atypical meningioma in the third ventricle of children have been reported (Buetow *et al.* 1991; Komotor *et al.* 2012). This article reports the first case of recurrent atypical meningioma in the third ventricle of a child. With simple surgery, the recurrence rate of atypical meningiomas in five years is nearly 40% (Louis *et al.* 2007). The longest follow-up duration for children with atypical meningiomas in the third ventricle has been reported to be only one year. The long-term effects are unknown.

The scope of tumor excision is the main factor determining the recurrence of atypical meningiomas (Song *et al.* 2008). However, for third ventricle meningiomas with unclear borders, over-excision could injure the nervous system and blood vessels around the third ventricle, causing serious postoperative complications or neural functional damage. Therefore, excision of the lesion to the greatest extent without damage to important structures around the third ventricle is a great challenge for neurosurgeons. Radiotherapy, as a supplementary postoperative therapy to atypical meningioma excision, reduces the recurrence rate of the tumor (Louis *et al.* 2007).

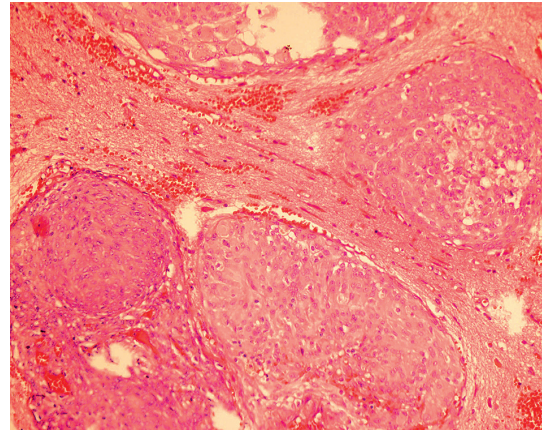


Fig. 2. HE staining, 40x. Invasive growth of meningioma tissue in the cerebral parenchyma was seen under a microscope

Regardless of the type of therapy, atypical meningiomas frequently recur; in particular, atypical meningiomas with precise evidence of invasion into cerebral tissues have high recurrence rates (Table 1). Long-term, close follow-up examinations must be performed to be able to treat recurrent lesions as soon as possible.

Conclusions

This article reports the first case of recurrent atypical meningioma in the third ventricle of a child. Tumor invasion into cerebral tissues signified a higher recurrence rate. Excision of the tumor under a microscope without injury to normal cerebral tissues is an essential requirement

Table 1. Reported cases of third ventricle meningioma

Authors and year	Patient age and sex	Surgical approach	Resection	Pathological diagnosis	Outcome
Strenger <i>et al.</i> (1987)	61 y, F	Transventricular	–	Grade III	Death
Pandya <i>et al.</i> (1990)	10 y, M	–	Total	Neurofibromatosis	Good
Huang <i>et al.</i> (1993)	6 y, M	–	Debulking	Atypical (grade II)	Good
Nakamura <i>et al.</i> (2003)	25 y, M	Transcallosal	Subtotal	Grade I and II	Death
Bhatoe <i>et al.</i> (2006)	–	Transcortical-transventricular	Total	Neurofibromatosis (grade I)	Good
Song <i>et al.</i> (2008)	12 y, M	Left frontal transcortical-transventricular	Total	Grade II	Good
Wajima <i>et al.</i> (2011)	63 y, M	Right frontal transcortical-transventricular	Total	Chordoid (grade II)	Good
Ødegaard <i>et al.</i> (2008)	–	Transcallosal	Total	Grade I and II	Good
Karki <i>et al.</i> (2014)	49 y, M	Transcortical-transventricular	Total	Atypical (grade II) → malignant (grade III)	Recurrence
Present case	12 y, M	Right frontal transcortical-transventricular	Total	Atypical (grade II)	Recurrence

for neurosurgeons. For such patients, long-term, close follow-up examinations must be conducted to monitor tumor recurrence.

References

1. Bhatoo HS, Singh P, Dutta V. Intraventricular meningiomas: a clinicopathological study and review. *Neurosurg Focus* 2006; 20: E9.
2. Buetow MP, Buetow PC, Smirniotopoulos JG. Typical, atypical, and misleading features in meningioma. *Radiographics* 1991; 11: 1087-1106.
3. Huang PP, Doyle WK, Abbott IR. Atypical meningioma of the third ventricle in a 6-year-old boy. *Neurosurgery* 1993; 33: 312-315.
4. Hug EB, Devries A, Thornton AF, et al. Management of atypical and malignant meningiomas: role of high-dose, 3D-conformal radiation therapy. *J Neurooncol* 2000; 48: 151-160.
5. Komotar RJ, Iorgulescu JB, Raper DM, et al. The role of radiotherapy following gross-total resection of atypical meningiomas. *J Neurosurg* 2012; 117: 679-686.
6. Louis DN, Ohgaki H, Wiestler OD, et al. The 2007 WHO classification of tumours of the central nervous system. *Acta Neuropathol* 2007; 114: 97-109.
7. Song KS, Park SH, Cho BK, et al. Third ventricular chordoid meningioma in a child. *J Neurosurg Pediatr* 2008; 2: 269-272.