

High-dose-rate pre-operative endorectal brachytherapy for patients with rectal cancer

Té Vuong, MD, FRCP¹, Slobodan Devic, PhD, FCCPM²

¹Department of Radiation Oncology, ²Department of Medical Physics, Jewish General Hospital, McGill University, Montreal, Québec, Canada

Abstract

High-dose-rate endorectal brachytherapy (HDREBT) is an image guided brachytherapy treatment for patients with rectal cancer. It is based on tumor imaging with magnetic resonance in particular, which is used to choose eligible patients and improve tumor visualization. Treatment planning is performed using 3D CT simulation and treatment planning. The treatment is given on an outpatient basis and requires minimal local anesthesia. The validation of the technique was carried out through a preoperative study and is now explored as part of a radical treatment for early rectal cancer or as a boost modality.

We describe technical aspects of the HDREBT and we discuss the ongoing institutional review board approved studies exploring the clinical applications of this treatment modality for patients with rectal cancer: 1) as a neoadjuvant treatment for patients with operable rectal tumor; 2) as a option to improve local control in patients with newly diagnosed rectal cancer but with previous pelvic radiation.

J Contemp Brachytherapy 2015; 7, 2: 183-188

DOI: 10.5114/jcb.2015.51402

Key words: brachytherapy, endorectal, image guidance, pre-operative, rectal cancer.

Purpose

Contact X-ray therapy for treatment of rectal cancer, introduced by Papillon [1] in the early 1970s, is highly effective and well tolerated for radical treatment of early stage rectal cancer [2,3] (T1, and favorable T2 lesions). On the other hand, HDREBT was mainly used in the past as a palliative treatment modality [4,5].

In our center, we developed a treatment protocol based on magnetic resonance tumor imaging, which we use to select eligible patients and also to improve tumor visualization for target outlining. Treatment planning is done using 3D CT simulation in conjunction with conformal treatment planning. We describe technical aspects of HDREBT and discuss the ongoing institutional review board (IRB) approved studies exploring the clinical applications of this treatment modality for patients with rectal cancer [6].

Material and methods

During 1998, we conducted a phase I/II study to evaluate the use of HDREBT as an alternative pre-operative down-staging modality to conventional external beam radiation therapy. Patients with T2-3 Nx tumors and no

evidence of necrotic or extramesorectal nodes larger than 1 cm were selected for participation in the study. Over the last 15 years techniques for imaging, treatment planning and dose delivery have evolved into the currently used HDREBT technique.

Pre-treatment imaging

Patients eligible for pre-operative endorectal HDRBT undergo endoscopic endorectal ultrasound (EUS) for tumor staging (transparietal extension) and magnetic resonance imaging (MRI) of the pelvis for tumor measurements (length and bulk evaluation). After completion of clinical and radiological evaluations under direct rectoscopy, radio-opaque clips are placed to mark the proximal and distal margins of the tumor for subsequent positioning, quality control of simulation, and treatment applications.

High-dose-rate endorectal brachytherapy equipment

The prescribed dose is delivered using a micro-Selectron remote after-loader (Elekta AB, Stockholm, Sweden) employing an iridium-192 source with a nominal activity at installation of 370 GBq (10 Ci). Daily radiographs with the patient in the treatment position and applicator in-

Address for correspondence: Dr. Te Vuong, MD, FRCP, Department of Radiation Oncology, Jewish General Hospital, McGill University, Montreal, Quebec, Canada, phone: +1 514-340-8288, fax: +1 514-340-7548, e-mail: te.vuong@mcgill.ca

Received: 23.03.2015

Accepted: 29.04.2015

Published: 30.04.2015

serted into the rectal lumen can be acquired using either a dedicated or portable X-ray unit.

During endoscopy on Day 1 (Fig. 1), several days following completion of clinical and radiological evaluations, four radio-opaque clips (QuickClip2, model: HX-201LR-135; Olympus, Southend-on-Sea, Essex, UK) are placed to mark the proximal and distal margins of the tumor (Fig. 2). The clips are of cylindrical shape with a length of 5 mm and a diameter of 1.5 mm. They are subsequently used for image guidance prior to daily treatments. We commonly use two clips to mark the proximal limit and two clips to mark the distal limit of the tumor volume, all clips inserted using direct rectoscopy. On occasion, more than four clips are inserted following the advice of the gastro-intestinal (GI) specialist. In our experience, some of the inserted clips get lost during the four-day course of treatment; however, usually at least one of the four clips remains inside the rectal lumen until the last treatment fraction. In our experience to date, all the complete set of clips was lost before the end of the course of treatment on only two occasions. Although we could have opted to carry out the based on bony anatomy, in both patients we inserted new clips and repeated the treatment planning for the remaining treatment fractions.

An intracavitary mould applicator (Elekta AB, Stockholm, Sweden) of cylindrical shape (27 cm long and 2 cm in diameter) is used in our study. As shown in Figure 3, eight catheter channels are distributed equally over the circumference of the applicator in equal angular increments, and a central lumen is also available for insertion of an additional central catheter. The applicator is made of a pliable silicon rubber material, which allows an easy insertion and navigation through the rectum and sigmoid colon. Figure 3 also indicates schematically the convention we are using with respect to the loading of the channels (from 1 to 8) as well as the catheters loaded

with uniquely coded x-ray markers (gray circles: 1, 3, 4, 5, and 7) that are used for ensuring the daily rotational reproducibility.

Prior to applicator insertion into the rectal lumen, an endocavity balloon (CIVCO, Latex-Free Endocavity Balloon, 610-898 (BS3000), USA) is placed over the rectal applicator. The endocavity balloon provides a snug fit to the mould applicator, and contains an adjustable inflation control of the balloon to provide proper fixation of the mould applicator within the rectal lumen. The balloon is oriented in such a way that its expanding section is placed opposite to the tumor location. Once the necessary longitudinal shift is determined and rotational position verified, the balloon is inflated by water injection. A small amount of CT iodine contrast can be added to help with the visualization on a CT scan.

The 3D treatment planning

Details of the treatment planning procedure have been described previously [6,7]. Prior to CT simulation, an initial antero-posterior (AP) scout view of the patient lying in supine position is performed in order to visualize the endorectal radio-opaque clips. The endorectal applicator is introduced using lubrication with the patient lying in the lateral decubitus position. The patient is then repositioned in the supine position, and a plate with the mounted hydraulic locking clamp is slid under the patient's pelvis and the Oncosmart intracavitary mould is latched onto the clamp (Elekta AB, Stockholm, Sweden). Repeated AP and lateral scout views are then taken and examined. When necessary, adjustments are made to the cephalic orientations of the applicator relative to the radio-opaque clip locations.

Following the CT simulation, the acquired images are sent to a dedicated virtual simulation image processing workstation. The tumor (GTV) and intramesorectal

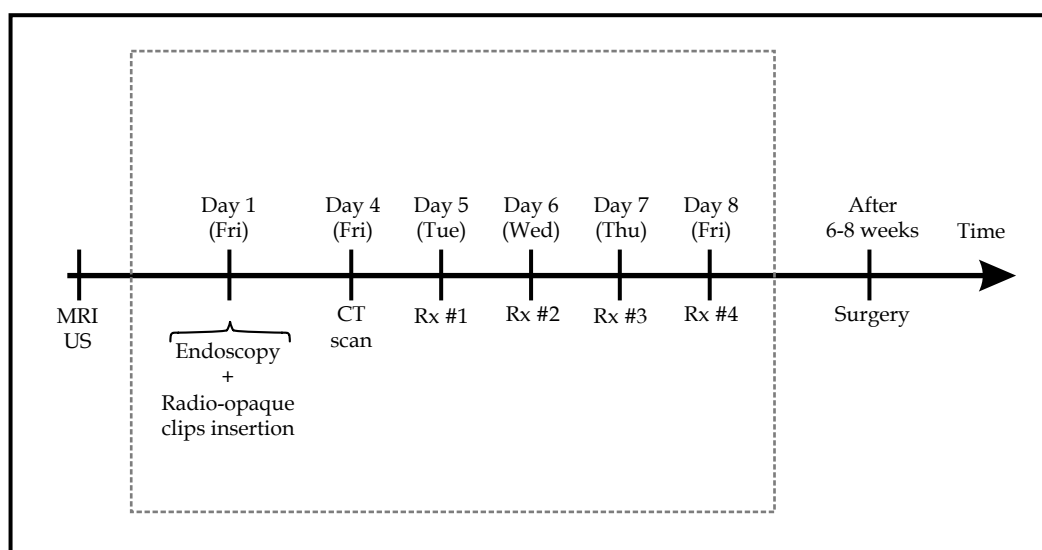


Fig. 1. Time scheme for preoperative endorectal high-dose-rate brachytherapy; the days of the week in parentheses represent the most suitable days not only from a logistical point of view but also for a reliable reproduction of the daily dose distribution

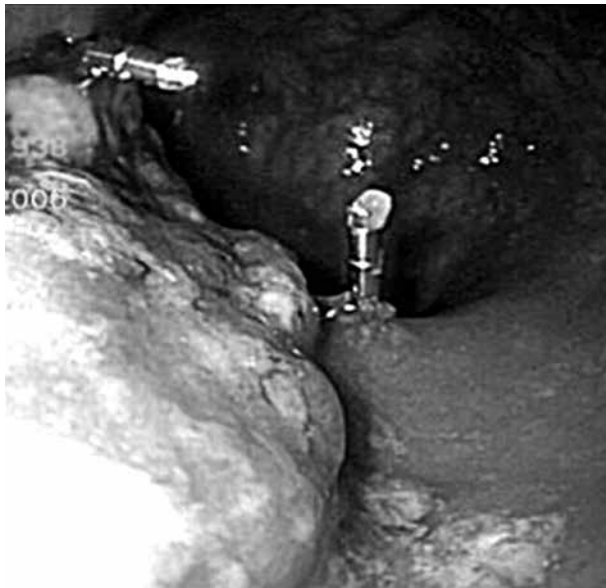


Fig. 2. Marking proximal and distal limit of a tumor using radiopaque clips under direct rectoscopy

extension including extra nodal and visible pararectal nodes (CTV), catheters and endorectal clips are contoured on a slice-by-slice basis. Contoured tumor, catheters, and endorectal clips are incorporated into digitally reconstructed radiographs (DRRs) or digitally composite radiographs (DCRs) to enhance selective visualization for use as reference for daily treatment.

The differential source positioning technique

Source positions and engaged channels for brachytherapy are determined with respect to the contoured tumor. Catheters are loaded in a differential manner, so that only those in direct contact with the tumor contain active source dwell positions. Following the source position determination, CT-aided brachytherapy treatment planning is carried out, so as to optimize fully the dose to the tumor, while limiting the dose to immediate adjacent tissues beyond the rectal wall. Isodose distributions are generated by commercially available treatment planning software (Elekta AB, Stockholm, Sweden).

A total dose of 26 Gy in 4 daily fractions of 6.5 Gy is prescribed at the CTV, defined as the GTV and intramesorectal deposits seen on the pre-staging MRI. Figure 4 represents an example of the dose distribution obtained during treatment planning optimization. The 100% isodose cloud (Fig. 4, bottom-left) completely covers the CTV. The plan is checked prior to treatment by inspecting the prescription dose to the CTV coverage on a slice-by-slice basis (Fig. 4, upper-left). Dose coverage can also be inspected within different planes (Fig. 4, upper-right). The bottom-right section of Figure 4 illustrates the difference between dose coverage to the CTV and sparing of the surrounding critical structures in terms of the corresponding dose-volume histograms.

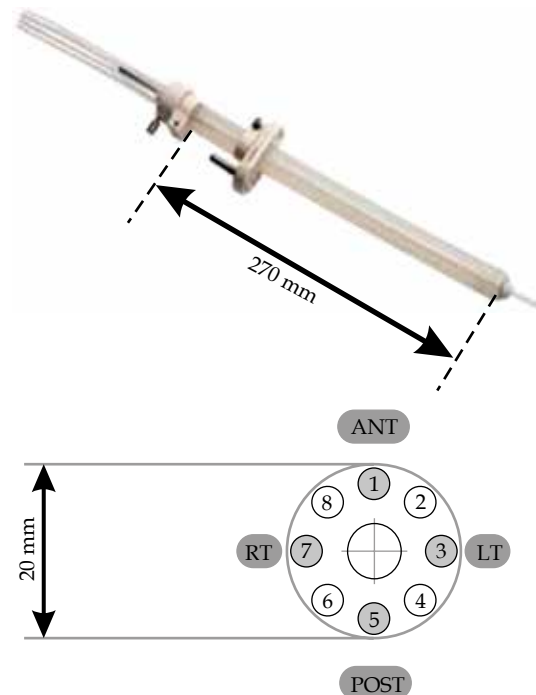


Fig. 3. Intracavitary mould applicator; the bottom schematics represents the catheter convention (1-8) as well as the catheters engaged with X-ray markers (1, 3, 4, 5, and 7; gray shaded circles)

Daily image guidance

Reproduction of the treatment planned dose distribution on a daily basis is crucial for the success of fractionated 3D based brachytherapy treatments [8,9]. Due to the cylindrical symmetry of the applicator used for preoperative HDR-EBT, two types of adjustments are necessary: applicator rotation and dwell positions shift along the applicator's longitudinal axis.

Since the applicator might not be placed before each treatment fraction inside the rectal lumen in the same manner as it was placed during the 3D CT volume acquisition used for treatment planning, there is a shift along the catheter axis that may have to be performed. The required shift is determined by comparison of a daily radiograph with the treatment planning digitally-reconstructed radiograph (DRR, see Fig. 5).

Outlining of the catheter is a crucial step in the treatment planning process to assure proper rotational reproducibility of the planned dose distribution on a daily basis. During the outlining procedure, catheters are assumed to follow their "ideal" positions, equally spaced by 45° and starting with the catheter number one at the "12 o'clock" position. We do not follow the actual catheter positions seen on the planning CT slice, since for daily treatments we will be able to reproduce only the ideal angular positions of the catheters. Once the longitudinal shift has been determined, the applicator is rotated and subsequently re-imaged using the fluoro mode (low mAs), until an acceptable alignment is achieved. The final acceptable radiograph that confirms the proper rotational

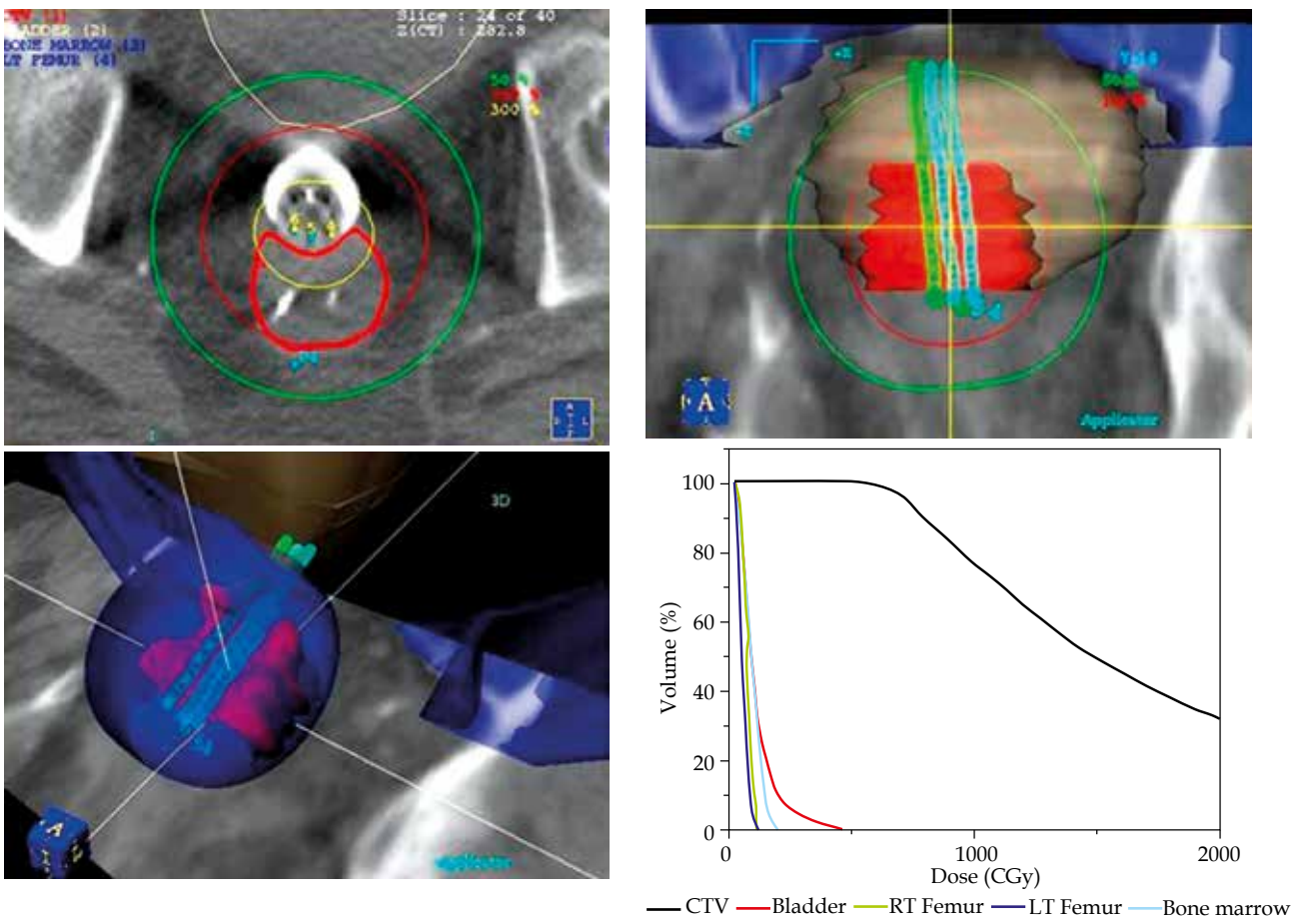


Fig. 4. Dose distribution obtained by treatment planning system

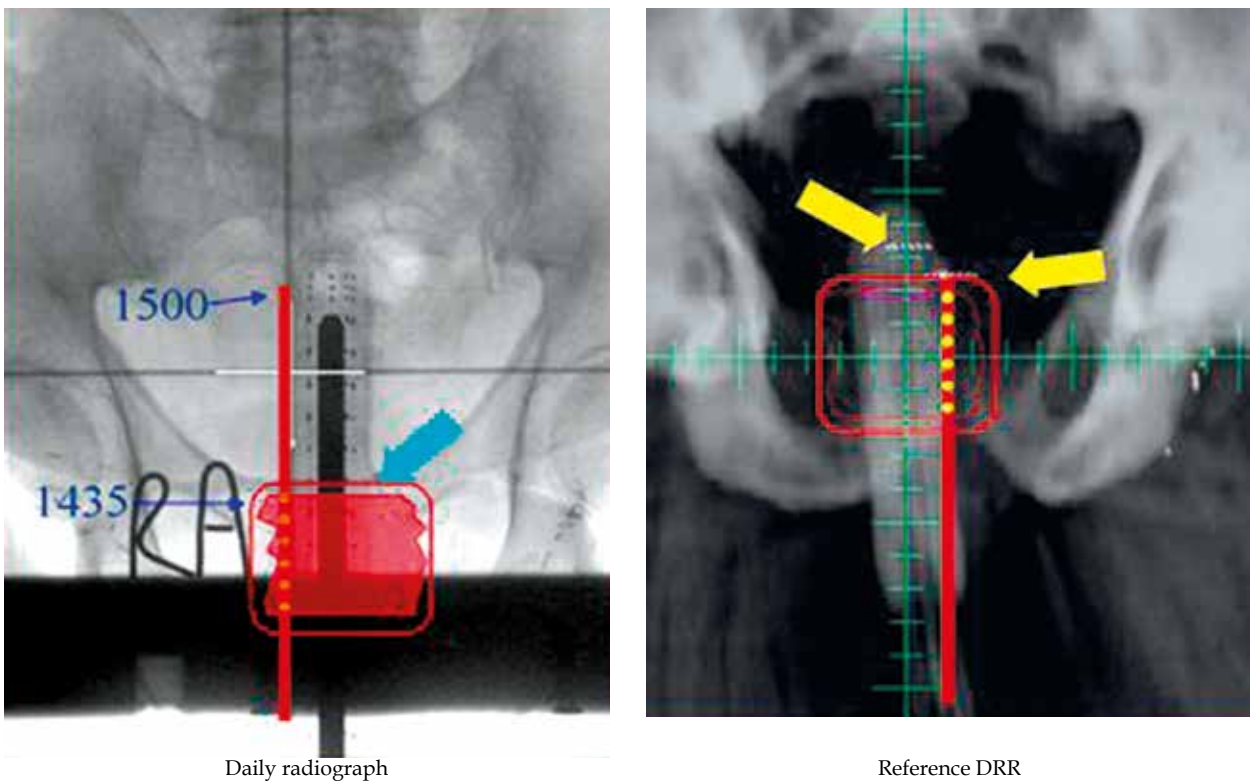


Fig. 5. Daily longitudinal treatment adjustment

position is shown in Figure 6B. To achieve the "ideal" rotational position, shown in Figure 6B, the applicator was rotated counter-clockwise.

During the last decade, HDREBT has evolved from an image-guided treatment to the adaptive brachytherapy treatment based on daily imaging.

When established, the patients were undergoing planning CT-simulation with the applicator in situ followed by treatment planning and then 4 consecutive days of treatment delivery. Prior to each treatment fraction, a daily radiograph was compared to the planning DRR and when necessary, changes would be made in the delivery plan in order to assure the dose is delivered as intended, a technique termed as an image guided brachytherapy technique. With the acquisition of the CT-simulator within our brachytherapy suite, we moved from daily image guided to a more advanced daily adaptive brachytherapy technique. After applicator insertion, the CT-data are acquired every day, target and planning structures are outlined right after the scan, and a plan is created and approved within 10-15 minutes post CT-simulation. Adaptive plans are delivered on a daily basis.

Clinical applications of high-dose-rate endorectal brachytherapy

Neoadjuvant treatment for patients with operable rectal cancer

Between October 1998 and July 2013, 483 patients referred for pre-operative radiation were elected for HDREBT. The median age was 68.2 years (range 28-90). Based on preoperative endorectal ultrasound and MRI, patients with T3 and low T2 with positive circumferential radial margin were included. Patients with sub-occlusive tumors, not amenable to a full colonoscopy or suspected involvement of extramesorectal nodes and large T4 tumors were excluded.

Treatment

High-dose-rate endorectal brachytherapy was prescribed to the gross tumor volume and intramesorectal deposits seen on MRI. A total prescription dose of 26 Gy was given over four daily treatments (6.5 Gy per day) on an outpatient basis, using the remote after loading delivery system. TME surgery was performed six to eight weeks after completion of treatment. Until 2005, patients with positive nodes received postoperative EBRT with 45 Gy in 25 fractions and 5-FU chemotherapy at 225 mg/m² by continuous infusion during irradiation. Subsequent 5-FU adjuvant chemotherapy was at the discretion of the medical oncologist. After 2005, FOLFOX chemotherapy alone was given by extrapolation of the colon data.

Results

A total of 483 patients received neoadjuvant HDREBT alone and 43 patients received postoperative external beam radiation therapy, and 5-FU chemotherapy for positive nodes (period 1989-2005). The complete sterilization rate was 27% and the rate of positive nodes was 30.7%.

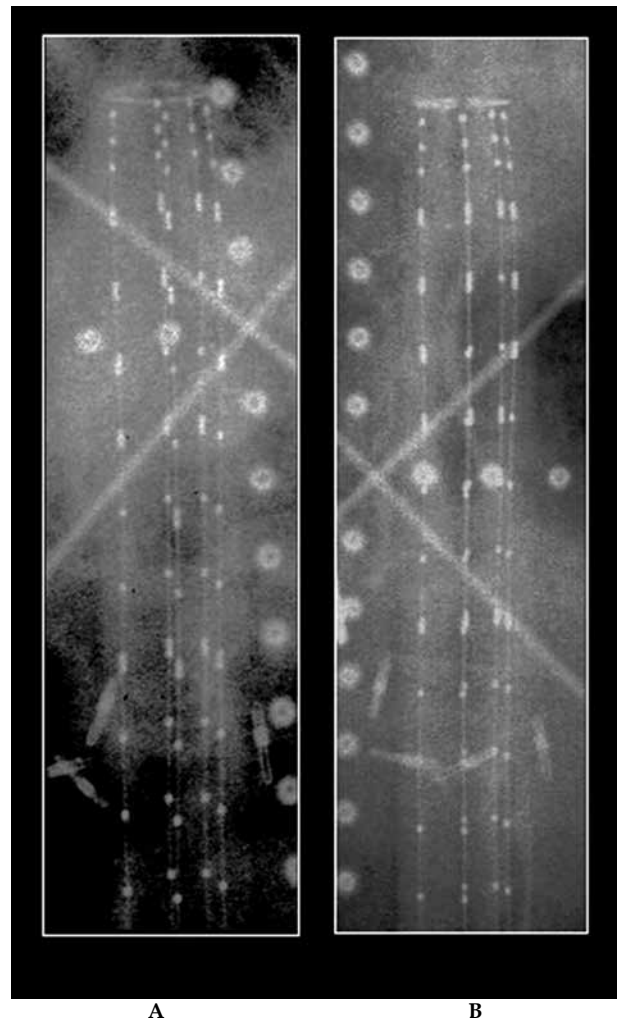


Fig. 6. Rotational alignment of the applicator: **A)** initial position; **B)** final position after appropriate applicator rotation

The median follow-up time was 63 months, the actuarial local recurrence rate was 4.8%, the disease-free survival was 65.5%, and the overall survival rate was 72.8%. Local recurrence was defined as tumor bed recurrence or pelvic nodal recurrence any time during the follow-up period, either as the first event or after the development of systemic metastases. There was no difference in local control between the two treatment strategies. The contribution of pelvic node relapse in local failure is relatively small compared to that of the tumor bed, and contrasts with its high incidence from surgical specimens.

Figure 7 illustrates the sagittal plane dose distribution using the endorectal brachytherapy treatment technique.

Conclusions

The results of our series suggest that limited targeted radiation with HDREBT to the tumor bed as well as the immediate perirectal nodal deposits, based on modern imaging (MRI) allows for excellent local control and limited toxicities on the surrounding tissues in a selected

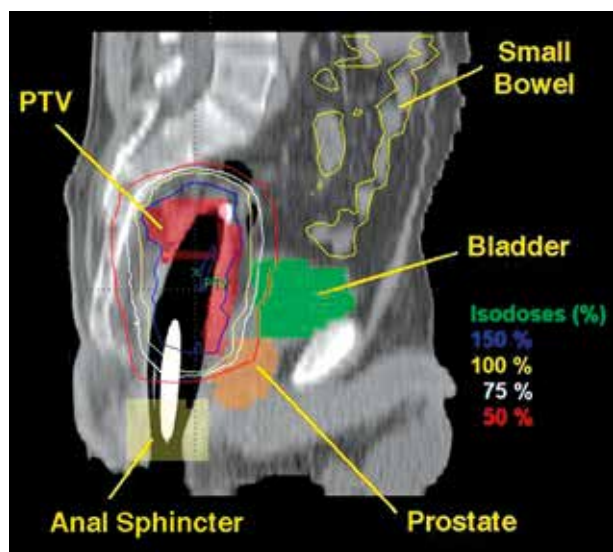


Fig. 7. Sagittal plane dose distribution using the endorectal brachytherapy treatment technique

but common group of patients [10]. Our pattern of pelvis failure supports the concept of a low nodal contribution in local relapse, and opens the debate on present clinical target volumes used in EBRT portals for all patients with rectal cancer and its implications on toxicity related risks. At this point, the Correct trial phase III study, lead by the John Hopkins team is on going and compares external beam radiation to HDREBT, and will provide an answer to this very pertinent question.

High-dose-rate endorectal brachytherapy is a highly conformal 3D image guided brachytherapy technique. This highly targeted radiation modality allows treatment of a selected but common group of rectal cancers. In our experience, it has been a useful neoadjuvant modality for rectal cancer and we are presently testing it as a boost modality in the context of radical radiation for elderly patients with either early tumors or inoperable patients with co-morbidity. It is a physician friendly technology. Although the potential clinical applications are numerous, they should be tested within clinical protocols.

Disclosure

Authors report no conflict of interest.

References

1. Papillon J. Endocavitary irradiation in the curative treatment of early rectal cancers. *Dis Colon Rectum* 1974; 17: 172-180.
2. Gerard JP, Romestaing P, Ardiet JM et al. Sphincter preservation in rectal cancer. Endocavitary radiation therapy. *Semin Radiat Oncol* 1998; 8: 13-23.
3. Ishikawa H, Fujii H, Koyama F et al. Long-term results of high-dose extracorporeal and endocavitary radiation therapy followed by abdominoperineal resection for distal rectal cancer. *Surg Today* 2004; 34: 510-517.
4. Evans MD, Podgorsak EB. Rectal and oesophageal treatment by the Selectron High Dose Rate afterloader. *Med Dosim* 1988; 13: 79-81.
5. Kaufman N, Nori D, Shank B et al. Remote afterloading intraluminal brachytherapy in the treatment of rectal, rectosigmoid, and anal cancer: a feasibility study. *Int J Radiat Oncol Biol Phys* 1989; 17: 663-668.
6. Vuong T, Belliveau P, Michel R et al. Conformal preoperative endorectal brachytherapy treatment for locally advanced rectal cancer. *Dis Colon Rectum* 2002; 45: 1486-1495.
7. Vuong T, Devic S, Moftah B et al. High dose rate endorectal brachytherapy in the treatment of locally advanced rectal carcinoma: Technical aspects. *Brachytherapy* 2005; 4: 230-235.
8. Devic S, Vuong T, Moftah B et al. Image guided high dose rate endorectal brachytherapy. *Med Phys* 2007; 34: 4451-4458.
9. Devic S, Vuong T, Evans M et al. Endorectal high dose rate brachytherapy quality assurance. *J Oncol* 2008; 58: 53e-54e.
10. Vuong T, Richard C, Niazi T et al. High dose rate endorectal brachytherapy for patients with curable rectal cancer. *Semin Colon Rectal Cancer Surg* 2010; 21: 115-119.