

# Robotic radical abdominal trachelectomy in early-stage cervical cancer: safe removal of the cervix with underpressure colpotomizer – review report based on case study

## *Robotyczna radykalna przezbrzuszną trachelektomia we wczesnym stopniu zaawansowania raka szyjki macicy przy użyciu podciśnieniowego manipulatora dopochwowego – praca przeglądowa na podstawie przypadku*

Magdalena Bizoń<sup>1,2</sup> , Maciej Olszewski<sup>1,2</sup>, Robert Balawender<sup>1</sup>, Krzysztof Mawlichanów<sup>1,3</sup>, Radovan Pilka<sup>1,4</sup>

<sup>1</sup>NEO HOSPITAL, Krakow, Poland

<sup>2</sup>LUX MED Onkologia, Oncologic Hospital, Warsaw, Poland

<sup>3</sup>Andrzej Frycz Modrzewski Kraków University, Krakow, Poland

<sup>4</sup>Department of Obstetrics and Gynaecology, Faculty Hospital Olomouc, Palacky University Olomouc, Olomouc, Czech Republic

Medical Studies/Studia Medyczne 2023; 39 (2): 206–214

DOI: <https://doi.org/10.5114/ms.2023.129049>

**Key words:** trachelectomy, cervical cancer, robotic surgery.

**Słowa kluczowe:** trachelektomia, rak szyjki macicy, chirurgia robotyczna.

### Abstract

Fertility preservation is a procedure of conservative surgery which may be performed in the early stage of cervical cancer as radical trachelectomy. The aim of the study is to describe the first robotic radical trachelectomy in Poland with safe cervical sample extraction using an underpressure manipulator. Robotic abdominal trachelectomy was performed in a 42-year-old nullipara with squamous cell cervical carcinoma G2 using an underpressure manipulator. No complications were observed. Mobilization of the patient began the day after the surgical procedure. The long-term obstetric and oncologic outcome of this technique would be expected to match the outcome of the other radical trachelectomy techniques in the published literature. Using of an underpressure manipulator decreases the risk of cervical tumour spread during the surgery. To our knowledge, this is the first description of safe radical trachelectomy specimen extraction using an underpressure colpotomizer.

### Streszczenie

Leczenie oszczędzające płodność może być rozważane w przypadku wczesnych stopni zaawansowania raka szyjki macicy jako radykalna trachelektomia. Celem pracy był opis pierwszej przeprowadzonej w Polsce radykalnej trachelektomii w asyście robota z użyciem podciśnieniowego manipulatora. Radykalną robotyczną trachelektomię z użyciem podciśnieniowego manipulatora przeprowadzono u 42-letniej nieródki z rozpoznaniem płaskonabłonkowego raka szyjki macicy G2. Okres około- i pooperacyjny przebiegał bez powikłań. Pacjentka została uruchomiona następnego dnia po operacji. W piśmiennictwie opisywane są długoterminowe korzystne wyniki położnicze i onkologiczne u pacjentek po przebytej radykalnej trachelektomii. Użycie podciśnieniowego manipulatora zmniejsza ryzyko rozprzestrzeniania się komórek guza w trakcie operacji. To pierwszy taki opis radykalnej robotycznej trachelektomii z użyciem podciśnieniowego manipulatora.

### Introduction

The morbidity of cervical cancer was globally estimated in 2018 at 570,000 cases, and mortality at 311,000 deaths [1]. Higher morbidity and mortality are observed in less developed countries, where screening methods are not used. Detection in late stages is reported in Sub-Saharan Africa and Southeast Asia [2].

Cervical cancer was placed 20<sup>th</sup> among malignant cancers in the United States in 2019. From 1975 to 2019 the morbidity of cervical cancer decreased by 57% [3].

Cervical cancer is placed seventh in terms of morbidity in Poland, and eighth in mortality. From 1999 to 2018 the number of morbidities decreased from 3565 to 2360 per year. Moreover, mortality also decreased from 1859 to 1593 per year [4].

However, the statistics for young women are different. In reproductive-age women cervical cancer is in second place for mortality from cancer [5]. In Poland cervical cancer is in 3<sup>rd</sup> place for morbidity from neoplastic disease up to 44 years old and 2<sup>nd</sup> place for mortality in the same age range [4].

Medical Studies/Studia Medyczne 2023; 39/2

Morbidity of cervical cancer in Poland in 2018 stood at 423 cases. On the other hand, there were 120 registered deaths in reproductive age [4].

Human papillomavirus (HPV) infection is one of the most frequent risk factors of cervical cancer. Morbidity of this cancer can also be increased because of parity, especially multiparity and smoking. Women with many sexual partners and those who started sexual intercourse at an early age are more predisposed to cervical cancer. The screening program is based on cytology and colposcopy [6].

There are some factors with a preventative influence, including condom use, limitation of sexual partners, and reduction in cigarette smoking. The preventive procedure against HPV infection is vaccination [7]. The screening program for HPV vaccination has already been started in Poland.

Cervical cancer is diagnosed after biopsy of the cervix. The next step is resonance imaging to visualize infiltration of the cancer. In the FIGO classification of 2018, stages IB1 to IIA are indications for surgical treatment. Unfortunately, radical surgery excludes reproductive plans.

In 1987 a novel surgical technique for the early stage of cervical cancer was conducted in women of reproductive age by the French surgeon Daniel Dargent. He introduced vaginal radical trachelectomy with fertility-sparing surgery (FSS) for women with a strong desire of maternity [8].

In 1994 cases of vaginal radical trachelectomy with laparoscopic pelvic lymphadenectomy indicated for young women with early-stage cervical cancer were described [9].

In 2005 Cibula *et al.* presented laparoscopic abdominal radical trachelectomy [10].

Three years later, in 2008 Persson performed robotic radical trachelectomy for fertility sparing in 2 cases of nulliparous women with stage IB1 of adenocarcinoma type of cervical cancer [11].

According to ESGO guidelines, fertility-sparing surgery can be considered in the early stages of cervical cancer IA1-IB1 to FIGO classification 2018. In stage IB1 radical trachelectomy can be considered as a fertility-sparing surgery [12].

The aim of the study is to describe the first robotic radical trachelectomy with bilateral biopsy of sentinel lymph nodes performed in Poland. Moreover, to our knowledge this is the first description of safe radical trachelectomy specimen extraction using an underpressure colpotomizer.

The first robotic trachelectomy was performed in NEO HOSPITAL in Cracow, Poland, using the DaVinci X System.

A 42-year-old nullipara with regular menses diagnosed with squamous cell cervical carcinoma G2 was admitted to NEO HOSPITAL in Cracow. In the histology after a cervical biopsy no lymphovascular space

invasion was detected. No metastatic disease was detected in an magnetic resonance imaging (MRI) scan. Maximal diameter of the cervical tumour in the MRI scan was 16.0 mm. There was no infiltration to parametria presented in the MRI scan. The patient was qualified as IB1 stage according to FIGO classification. No chronic diseases and no operations were reported. BMI was 21.05 kg/m<sup>2</sup> (weight: 58 kg, height: 166 cm). The patient is single with higher education. Due to her intention of pregnancy and meeting the criteria, the patient was qualified for laparoscopic trachelectomy assisted by da Vinci robot with bilateral biopsy of sentinel lymph nodes. Surgeon has 12 years' experience in robotic surgery.

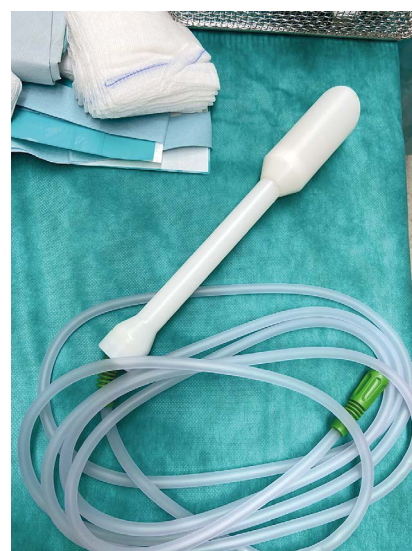Before the operation the patient was extensively counselled as to the risks, benefits, and options.

After surgery and follow-up visit, the VAS scale was used, where 0 means no pain, and 10 means the maximal level of symptoms. The Clavien-Dindo classification describing perioperative and postoperative complications was used during hospitalization.

Quality of life was assessed using EQRTC QLQ-C30 and EORTC QLQ-CX24 questionnaires.

The operation was performed on 17 July 2021 with a 4-arm da Vinci X robot.

After introduction of general anaesthesia and a Foley catheter inserted into the bladder, 0.25 ml of a 2.5 mg/ml ICG solution was injected submucosally peritumourally at 3 and 9 o'clock, respectively, with a 23G × 1½" needle, achieving a total dose of 2.5 mg ICG. Then a vacuum colpotomizer called a MyTube was inserted in the vagina without any compromise of the cervix (Figure 1).



**Figure 1.** MyTube – underpressure colpotomizer. The top of the colpotomizer is put through the vagina to the cervix. In the centre of the top there is a hole where the cervix is situated. There is no damage of the cervix, so no possibility of spread of carcinomatous cells

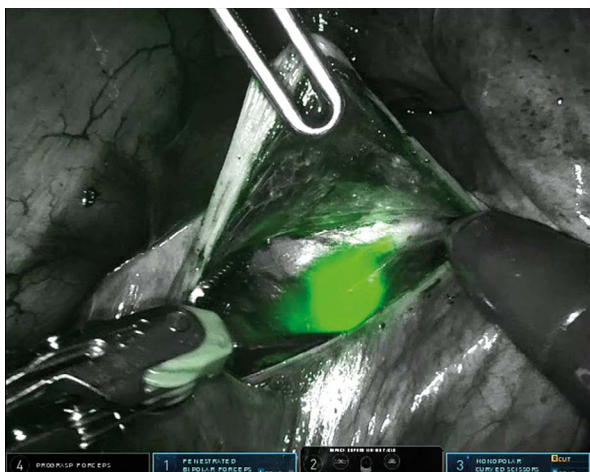

Figure 2. Sentinel lymph node (real-time ICG)

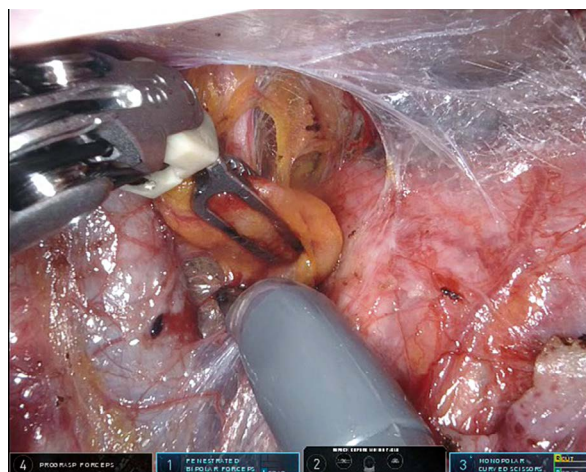


Figure 3. Sentinel lymph node in normal view

The patient was placed in the dorsolithotomy position, and a Veress needle was introduced to insufflate the peritoneal cavity with carbon dioxide to a pressure of 15 mm Hg. After the insertion of the trocar, the whole intra-abdominal cavity was explored with a laparoscope. Then all 5 ports were placed through the abdominal wall: 4 ports for 8 mm and a 12-mm port in the right lower quadrant for the surgical assistant.

The biopsies of sentinel lymph nodes were done with negative frozen section results bilaterally after preparation of the paravesical and pararectal spaces (Figures 2, 3). After being found negative for metastases on frozen section, a standard compartmental pelvic lymphadenectomy was performed. Sparing the infundibulopelvic and round ligaments, the bladder was dissected in the midline and the uterine arteries were isolated at their lateral origins. The posterior blades of the broad ligaments were divided to the sacrouterine ligaments following to the ureters, which were dissected and visualized also at the ventral and distal side of the uterine arteries. This enabled a safe dis-

section of the upper parametria preserving the main uterine arteries and an identification of their descending branches. The ureters were retracted laterally to dissect and divide the anterior ligament, the lower parametrium, and the paracolpium. The lateral parts of the sacrouterine ligaments were retracted laterally together with identified fibres of the iliohypogastric nerves before the medial part of the sacrouterine ligaments were divided at the appropriate length.

Because of fertility-sparing surgery, bilaterally ovaries, tubes, and adnexal vessels were spared. The cervix and paracervical tissue were amputated and removed using the MyTube colpotomizer with underpressure, and a frozen section revealed negative margins. A prophylactic cerclage with Prolene was placed beneath the level of internal uterine opening to prevent cervical incompetence (Figure 4). The uterus was reanastomosed to the vagina by using continuous suture by V-lock (Figure 5). At the end of the operation, a Redon drain was placed. Total blood loss was 40 ml.

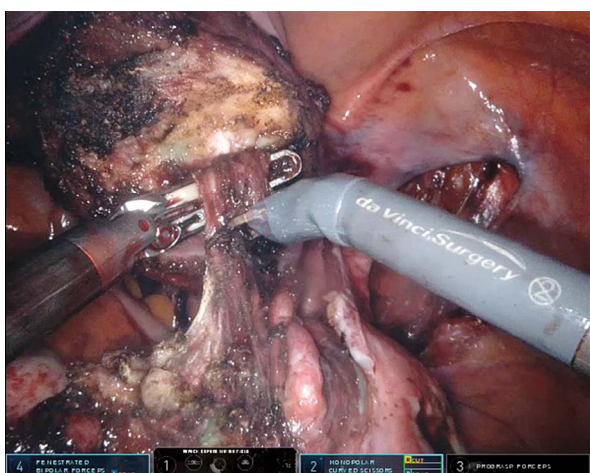


Figure 4. Amputation of cervix and paracervical tissue

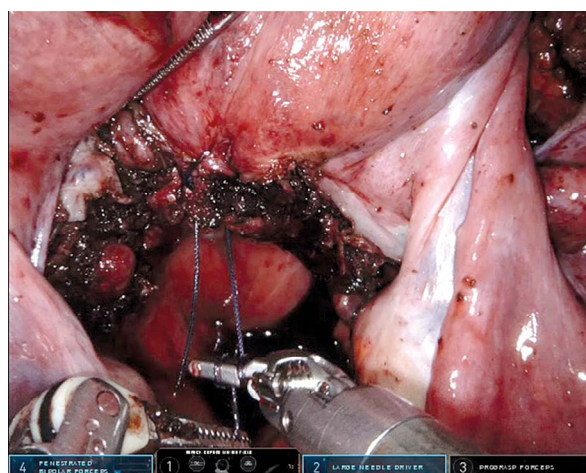


Figure 5. Reanastomosis of the uterus to the vagina

The operation time was 285 min. The patient was hospitalized for 5 days. No complications were observed. Mobilization of the patient began the day after the surgical procedure.

Before the operation the patient declared the robotic technique as the best method of surgical treatment by giving it the maximal number of points in the questionnaire. The subjective benefits that affected this opinion were precision of movement of the robot, cosmetic effects, less blood loss, and shorter hospitalization.

The patient felt no pain before the surgery. Everyday a VAS scale was used for subjective assessment of pain. In the evening on the day of the operation, pain was at level 5 in the patient’s opinion. The following day, pain was estimated on the scale as 3. Two weeks after the operation, she indicated 2 on the VAS scale. At the follow-up visit after 6 weeks there was no complaint of pain.

Clavien-Dindo classification 5 days after the operation was zero points, and in follow-up visits after 2 and 6 weeks, also zero points were measured.

The patient completed EQRTC QLQ-C30 questionnaire before the radical trachelectomy and scored 43 points before surgery. Two weeks after the surgical procedure the number of points was 72. Quality of life using the same instrument after 6 weeks after operation was assessed by the patient as 52 points.

Another questionnaire used during the study was EQRTC QLQ-CX24. Before the onset of treatment the patient received 36 points, 2 weeks after the operation the number of points increased to 45, and then it decreased to 32 points.

Histological results of the cervix after radical robotic trachelectomy revealed ulcerate squamous cell cervical cancer G2 with a depth of infiltration of 18 mm, LVSI negative. The surgical limits of the vaginal area of the cervix were free of carcinomatous foci. Parametria of both sides showed no infiltration. Tissue of the vagina located close to the uterus had no cancer cells. No metastases were observed in lymph nodes (Table 1). There was no need for adjuvant treatment.

Currently the patient is still under control in an outpatient gynaecological oncology clinic. There have been no indications for complementary methods of treatment. The patient’s quality of life has not changed since the surgical treatment. No progression of cervical cancer has been observed. Nine months after the operation, she has not decided about pregnancy.

Radical trachelectomy can be performed in patients with cervical cancer diagnosed in an early stage (IA–IB1 in FIGO classification), with cervical tumour less than 2 cm in diameter, who are in reproductive age, and plan to become pregnant. It is a very rare procedure in Poland.

**Table 1.** Histological results of lymph nodes

Type of lymph nodes	Number of lymph nodes	Result
Iliac internal right	1	No metastases
Iliac external right	6	No metastases
Obturatorial right	5	No metastases
Parametrial right	2	No metastases
Iliac internal left	4	No metastases
Iliac external left	6	No metastases
Obturatorial left	9	No metastases
Type of tissue	Result	
Left parametria	No infiltration	
Right parametria	No infiltration	
Tissue of vagina located close to the uterus	No infiltration	

Matsuo *et al.* published a national study in 2020, which revealed a nearly 3-fold increase in the number of fertility-sparing trachelectomies in the USA, but only 25% of centres have adequate qualifications. Hospital surgical volume of trachelectomy was a predictor of fewer perioperative complications and short-term hospitalization. These procedures should be performed in the top centres [13]. Radical trachelectomy, in comparison to radical hysterectomy, performed in early-stage cervical cancer allows for fewer intraoperative and postoperative complications, less blood loss, and shorter hospitalization [14].

There are different techniques of radical trachelectomy.

In 2011 a retrospective investigation was published with an analysis of 14 patients who underwent vaginal trachelectomy with laparoscopic lymphadenectomy between 2003 and 2011. There was no distant metastasis in their lymph nodes. Blood loss was from 60 to 335 ml, mean 120 ml. Mean duration of the surgical procedure was 185 min (170–225 min). The number of removed lymph nodes was 11–23 (mean 15). Three cases were complicated with bleeding from the parametrial vein 6 h after surgery, vaginovesical fistula after 6 days, and haemorrhage because of infection 21 days after the operation [15].

Saadi *et al.* described 4 patients who underwent laparoscopic radical trachelectomy with a mean age of 26 years and mean BMI of 21. Maximum tumour size was 31 mm, with a mean of 17 mm. Duration of surgery was 210–240 min (mean 225 min). No complications were reported. Parametria were free in all cases. On average 18 lymph nodes per surgical procedure were removed. No conversion to laparotomy was made. No complementary treatment was indicated after surgery [16].

Plante *et al.* presented research of alternative treatment of cervical cancer with low risk and tumour size less than 2 cm. Seventy-five percent of patients recruited to the investigation were nulliparous, with mean age of 30 years. All analysed women underwent laparoscopic biopsy of the sentinel node with subsequent simple vaginal trachelectomy. In all cases lymph nodes were negative. There were 2 cases reported as complications. The first was a haematoma located in the trocar site, and the second was a vaginal laceration. The recurrence-free survival at 24 months was 100% [17].

Vieira *et al.* compared radical trachelectomy performed in laparotomy and laparoscopically. The analysed population consisted of 100 women, 58 of whom were operated on by open radical trachelectomy and 42 with minimally invasive surgery. In overall survival, there was one case of recurrence of a patient after laparotomy and none after laparoscopy [18].

Comparison of laparoscopic radical trachelectomy and abdominal radical trachelectomy showed less blood loss and shorter time of hospitalization using the former technique of surgery [19].

The first robotic radical trachelectomies performed by Persson *et al.* lasted 387 and 358 min. Indications were nulliparous with adenocarcinoma of the cervix, stage IB1 [11]. In 2008 Geisler *et al.* conducted another robotic trachelectomy because of adenocarcinoma of the cervix, stage Ib1. Surgery lasted 172 min with blood loss of 100 ml [20]. Radical trachelectomy performed for the first time in Poland lasted 285 min and had 40 ml of total blood loss.

Persson *et al.* compared results after robotic radical trachelectomy and vaginal radical trachelectomy. The remaining cervical length and possibility of placement of the cerclage after the operation were the same after both techniques [21].

The problem of conservative surgery is parametrectomy. Baiocchi *et al.* analysed 345 patients with cervical cancer in stage Ia2 to Ib2 after radical surgery. Histological results revealed that in cases of lack of lymphovascular space invasion and tumour size less than 2 cm parametrial invasion is unlikely. On the other hand, lymph node metastasis and deep stromal invasion may correlate with parametrial invasion [22].

The first concept of fertility-sparing surgery for cervical cancer was suggested by Aburel in 1932 [23].

In every case of early-stage cervical cancer in young age, a conversation about fertility should take place. Fifty percent of women feel under control about oncofertility and cannot speak about this problem [24]. Fertility preservation is a procedure of conservative surgery to allow a patient to become pregnant in the future. It is reserved for women with early-stage cervical cancer and low-grade early-stage endometrial cancer where hormonal therapy is an option of treatment. In ovarian cancer, conservative surgery can only be performed in stage I epithelial type [25].

There are many studies focused on long-term observations in a number of pregnancies after radical trachelectomy. Lu *et al.* in 2014 reported 140 cases of total laparoscopic radical trachelectomy. The recurrence rate was 2.9%. From the whole group, 59 patients tried to become pregnant, but only 11 had term deliveries, while there were 14 preterm labours and 17 miscarriages [26].

Shah *et al.* were among the first to describe reproductive effects after conservative surgery of cervical cancer. They reported a pregnancy rate of 54% after radical trachelectomy because of early-stage cervical cancer. From this group, 70% of pregnancies finished successfully [27]. Rob *et al.* reported fertility-sparing surgery in a population of 90% nulliparities. The percentage of pregnancies after the treatment was 7–38% including premature and mature deliveries [28].

Benefits from pregnancies after fertility-sparing surgery were screening and treatment of asymptomatic bacteriuria and cervical incompetence screening. Progression of cervical shortening in transvaginal ultrasound is observed during pregnancy. Cerclage can be a solution for prevention of preterm birth or late abortion [29].

Breban-Kehl *et al.* conducted a retrospective study of 75 patients after fertility preservation in cases of cervical cancer from 1995 to 2020. The recurrence rate was 4.8%, and one death was confirmed. Thirty-one pregnancies were registered, 74% with spontaneous onset. Circa 60% of patients delivered at term [30].

Ramirez *et al.* reported a 43% pregnancy rate after radical abdominal trachelectomy, but only 75% finished successfully [31].

On the other hand, it was observed that after laser conization and after vaginal trachelectomy preterm rupture of the membrane may occur [32]. Basta *et al.* observed a 76.5% pregnancy rate in patients after conization, and 90% lasted until term. Fifty per cent of patients after vaginal radical trachelectomy with laparoscopic lymphadenectomy became pregnant, but only 50% finished at term, 33% delivered preterm, and 16.7% experienced miscarriages [33].

Muraji *et al.* analysed levels of anti-Müllerian hormone (AMH) after abdominal radical trachelectomy with pelvic lymphadenectomy and abdominal radical hysterectomy. Serum levels of this hormone were higher in the first group than in the second one. The data indicated that abdominal radical trachelectomy does not influence the functions of the ovaries. Ovarian reserve was not evaluated. Moreover, in one case after radical trachelectomy the AMH level decreased, which correlated with pelvic lymphocyst infection [34].

Minimally invasive surgery has many benefits for patients. Quality of life after minimally invasive radical trachelectomy was assessed by special questionnaires. Twenty-three patients with mean age

of 30 years who underwent operations between 2002 and 2011 answered questions about physical, psychological, reproductive, and sexual functions. All women had regular menstrual periods after surgery. Cervical stenosis was diagnosed in one patient. Sixty percent of the analysed group became pregnant spontaneously. Sexual dysfunction was observed briefly after the operation. One (4.4%) patient complained of problems with lubrication, while 3 (13%) women were afraid of intercourse. Dyspareunia was observed in 6 patients (26.1%) but resolved after 3 months. All women declared full psychological and physical recovery [35].

In 2015 Chan *et al.* reported a study of 470 survivors of localized cervical and ovarian cancer. All analysed patients answered questionnaires about sexual satisfaction and sexual quality of life. From the group of cervical cancer survivors, 92 had undergone fertility-sparing surgery (FSS) (conization or trachelectomy) and 84 had undergone radical hysterectomy. There were no significant differences in sexual satisfaction. Apart from the possibility of posttreatment fertility in the FSS group, the benefits in terms of sexual quality of life were the same in both groups [36].

Kampers *et al.* in their metanalysis concluded that DFS and OS in the minimally invasive approach of early-stage cervical cancer appear to depend on the surgical technique. Protective operating techniques in the minimally invasive approach result in improved survival. Based on the results of this metanalysis, we decided to use an underpressure colpotomizer to avoid spread cancer cells during the surgical procedure [37].

In 2018 Ramirez *et al.* published results of a prospective LACC study comparing methods of surgical treatment of early-stage cervical cancer. Minimally invasive surgery (84.4% of patients underwent laparoscopy and 15.6% underwent robot-assisted surgery) was associated with a lower rate of disease-free survival and overall survival than open surgery. The hazard ratio for disease recurrence and death from cervical cancer was also higher in patients after minimally invasive surgery. Inclusion criteria were cervical cancer in IA1 to IB1 according to FIGO classification 2009, where the maximum diameter of the tumour was 4.0 cm. In this study typical uterine manipulator was used, which is different from our underpressure colpotomizer. The procedures performed in the trial included only radical hysterectomy; they do not perform radical trachelectomy. They recruited patients with cervical tumour size up to 4.0 cm and qualified for radical hysterectomy. The case of the patient we have described is focused on cervical cancer with a 16.0 mm tumour, and because of her desire for maternity a sparing procedure was done [38].

In 2021 Schmeler *et al.* published a prospective trial of conservative surgery for low-risk, early-stage cervi-

cal cancer (ConCerv). Inclusion criteria included cervical cancer in stage IA2-IB1. The study was conducted from April 2010 to January 2019 in 14 institutions from 9 countries. Cervical conization followed by lymph node assessment was conducted in 44% of patients who desired fertility preservation. Forty women (40%) with no desire of fertility underwent cervical conization followed by simple hysterectomy with lymph node assessment. The rest of the analysed population underwent hysterectomy with an unexpected diagnosis of cancer, followed by lymph node dissection only. Laparoscopic surgery was done in 83%, while robotic surgery was performed in 13%. In this study no patient underwent radical trachelectomy. After 2 years of observation 3 cases of recurrence were registered. The ConCerv study suggests that conservative surgery in early-stage, low-risk cervical cancer with tumour size less than 2.0 cm can be safe and feasible [39].

The SUCCOR study conducted from January 2013 to December 2014 revealed that minimally invasive surgery in cervical cancer had a higher risk of relapse and death than open surgery. However, avoiding the uterine manipulator gave similar outcomes to minimally invasive surgery and open surgery [40].

In surgical treatment of cervical cancer, the procedure of vaginal closure should be performed in a safe way, to prevent tumour spillage. In 2019, Köhler *et al.* conducted analysis of 1952 patients with cervical cancer in stage IB–IIA treated with combined laparoscopic-vaginal technique for radical hysterectomy to avoid tumour spillage and manipulation in this area. All procedures were performed without use of a uterine manipulator. Ten-year overall survival rates were higher than 95% [41]. In our case the use of an underpressure manipulator was also a kind of prevention of tumour spillage.

Boyraz *et al.* used a surgical stapler (EndoGIA) to close the vagina in the case of a 40-year-old woman with cervical squamous cell carcinoma in stage IB1. After removal of the manipulator, the vagina was closed using a stapler, and in that way there was no possibility of tumour spillage [42].

Lago *et al.* used a vaginal cuff closure technique as protection against tumour spillage. The vaginal cuff was closed by a running, tension-free suture. This can also be an alternative method [43]. The similar solution was described by Deura *et al.* [44].

Another method of tumour spillage prevention is to pull the round ligament without a uterine manipulator, which was performed by Meng *et al.* The follow-up after the study lasted for 18 months, and only one patient died during this time [45].

In our case, using an underpressure manipulator was also a method of prevention of tumour spillage to avoid recurrence of cervical cancer.

The comparison of laparoscopy and robotic surgery in radical surgery in early-stage cervical cancer

revealed no differences between the 2 techniques. There were no statistically significant differences in intraoperative and postoperative complications. Three-year survival in both groups of patients gave similar results. The choice of method of treatment should depend on the final decision of the patient and the operating surgeon [46].

In our case study, the patient agreed to radical trachelectomy after all the information was given about the LACC trial, the ConCerv stud, and the SUCCOR study. The desire of the patient for fertility-sparing treatment was the most significant target of the patient for making this decision.

Radical trachelectomy, as a difficult surgical procedure performed in early stage of cervical cancer, is dedicated for women in reproductive age with a desire of pregnancy.

Technically, the surgery is feasible and can be performed by any gynaecological oncologist who is skilled in radical pelvic surgery and the robotic system. Improved visualization with the robot and the fine dissection permissible with the instrument facilitate this procedure. The long-term obstetric and oncologic outcome of this technique would be expected to match the outcome of other radical trachelectomy techniques in the published literature.

In a comparison of different surgical techniques, the high pregnancy rate and low rate of premature delivery before 32 weeks GA may promote the use of the robot-assisted approach.

Using an underpressure colpotomizer decreases the risk of the cervical tumour spread during the surgery and allows for longer survival with no progression of disease. It is an alternative way of minimizing the risk of tumour spillage into the peritoneal cavity. Further investigations are needed.

### Conflict of interest

The authors declare no conflict of interest.

### References

1. Bray F, Ferlay J, Soerjomataram I, Siegel RL, Torre LA, Jemal A. Global cancer statistics 2018: GLOBOCAN estimates of incidence and mortality worldwide for 36 cancers in 185 countries. *CA Cancer J Clin* 2018; 68: 394-424.
2. Hota, PK, Panda N, Nayak B, Samantaray S. Geographical distribution of cervical cancer in Odisha: a 5-year retrospective study at a regional cancer center. *South Asian J Cancer* 2018; 7: 34-36.
3. Cancer stat facts: cervical cancer, National Cancer Institute, Surveillance, Epidemiology, and End Result Program <https://seer.cancer.gov/statfacts/html/cervix.html> (9/19/2019).
4. Central Registration of Cancers in Poland. <http://onkologia.org.pl>
5. Siegel RL, Miller KD, Jemal A. Cancer statistics, 2019, *CA Cancer J. Clin* 2019; 69: 7-34.
6. Sindiani AM, Alshdaifat EH, Alkhatib A. Investigating cervical risk factors that lead to cytological and biopsy examination. *Med Arch* 2020; 74: 294-297.
7. Stumbar S, Stevens M, Feld Z. Cervical cancer and its precursors: a preventative approach to screening, diagnosis and management. *Prim Care* 2019; 46: 117-134.
8. Bentivegna E, Maulard A, Pautier P, Chargari C, Gouy S, Morice P. Fertility results and pregnancy outcomes after conservative treatment of cervical cancer: a systematic review of the literature. *Fertil Steril* 2016; 106: 1195-1211.
9. Dargent D, Brun JL, Roy M, Mathevest P, Remy I. La trachelectomie elargie (TE), une alternative a l'hysterectomie radical dans le traitement des cancers infiltrants developpes sur la face externe du col uterin. *J Obstet Gynecol* 1994; 2: 285-292.
10. Cibula D, Ungar L, Palfalvi L, Bino B, Kuzel D. Laparoscopic abdominal radical trachelectomy. *Gynecol Oncol* 2005; 97: 707-709.
11. Persson J, Kannisto P, Bossmar T. Robot-assisted abdominal laparoscopic radical trachelectomy. *Gynecol Oncol* 2008; 111: 564-567.
12. Cibula D, Potter R, Planchamp F, Avall-Lundqvist E, Fischerova D, Meder C, Kohler C, Landoni F, Lax S, Lindgaard J, Mahantshetty U, Mathevet P, McCluggage G, McCormack M, Naik R, Nout R, Pignata S, Ponce J, Querleu D, Raspagliesi F, Rodolakis A, Tamussino K, Wimmerberger P, Raspollini M. The European Society of Gynaecological Oncology/European Society for Radiotherapy and Oncology/European Society of Pathology Guidelines for the Management of Patients with cervical cancer. *Int J Gyn Cancer* 2018; 28: 641-655.
13. Matsuo K, Matsuzaki S, Mandelbaum RS, Matsushima K, Klar M, Grubbs BH, Roman LD, Wright JD. Association between hospital surgical volume and perioperative outcomes of fertility-sparing trachelectomy for cervical cancer: a national study in the United States. *Gynecol Oncol* 2020; 157: 173-180.
14. Han L, Yang XY, Zheng A, Wang L, Chu YX, Wang Y. Systematic comparison of radical vaginal trachelectomy and radical hysterectomy in the treatment of early-stage cervical cancer. *Int J Gynaecol Obstet* 2011; 112: 149-153.
15. Persson J, Imboden S, Reynisson P, Andersson B, Borgfeldt C, Bossmar T. Reproducibility and accuracy of robot-assisted laparoscopic fertility sparing radical trachelectomy. *Gynecol Oncol* 2012; 127: 484-488.
16. Plante M, Gregoire J, Renaud MC, Sebastianelli A, Grondin K, Noel P, Roy M. Simple vaginal trachelectomy in early-stage low-risk cervical cancer: a pilot study of 16 cases and review of the literature. *Int J Gynecol Cancer* 2013; 23: 916-922.
17. Vieira M, Rendon G, Munsell M, Echeverri L, Frumovitz M, Schmeler K, Pareja R, Escobar P, Dos Reis R, Ramirez P. Radical trachelectomy in early-stage cervical cancer: a comparison of laparotomy and minimally invasive surgery. *Gynecol Oncol* 2015; 138: 585-589.
18. Kucukmetin A, Biliatis I, Ratnavelu N, Patel A, Cameron I, Ralte A, Naik R. Laparoscopic radical trachelectomy is an alternative to laparotomy with improved perioperative outcomes in patients with early-stage cervical cancer. *Int J Gynecol Cancer* 2014; 24: 135-140.
19. Geisler JP, Orr CJ, Manahan KJ. Robotically assisted total laparoscopic radical trachelectomy for fertility sparing

- in stage IB1 adenosarcoma of the cervix. *J Laparoendosc Adv Surg Tech A* 2008; 18: 727-729.
20. Saadi JM, Perrotta M, Orti R, Salvo G, Giavedoni M, Gogorza S, Testa R. Laparoscopic radical trachelectomy: technique, feasibility and outcomes. *JLS* 2015; 19: e2013.00248.
  21. Baiocchi G, de Brot L, Faloppa C, Mantoan H, Duque MR, Badiglian-Filho L, Balieiro A, da Costa A.; Kumagai L. Is parametrectomy always necessary in early-stage cervical cancer? *Gynecol Oncol* 2017; 146: 16-19.
  22. Abu-Rustum NR, Sonoda Y, Black D, Levine DA, Chi DS, Barakat RR. Fertility-sparing radical abdominal trachelectomy for cervical carcinoma: technique and review of the literature. *Gynecol Oncol* 2006; 103: 807-813.
  23. Wenzel L, Dogan-Ates A, Habbal R, Berkowitz R, Goldstein DP, Bernstein M, Kluhsman BC, Osann K, Newlands E, Seckl MJ, Hancock B, Cella D. Defining and measuring reproductive cancers survivors. *J Nat Cancer Inst* 2005; 34: 94-98.
  24. Floyd J, Campbell S, Rauh-Hoin J, Woodard T. Fertility preservation in women with early-stage gynecological cancer: optimizing oncologic and reproductive outcomes. *Int J Gynecol Cancer* 2021; 31: 345-351.
  25. Lu Q, Liu C, Zhang Z. Total laparoscopic radical trachelectomy in the treatment of early-stage cervical cancer: review of technique and outcomes. *Curr Opin Obstet Gynecol* 2014; 26: 302-307.
  26. Dańska-Bidzińska A, Sobczewski P, Bidziński M, Gujski M. Radical trachelectomy – retrospective analysis of our own case material. *Ginekol Pol* 2011; 82: 436-440.
  27. Shah JS, Jooya ND, Woodard TL, Ramirez P, Fleming ND, Frumovitz M. Reproductive counseling and pregnancy outcomes after radical trachelectomy for early-stage cervical cancer. *J Gynecol Oncol* 2019; 30: e45.
  28. Rob L, Skapa P, Robova H. Fertility-sparing surgery in patients with cervical cancer, *Lancet Oncol* 2011; 12: 192-200.
  29. Simjak P, Parizek A, Slama J. Prenatal care for woman after fertility-sparing surgery for cervical cancer. *Ceska Gynekol* 2020; 85: 422-429.
  30. Breban-Kehl M, Zaccarini F, Sanson C, Maulard A, Scherrier S, Genestie C, Chargari C, Pautier P, Leary A, Balleyguier C, Morice P, Gouy S. Fertility preservation in cervical cancer, analysis of 30 years of practice and immersion in future developments. *Gynecol Obstet Fertil Senol* 2022; 50: 62-68.
  31. Ramirez P, Schmeler KM, Soliman P, Frumovitz M. Fertility preservation in patients with early cervical cancer: radical trachelectomy. *Gynecol Oncol* 2008; 110 (3 Suppl 2): 25-28.
  32. Ishioka S, Endo T, Hayashi T, Baba T, Umemura K, Saito T. Pregnancy-related complications after vaginal radical trachelectomy for early-stage invasive uterine cervical cancer. *Int J Clin Oncol* 2007; 12: 350-355.
  33. Basta P, Kolawa W, Stangel-Wójcikiewicz K, Schwarz J. Pregnancy and labor after fertility-sparing surgical management of cervical cancer. *Ginekol Pol* 2015; 86: 700-705.
  34. Muraji M, Sudo T, Iwasaki S, Ueno S, Wakahashi S, Yamaguchi S, Fujiwara K, Nishimura R. The effect of abdominal radical trachelectomy on ovarian reserve: serial changes in serum Anti-Mullerian Hormone levels. *J Cancer* 2012; 3: 191-195.
  35. Fanfani F, Landoni F, Gagliardi ML, Fagotti A, Preti E, Moruzzi MC, Monterossi G, Scambia G. Sexual and reproductive outcomes in early-stage cervical cancer patients after excisional cone as a fertility-sparing surgery: an Italian experience. *J Reprod Infertil* 2014; 15: 29-34.
  36. Chan J, Letourneau J, Salem W, Cil A, Chan SW, Chen LM, Rosen M. Sexual satisfaction and quality of life in survivors of localized cervical and ovarian cancers following fertility-sparing surgery. *Gynecol Oncol* 2015; 139: 141-147.
  37. Kampers J, Gerhardt E, Sibbertsen P, Flock T, Klapdor R, Hertel H, Jentschke M, Hillemanns P. Protective operative techniques in radical hysterectomy in early cervical carcinoma and their influence on disease-free and overall survival: a systematic review and metaanalysis of risk groups. *Arch Gynecol Obstet* 2021; 304: 577-587.
  38. Ramirez P, Frumovitz M, Pareja R, Lopez A, Vieira M, Ribeiro R, Buda A, Yan X, Shuzhong Y, Chetty N, Isla D, Tamura M, Zhu T, Robledo K, Gebiski V, Stat M, Asher R, Behan V, Nicklin J, Coleman R, Obermair A. Minimally invasive versus abdominal radical hysterectomy for cervical cancer. *N Engl J Med* 2018; 379: 1895-1904.
  39. Schmeler K, Pareja R, Blanco A, Fregnani J, Lopes A, Perrotta M, Tsunoda A, Cantu-de-Leon D, Ramondetta L, Machana J, Crotzer D, McNally O, Riege M, Scambia G, Carvajal J, Guilmi J, Rendon G, Ramalingam P, Fellman B, Coleman R, Frumovitz M, Ramirez P. ConCerv: a prospective trial of conservative surgery for low-risk early-stage cervical cancer. *Int J Gynecol Cancer* 2021; 31: 1317-1325.
  40. Chiva L, Zanagnolo V, Querleu D, Martin-Calvo N, Arevalo-Serrano J, Capilna M, Fagotti A, Kucukmetin A, Mom C, Chakalova G, Aliyev S, Malzoni M, Narducci F, Arencibia O, Raspagliesi F, Toptas T, Cibula D, Kaidarova D, Meydani M, Tavares M, Golub D, Perrone A, Poka R, Tsolakidis D, Vujic G, Jedryka M, Zusterzeel P, Beltman J, Goffin F, Haidopoulos D, Haller H, Jach R, Yezhova I, Berlev I, Bernardino M, Bharathan R, Lanner M, Maenpaa M, Sukhin V, Feron J, Fruscio R, Kukk K, Ponce J, Minguez J, Vazquez-Vicente D, Castellanos T, Chacon E, Alcazar J. SUCCOR study: an international European cohort observational study comparing minimally invasive surgery versus open abdominal radical hysterectomy in patients with stage IB1 cervical cancer. *Int J Gynecol Cancer* 2020; 30: 1269-1277.
  41. Köhler C, Hertel H, Hermann J, Marnitz S, Mallman P, Favero G, Plaikner A, Martus P, Gajda M, Schneider A. Laparoscopic radical hysterectomy with transvaginal closure of vaginal cuff – a multicenter analysis. *Int J Gynecol Cancer* 2019; 29: 845-850.
  42. Boyraz G, Karalok A, Basaran D, Turan T. Vaginal closure with EndoGIA to prevent tumor spillage in laparoscopic radical hysterectomy for cervical cancer. *J Minim Invasive Gynecol* 2019; 26: 602.
  43. Lago V, Tiermes M, Padilla-Iserte P, Matute L, Gurrea M, Domingo S. Protective maneuver to avoid tumor spillage during laparoscopic radical hysterectomy: vaginal cuff closure. *J Minim Invasive Gynecol* 2021; 28: 174-175.
  44. Deura I, Kanamori R, Nagasawa Y, Kuji S, Ohara T, Tozawa A, Shimada M, Suzuki N. A simple technique of vaginal cuff closure to prevent tumor cell spillage in laparoscopic radical hysterectomy for uterine cervical cancer. *Asian J Endosc Surg* 2021; 14: 665-668.



45. Meng S, Li Z, Chen L, Yang X, Su P, Wang Y, Yi P. Laparoscopic radical hysterectomy for cervical cancer by pulling the round ligament without a uterine manipulator. *Eur J Obstet Gynecol Reprod Biol* 2021; 264: 31-35.
46. Gallotta V, Conte C, Federico A, Vizzielli G, Alletti S, Tortorella L, Anchora L, Cosentino F, Chiantera V, Fagotti A, D'Indinosante M, Pelligra S, Scamba G, Ferrandina G. Robotic versus laparoscopic radical hysterectomy in early cervical cancer: a case matched control study. *Eur J Surg Oncol* 2018; 44: 754-759.

**Address for correspondence:**

Magdalena Bizoń  
NEO HOSPITAL  
ul. Kostrzewskiego 47  
30-437 Krakow, Poland  
Phone: +48 697 722 894  
E-mail: magdalena.bizon1@gmail.com