

Evaluation of the nailfold skin capillaroscopic modifications of psoriatic patients and levels of the transforming growth factor α and vascular endothelial growth factor: an initiative paper

Beata Bergler-Czop, Ligia Brzezińska-Wcisło, Ewa Syguta

Department of Dermatology, Silesian Medical University, Katowice, Poland
Head: Prof. Ligia Brzezińska-Wcisło MD, PhD

Post Dermatol Alergol 2011; XXVIII, 6: 428–434

Abstract

Introduction: Psoriasis occurs in 1-5% of population and admissions to hospitals include 6-8% of patients in the dermatological wards. Angiogenesis plays a role in pathogenesis of many skin disorders and it is one of basic phenomena observed in psoriasis.

Aim: The aim of this study was to compare capillaroscopic images and neovascularisation factors in the patients diagnosed with psoriasis as well as to assess progress in psoriasis treatment in this group of patients.

Results: The preliminary analysis showed existence of a statistically significant correlation between tumour growth factor α (TGF- α) and vascular endothelial growth factor (VEGF) levels in the patients' sera and the capillaroscopic image of these patients. Additionally, a correlation was observed between PASI results, tested neovascularisation factors and capillaroscopic images. The obtained results suggest a possibility to use capillaroscopy and diagnosis of neovascularisation factors to diagnose and assess the progress of psoriasis treatment.

Conclusions: The study had a preliminary character and it is still continued.

Key words: psoriasis vulgaris, capillaroscopy, angiogenesis.

Introduction

Psoriasis occurs in 1-5% of population and admissions to hospitals include 6-8% of patients in the dermatological wards [1]. Angiogenesis plays a role in pathogenesis of many skin disorders and it is one of basic phenomena observed in psoriasis. Multiple cytokines are involved in this process: transforming growth factor α (TGF- α), vascular endothelial growth factor (VEGF), interleukin 8 (IL-8), tumour necrosis factor α (TNF- α), platelet-derived endothelial cell growth factor/thymidine phosphorylase (PDECGF/TP).

Neoangiogenesis is also related with excessive expression of adhesion proteins (integrin α V β 3, selectin) on the endothelial cell surface. Described changes lead to abnormalities in vessels, which can be visualised by capillaroscopy.

The radioisotope method showed that vascular abnormalities are the cause of 10 to 13 times faster

blood flow in the psoriatic plaques. Proliferation of endothelial cells of the venous part leads to elongation of a vessel and its penetration into an elongated dermal papilla. The arterial part of the capillary shortens and almost all its loop becomes a venous capillary. The dominating venous part also shows different numbers of basal membrane layers and the presence of holes in the endothelium.

The capillaries on the margins of a psoriatic plaque are parallel to the skin surface and become perpendicular upon movement towards the unchanged skin. It was also concluded that the number of the vascular loops in the indirect proximity of the skin changes is higher than within the changes [2-4].

The vascular changes are also observed in persons with psoriasis within the unchanged skin. There is little literature on capillaroscopic changes in the patients with diagnosed psoriasis in combination with assessment of the levels of neovascularisation factors.

Address for correspondence: Beata Bergler-Czop MD, PhD, Department of Dermatology, Silesian Medical University, 20/24 Francuska, 40-027 Katowice, Poland, phone/fax: +48 32 256 11 82, e-mail: bettina2@tlen.pl

Aim

The aim of this study was to compare capillaroscopic images and neovascularisation factors in the patients diagnosed with psoriasis and to assess progress in psoriasis treatment in this group of patients.

Material and methods

The study was carried out among patients treated for common psoriasis in the Dermatology Clinics of the Silesian Medical University in Katowice in 2010-2012. Up to date, the study has been performed in 40 patients treated only externally (mean age 41.62 years) and in 40 controls (mean age 35.4 years).

During the visit, the patients were classified into the study, clinical tests (PASI) and a detailed interview (questionnaire) were performed. Assessment of microcirculation in II-V fingers was performed using a capillaroscope. The examination was performed after a 15-min rest and at room temperature of 20-22°C. The patients also gave a sample of venous blood for determination of TGF- α and VEGF levels using ELISA.

Qualification criteria:

- diagnosis of common psoriasis, confirmed by histopathology examination,
- only external treatment during the previous year (without phototherapy).

The following patients were excluded from the group:

- with recognised accompanying ailments, in which changes may be related with microcirculation,
- patients using drugs for microcirculation,
- patients, in whom it was impossible to perform capillaroscopy for technical reasons,
- patients with changes in nail plates,
- patients with diagnosed psoriatic arthritis.

Results

Vascular endothelial growth factor

The levels of VEGF in the control group are statistically significantly different than in patients with psoriasis vulgaris. The level of VEGF is higher in patients with psoriasis vulgaris (Tables 1-2, Figure 1).

Transforming growth factor α

The levels of TGF- α in the control group are statistically significantly different than in patients with psoriasis vulgaris. The level of TGF- α is higher in patients with psoriasis vulgaris (Tables 3-4, Figure 2).

Vascular endothelial growth factor and capillaroscopy changes: patients with psoriasis vulgaris

The test results indicate that the groups are statistically significantly different. In a group of patients with

a higher level of VEGF, changes in capillaroscopy are significantly more frequent (Tables 5-6, Figure 3).

In our patients, the most common capillaroscopy pathological changes included bushy capillaries, torturous capillaries, vascular elongations, congestive loops, sinuous, short and glomerular capillaries.

Transforming growth factor α and capillaroscopy changes: patients with psoriasis vulgaris

The test results indicate that the groups are statistically significantly different. In a group of patients with a higher level of TGF- α , changes in capillaroscopy are significantly more frequent (Tables 7, 8, Figure 4).

Table 1. VEGF in control group and in patients with psoriasis vulgaris

VEGF [pg/ml]	Median	Minimum	Maximum	Standard deviation
Patients	33.57728	9.200000	105.7000	22.48301
Control	7.71315	1.450000	22.1000	4.82800

Table 2. VEGF in control group and in patients with psoriasis vulgaris

	U Mann-Whitney's test	Z	Value of p
VEGF [pg/ml]	46	7.192559	0.000001

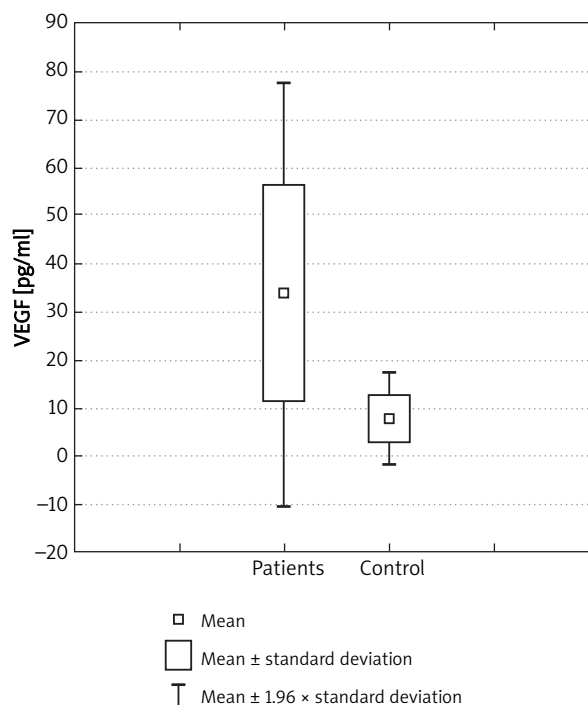


Fig. 1. VEGF in control group and in patients with psoriasis vulgaris

Table 3. TGF- α in control group and in patients with psoriasis vulgaris

TGF- α [pg/ml]	Median	Minimum	Maximum	Standard deviation
Patients	1.221480	0.004000	3.430000	0.918807
Control	0.544830	0.004000	1.800000	0.555281

Table 4. TGF- α in control group and in patients with psoriasis vulgaris

TGF- α [pg/ml]	U Mann-Whitney's test	Z	Value of p
	441	3.449668	0.000561

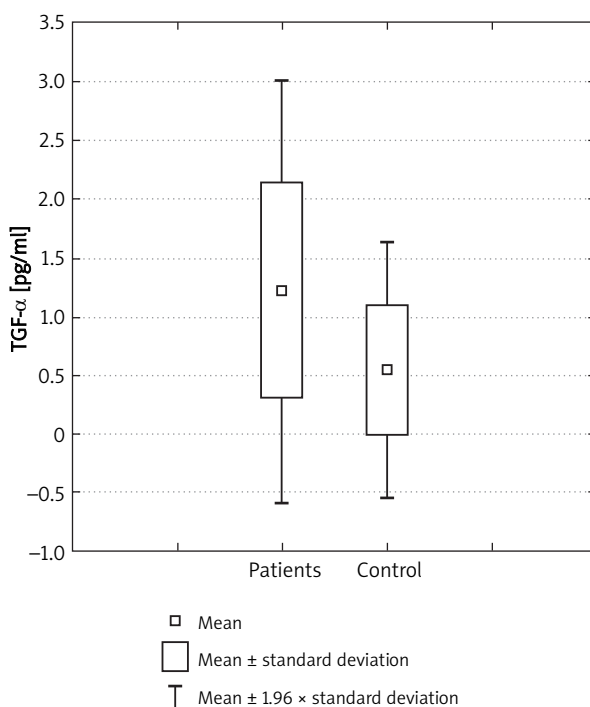


Fig. 2. TGF- α in control group and in patients with psoriasis vulgaris

Microcirculatory changes and PASI

The test results indicate that the groups are statistically significantly different. In a group of patients with higher PASI, changes in capillaroscopy are significantly more frequent (Tables 9-10, Figure 5).

Transforming growth factor α and PASI

The correlation coefficient is $p = 0.011$. In patients with higher PASI, the level of TGF- α is higher (Figure 6).

Vascular endothelial growth factor vs. PASI

The correlation coefficient is $p = 0.0001$. In patients with higher PASI, the level of VEGF is higher (Figure 7).

Table 5. VEGF in patients with psoriasis and changes in capillaroscopy and in group without changes

VEGF [pg/ml]	N	Median	Minimum	Maximum	Standard deviation
Changes	21	43.99371	11.57800	105.7000	26.06108
Without changes	19	21.23716	9.200000	32.83000	6.236363

Table 6. VEGF in patients with psoriasis and changes in capillaroscopy and in group without changes

VEGF – patients with psoriasis [pg/ml]	U Mann-Whitney's test	Z	Value of p
	68	-3.548	0.000388

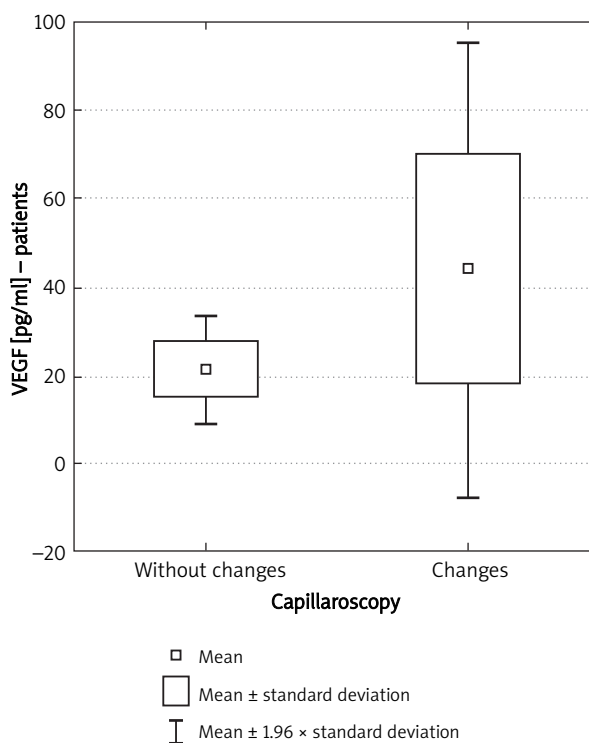


Fig. 3. VEGF in patients with psoriasis and changes in capillaroscopy and in group without changes

Discussion

Capillaroscopy is a non-invasive study carried out using a capillaroscopic microscopy or a videocapillaroscope. This examination allows us to observe the flowing blood, make measurements and a detailed quantitative and qualitative assessment of the skin and mucosal capillaries. It also allows us to determine microcirculation in different body parts, such as trunk, hands, feet and lower legs [5].

Table 7. TGF- α in patients with psoriasis and changes in capillaroscopy and in group without changes

TGF- α [pg/ml]	N	Median	Minimum	Maximum deviation	Standard deviation
Without changes	19	0.884105	0.004000	2.700000	0.775104
Changes	21	1.526724	0.034200	3.430000	0.948436

Table 8. TGF- α in patients with psoriasis and changes in capillaroscopy and in group without changes

	t-Student's test	df	Value of p
TGF- α – patients with psoriasis [pg/ml]	-2.33115	38	0.02515

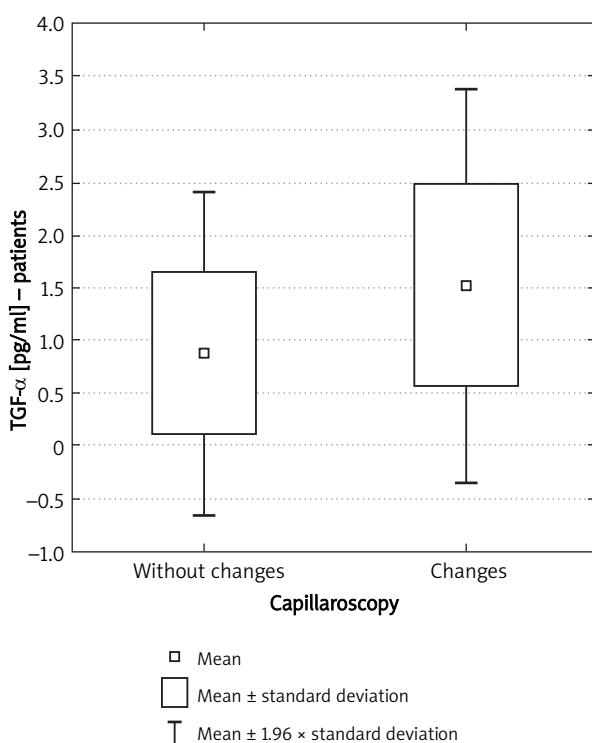


Fig. 4. TGF- α in patients with psoriasis and changes in capillaroscopy and in group without changes

The following characteristics are monitored during examination:

- 1) megacapillaries – giant or dilated loops,
- 2) extravasations,
- 3) depletion of capillaries, and avascular areas,
- 4) disturbances in the capillaries' pattern,
- 5) tortuous capillaries (bush pattern) [2-4].

Assessment of microcirculation in many papers on psoriasis was performed within the psoriatic plaques. Such assessment visualises only the upper part of the

Table 9. PASI in patients with psoriasis and changes in capillaroscopy and in group without changes

PASI	N	Median	Minimum	Maximum deviation	Standard deviation
Changes	21	19.77619	12.10000	36.00000	6.619132
Without changes	19	14.67895	11.70000	23.10000	2.931359

Table 10. PASI in patients with psoriasis and changes in capillaroscopy and in group without changes

	U Mann-Withney's test	Z	Value of p
PASI	84.5	-3.10111	0.001928

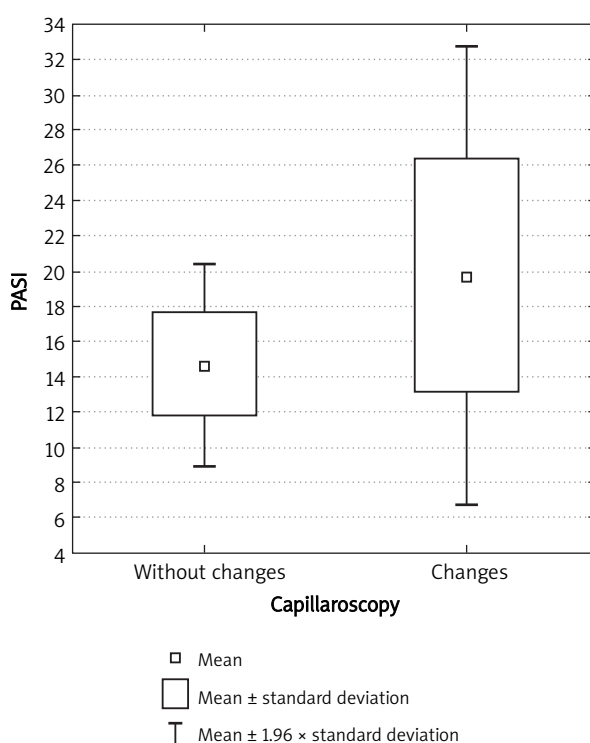


Fig. 5. PASI in patients with psoriasis and changes in capillaroscopy and in group without changes

capillary loop, while the capillaroscopy of nailfolds helps to assess the whole loop.

In our study, 52% of patients with diagnosed psoriasis, treated only externally showed changes in the capillaroscopy examination. The most common pathological changes included bushy capillaries, torturous capillaries, vascular elongations, congestive loops, sinuous, short and glomerular capillaries.

Hern *et al.* [6] made a comparison in order to determine whether there were any differences in microvascu-

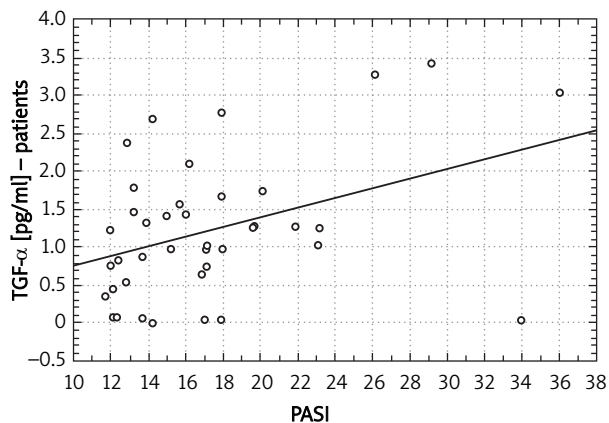
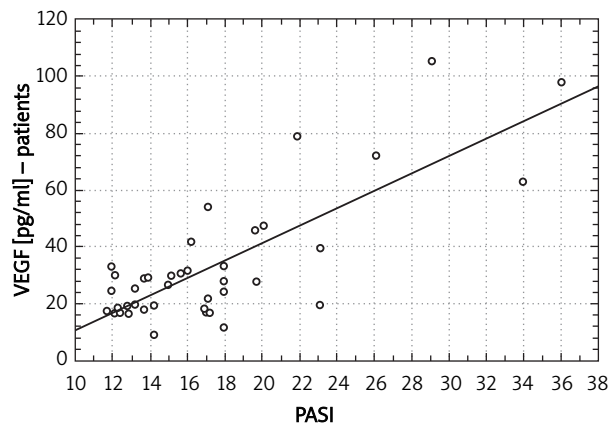
Fig. 6. TGF- α and PASI

Fig. 7. VEGF and PASI

lar parameters in both the clinically uninvolved skin of psoriatic subjects and in the skin of normal volunteers. Quantitative analysis of capillaroscopic images showed that there were no significant differences in microvessel density. In the other authors, the results are quite different. Bull *et al.* [7] demonstrated clear differences between normal and psoriatic skin. More capillaries were red cell-perfused in both plaque and uninvolved skin compared to normal skin. The density of capillaries was not increased in plaque or uninvolved psoriatic skin.

Micali *et al.* [8] used capillaroscopy in various dermatoses of the hand and feet. Thirty-two subjects were sequentially enrolled in an open-label study involving a single visit. Inclusion criteria were the presence of clinically nonspecific, active, and untreated palmar and/or plantar erythematous scaly lesions with no other skin involvement. Exclusion criteria were the presence of comorbid disorders, excessive hyperkeratosis and/or pustular lesions, and the use of systemic and/or topical drugs within 4 and 2 weeks of study enrollment, respectively. In the same group of patients, the diagnosis was confirmed by histologic examination. In 15 subjects, typical features of psoriasis were observed (the same in the histology). In the remaining 17 patients, the diagnosis of eczema was established by histology and the capillaroscopy picture was rather different.

Rosina *et al.* [9] used videocapillaroscopy to differentiate between psoriasis and seborrheic dermatitis when the scalp is the only affected site. The examination was conducted in 30 patients. Videocapillaroscopy was performed on histology-confirmed scalp lesions. The authors said that this method could be a useful noninvasive approach to differentiating between psoriasis and seborrheic dermatitis.

Bhushan *et al.* [10] recruited forty-four patients with psoriasis. Capillary density and standard capillary dimensions were studied and compared with those of 44 age- and sex-matched control subjects. In contrast to previous

studies, they found no specific pattern of a morphological nature of nailfold capillaries in patients with psoriasis with or without nail changes, when compared with normal controls.

In our study, only patients with psoriasis vulgaris were qualified. In other publications, we have a lot of information about microcirculation in patients with arthropathic psoriasis.

Salli *et al.* [11] evaluated the microcirculation through periungueal capillaroscopy in eighteen patients suffering from psoriatic arthritis. In most of the patients, the exam showed a reduction in anasas' density and in capillary length and caliber as well as interstitial edema and expansion of the ansa venular portion with coiling and kinking, demonstrating the re-organization of the veins and the neo-angiogenesis. Microaneurysms have also been found.

A lot of publications evaluated, using capillaroscopy, the results of various forms of antipsoriatic therapy. Our preliminary study was conducted only in patients treated locally.

Rosina *et al.* [12] analyzed clinical and capillaroscopic modifications in comparable lesions of the elbows during different topical therapies (calcipotriol, betamethasone dipropionate and calcipotriol plus betamethasone dipropionate) at baseline, and after 15 and 30 days of therapy. Topical therapy with combined betamethasone dipropionate and calcipotriol induced a higher decrease in erythema, infiltration and desquamation and a significant reduction of the mean 'bush' diameter and capillary number/mm² compared with betamethasone and calcipotriol alone.

Stinco *et al.* [13] evaluated the modifications of the superficial capillary bed in a psoriatic plaque and healthy perilesional skin during treatment with a topical steroid. In total, 24 patients affected with psoriasis vulgaris were enrolled. Each patient was instructed to apply mometasone furoate cream 0.1% once daily to a selected psoriatic lesion for 12 weeks; clinical and capillaroscopic exam-

ination was made of the psoriatic plaque and the surrounding skin. Mometasone furoate cream proved to be effective in reducing the clinical and capillaroscopic alterations of the psoriatic plaque, but there was no association between clinical improvement and microcirculatory alterations noted.

The same author observed and quantified the modifications of the superficial capillary bed in psoriatic plaques during treatment with cyclosporine A. Twelve patients with psoriasis vulgaris were treated with an initial dose of 4 mg/kg/day cyclosporine A over a period of 3 months with periodic clinical and capillaroscopic assessments. Clinical resolution of the lesions and a reduction in microcirculatory alterations was observed in 70% of patients, although none returned to a normal capillaroscopic pattern [14].

Hern *et al.* [15] quantified the structural vascular abnormalities in plaque skin using noninvasive techniques *in vivo*. Investigations were carried out before and after PDL treatment to determine the nature of laser-induced microvascular changes and the relationship between these changes and clinical improvement. Plaque microvessels were visualized using native capillaroscopy. Plaques were then treated three times with the PDL at 14-day intervals. Whole body disease was stable. Treated plaques showed a 48% reduction in plaque severity score.

Trvisan *et al.* [16] examined the effects of systemic etretinate or PUVA therapy on capillary functions. They used the nailfolds of 30 patients affected by diffuse psoriasis for less than 3 years. The authors evaluated the percentage of capillary minor dystrophies (type I-IV) and the flow rate before and after 1 month of treatment. These parameters were assessed by means of a 1-4 rating scale. The results underlined that a significant percentage of 1st type dystrophies is a prognostic rather than a diagnostic parameter in the capillaroscopic evaluation of psoriasis.

Several studies suggest that microangiopathy plays a crucial role in the pathogenesis of psoriasis. It is connected with a lot of cytokines: TGF- α , VEGF, IL-8, TNF- α , PDECGF/TP and IL-17. The mediators derived from keratinocytes, monocytes and the other cells of the immunology system [17]. In the present study, we have evaluated levels of two cytokines: VEGF and TGF- α .

Vascular endothelial growth factor is a mitogen that stimulates migration and separation of the endothelial cells. This factor plays a role not only in the neovascularization process but also influences their morphology [17]. Transforming growth factor- α is produced by macrophages, keratinocytes and neurons. It induces epithelial cells and proliferation of the neural cells. This factor is closed to EGF and it could be connected by EGF receptors [18].

In our study, in both cases, we observed a correlation between changes in capillaroscopy examination and higher levels of VEGF and TGF- α in the patients' sera. Both factors had also higher levels in psoriatic patients than in

the sera of healthy volunteers. In the literature, we did not find much information about this topic.

Campanati *et al.* [19] verified the effect of etanercept on cutaneous en plaque capillaries *in vivo* using intra-vital videocapillaroscopy analysis to evaluate the relation between the en plaque videocapillaroscopic pattern and the immunohistochemical cutaneous expression of VEGF in psoriasis. Tumour necrosis factor- α up-regulates the genetic transcription of VEGF, a pro-angiogenic cytokine over-expressed in psoriatic skin, which promotes microangiopathic modifications in psoriatic plaque. Etanercept is a chimeric protein used in the treatment of psoriasis and other immunomediated disorders, which blocks inflammatory response by interfering in the binding of TNF- α to its receptors.

Eighteen patients suffering from stable, en plaque type psoriasis, involving at least 10% of body surface area (BSA), and not responsive to conventional therapy were included in the study. All the enrolled patients received etanercept 50 mg twice a week, subcutaneously, for 12 weeks. All the patients experienced a clinical improvement of cutaneous disease with a significant decrease of PASI score. On capillaroscopy analysis, microangiopathy dramatically decreased, this modification being significantly related with PASI. Immunohistochemical expression of VEGF decreased significantly and was related with a reduction of psoriatic microangiopathy. The results of our videocapillaroscopic and immunohistochemical investigation confirm that the therapeutic potentiality of etanercept is based also on its capability to promote the regression of psoriatic microangiopathy.

Petzelbauer *et al.* [20] evaluated the pattern of cytokine inducibility of endothelial-leukocyte adhesion molecule 1 (ELAM-1) and vascular cell adhesion protein 1 (VCAM-1) in altered dermal microvessels of psoriatic patients. The dermal microvasculature of lesional skin contained ELAM-1+ in 29.4% of vessels and VCAM-1+ endothelial cells in 8.7% of vessels. After 24 h of organ culture in medium supplemented with tumor necrosis factor and IL-4, ELAM-1+ endothelial cells were increased significantly in uninvolved, perilesional and lesional skin. Vascular cell adhesion protein 11 was not inducible in uninvolved skin but VCAM-1+ endothelial cells were increased significantly in perilesional and lesional skin.

The preliminary analysis showed existence of a statistically significant correlation between TGF- α and VEGF levels in the patients' sera and the capillaroscopic image of these patients. Additionally, a correlation was observed between PASI results, tested neovascularisation factors and capillaroscopic images. The obtained results suggest a possibility to use capillaroscopy and diagnosis of neovascularisation factors to diagnose and assess the progress of psoriasis treatment. The study had a preliminary character and it is still continued.

References

1. Braun-Falco O, Plewig G, Wolff HH, et al. Łuszczycza [In Polish]. In: *Dermatologia*. Braun-Falco O, Plewig G, Wolff HH, et al. (eds.). Wydawnictwo Czelej, Lublin 2000; 557-80.
2. Bartosińska J, Chodorowska G. Autorska propozycja klasyfikacji obrazów kapilaroskopowych w łuszczycy zwyczajnej i stawowej. *Post Dermatol Alergol* 2009; 26: 17-24.
3. Bartosińska J, Chodorowska G, Krasowska D, et al. Przydatność kapilaroskopii do oceny zmian naczyniowych o charakterze angiogenezy w łuszczycy. *Post Dermatol Alergol* 2008; 25: 276-82.
4. Bartosińska J, Chodorowska G, Dabrowska-Członka M, et al. Zmiany kapilaroskopowe w łuszczycy. *N Med* 2006; 1: 28-31.
5. Michalska-Jakubus M, Chodorowska G, Krasowska D. Nailfold capillaroscopy. Microscopic assessment of microcirculation abnormalities in systemic sclerosis. *Post Dermatol Alergol* 2010; 27: 106-18.
6. Hern S, Stanton AW, Mellor RH, et al. In vivo quantification of the structural abnormalities in psoriatic microvessels before and after pulsed dye laser treatment. *Br J Dermatol* 2005; 152: 505-11.
7. Bull RH, Bates DO, Mortimer PS. Intravital video-capillaroscopy for the study of the microcirculation in psoriasis. *Br J Dermatol* 1992; 126: 436-45.
8. Micali G, Nardone B, Scuderi A, et al. Videodermatoscopy enhances the diagnostic capability of palmar and/or plantar psoriasis. *Am J Clin Dermatol* 2008; 9: 119-22.
9. Rosina P, Zamperetti MR, Giovannini A, et al. Videocapillaroscopy in the differential diagnosis between psoriasis and seborrheic dermatitis of the scalp. *Dermatology* 2007; 214: 21-4.
10. Bhushan M, Moore T, Herrick AL, et al. Nailfold video capillaroscopy in psoriasis. *Br J Dermatol* 2000; 142: 1171-6.
11. Salli L, Raimondi F, Pappalardo A. Periungual capillaroscopy in psoriatic arthritis. *Clin Ther* 1999; 150: 409-12.
12. Rosina P, Giovannini A, Gisondi P, et al. Microcirculatory modifications of psoriatic lesions during topical therapy. *Skin Res Technol* 2009; 15: 135-8.
13. Stinco G, Lautieri S, Piccirillo F, et al. Response of cutaneous microcirculation to treatment with mometasone furoate in patients with psoriasis. *Clin Exp Dermatol* 2009; 34: 915-9.
14. Stinco G, Lautieri S, Valent F, et al. Cutaneous vascular alterations in psoriatic patients treated with cyclosporine. *Acta Derm Venereol* 2007; 87: 152-4.
15. Hern S, Mortimer PS. In vivo quantification of microvessels in clinically uninvolved psoriatic skin and in normal skin. *Br J Dermatol* 2007; 156: 1224-9.
16. Trevisan G, Magaton Rizzi G, Dal Canton M. Psoriatic microangiopathy modifications induced by PUVA and etretinate therapy. A nail-fold capillary microscopic study. *Acta Derm Venereol* 1989; 146: 53-6.
17. Heidenreich R, Röcken M, Ghoreschi K. Angiogenesis drives psoriasis pathogenesis. *Int J Exp Pathol* 2009; 90: 232-48.
18. Azambuja AP, Portillo-Sánchez V, Rodrigues MV, et al. Retinoic acid and VEGF delay smooth muscle relative to endothelial differentiation to coordinate inner and outer coronary vessel wall morphogenesis. *Circ Res* 2010; 107: 204-16.
19. Campanati A, Goteri G, Simonetti O, et al. Angiogenesis in psoriatic skin and its modifications after administration of etanercept: videocapillaroscopic, histological and immunohistochemical evaluation. *Int J Immunopathol Pharmacol* 2009; 22: 371-7.
20. Petzelbauer P, Pober JS, Keh A, et al. Inducibility and expression of microvascular endothelial adhesion molecules in lesional, perilesional, and uninvolved skin of psoriatic patients. *J Invest Dermatol* 1994; 103: 300-5.