

Original paper

Liver pathology in children with newly diagnosed celiac disease

Kamila Agnieszka Kwiatek-Średzińska¹, Katarzyna Kondej-Muszyńska¹, Mirosława Uścińowicz¹, Irena Werpachowska¹, Maria Sobaniec-Łotowska², Dariusz Lebensztein¹

¹Department of Pediatrics, Gastroenterology, Hepatology, Nutrition and Allergology, Medical University of Białystok, Poland

²Department of Medical Pathomorphology, Medical University of Białystok, Poland

Abstract

Aim of the study: To evaluate the prevalence and the type of liver pathology in children at the time of diagnosis of celiac disease (CD).

Material and methods: Data from newly diagnosed children with CD hospitalized in the university hospital were retrospectively reviewed. Liver pathology was defined as elevated alanine transaminase (ALT) and/or gamma-glutamyl transpeptidase (GGT) serum activity and/or pathological changes of the organ in ultrasound.

Results: Liver pathology was detected in 17 of 149 children (11.4%). Ten patients (6.7%) had an elevated ALT serum activity, whereas no child had an elevated GGT activity. Pathological changes of liver in ultrasound (mainly enlargement or steatosis of the organ) were found in 12 patients (8.1%), of whom 5 children (3.4%) had simultaneously elevated ALT serum activity. Children with liver pathology had lower iron (Fe) ($p = 0.02$) and folic acid ($p = 0.01$) concentrations compared to the rest of the patients. There were no statistically significant differences between liver pathology existence and age, sex, serum immunoglobulin A anti-tissue transglutaminase type 2 antibodies (IgA anti-TG2), ferritin, vitamin B12, or vitamin D concentrations. Moreover, a positive correlation between IgA anti-TG2 concentration and ALT serum activity was found ($p < 0.01$, $R = 0.29$).

Conclusions: Liver pathology is present at diagnosis in a significant proportion of children with CD in the form of hypertransaminasemia and pathological changes of the organ in ultrasound. There is a correlation between IgA anti-TG2 concentration and ALT serum activity.

Key words: celiac disease, liver pathology, hypertransaminasemia, children.

Address for correspondence

Kamila Agnieszka Kwiatek-Średzińska, Department of Pediatrics, Gastroenterology, Hepatology, Nutrition and Allergology, Medical University of Białystok, 17 Jerzego Waszyngtona St., 15-274 Białystok, Poland, e-mail: kamila.kwiatek90@gmail.com

Introduction

Celiac disease (CD) is an immune-mediated systemic disorder elicited by gluten and related prolamines in genetically susceptible individuals and characterized by the presence of a variable combination of gluten-dependent clinical manifestations, CD-specific antibodies, HLA-DQ2 or HLA-DQ8 haplotypes, and enteropathy. Classical CD is characterized by chronic diarrhea, recurrent abdominal pain and failure to thrive. However, some patients also suffer from extraintestinal symptoms involving liver abnormalities [1].

The hepatic dysfunction in CD ranges from asymptomatic liver enzyme elevations or nonspecific hepatitis to chronic liver disease. The majority of studies determine the percentage of patients with hypertransaminasemia or the association between CD and liver diseases, but they do not estimate other pathological hepatic changes [2-4].

The primary aim of the study was to evaluate the prevalence and the type of liver pathology in children with newly diagnosed celiac disease. The secondary aim was to assess whether liver pathology is associated with determined demographic features or biochemical blood tests.

Material and methods

The retrospective study included 149 children hospitalized in the university hospital with newly diagnosed CD. Celiac disease was diagnosed on the basis of ESPGHAN guidelines [1]. Patients who had pre-existing liver disease were excluded. Demographic data at the time of diagnosis were obtained. In addition, ultrasound and some biochemical tests from blood (alanine transaminase [ALT], gamma-glutamyl transpeptidase [GGT], iron [Fe], ferritin, vitamin D, vitamin B12, and folic acid) were analyzed.

Liver pathology was defined as elevated ALT and/or GGT serum activity and/or pathological changes of the organ in ultrasound.

The Mann-Whitney *U* test was used to compare age, immunoglobulin A anti-tissue transglutaminase type 2 antibodies (IgA anti-TG2), ferritin, vitamin D, vitamin B12 and folic acid concentrations. Student's *t* test was performed to compare Fe concentration. The chi-square test was used to compare sex. Spearman's rank correlation coefficient was used to measure statistical dependence between IgA anti-TG2 concentration and ALT activity. A *p* value < 0.05 was considered statistically significant. Statistical analyses were performed using Statistica (StatSoft, Cracow, Poland).

Results

One hundred forty-nine patients were enrolled in the study (mean age 8 years, 90 girls and 59 boys). Liver pathology was detected in 17 of 149 children

Table 1. Characteristics of patients with and without liver pathology

Parameter	Patients with liver pathology (n = 17)	Patients without liver pathology (n = 132)	<i>p</i>
Age, mean ±SD	7.6 ±4.2	8.2 ±4.2	NS
Sex, no. of female (%)	9 (53)	81 (61)	NS
IgA anti-TG2 (U/ml), mean ±SD	114 ±135	79 ±96	NS
Fe (µg/dl), mean ±SD	51 ±27	74 ±35	0.02
Ferritin (ng/ml), mean ±SD	73 ±208	37 ±59	NS
Folic acid (ng/ml), mean ±SD	6 ±4	10 ±4	0.01
Vitamin B12 (pg/ml), mean ±SD	367 ±239	446 ±211	NS
Vitamin D (ng/ml), mean ±SD	15 ±11	22 ±11	NS

NS – non-significant

(11.4%). Ten patients (6.7%) had elevated ALT serum activity, whereas no child had elevated GGT activity. Pathological changes of liver in ultrasound (mainly enlargement or steatosis of the organ) were found in 12 patients (8.1%), of whom 5 children (3.4%) had simultaneously elevated ALT serum activity.

Demographic and biochemical characteristics of the patients with and without liver pathology are listed in Table 1. Children with liver pathology had lower Fe and folic acid concentrations compared to the rest of the patients. There were no statistically significant differences between liver pathology existence and age, sex, IgA anti-TG2, ferritin, vitamin B12, or vitamin D concentrations in blood. Moreover, a positive correlation between IgA anti-TG2 concentration and ALT serum activity was found ($p < 0.01$, $R = 0.29$) (Fig. 1).

Discussion

Although CD primarily affects the gut, the clinical manifestations of the disease are wide, with many extraintestinal systems and organs, including the liver [5, 6]. The hepatic dysfunction presenting in CD ranges from asymptomatic liver enzyme elevations or nonspecific hepatitis (cryptogenic liver disorders), to chronic liver disease [2]. There is growing evidence that a largely silent chronic liver abnormality, “cryptogenic-elevated transaminases”, is frequently associated with untreated celiac disease in both children and adult patients [7]. Liver changes in patients with CD have been reported since 1977 by Hagander *et al.* [8], who found that 40% of adults with incipient CD had increased serum activities of transaminases, which returned to normal upon a gluten-free diet (GFD) in the majority of patients [2]. One year later, Lindberg *et al.* [9] reported elevation of serum aminotransferases in about one-third of pediatric patients with CD [2].

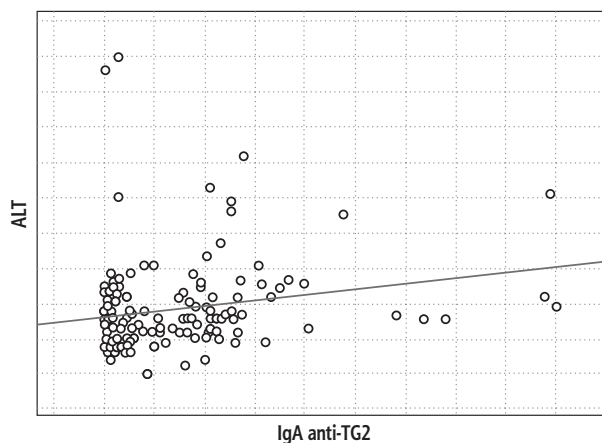


Fig. 1. Correlation between serum IgA anti-TG2 concentration and ALT activity

The majority of studies assess the prevalence of hypertransaminasemia in CD or the association between CD and liver diseases, but they do not evaluate other pathological changes in patients with newly diagnosed CD (for instance in ultrasound images). The primary aim of the present study was to determine the percentage of children with CD with liver pathology at the time of diagnosis. The results showed liver abnormalities in 11.4% of patients, including 6.7% with an elevated ALT serum activity. This is lower than reported mostly in other studies (9.2% to 47.7%) [3, 4, 10-14]. The reason may be that in other centers transaminases were inconsistently obtained at diagnosis of CD, mainly in symptomatic patients [14], while in our center ALT is part of basic laboratory blood tests.

The pathogenesis of the hypertransaminasemia and liver damage in CD remains poorly understood. Probably they involve increased intestinal permeability and alterations in gut microbiota, chronic intestinal inflammation, and genetic predisposition [2]. Most pediatric and adult patients normalize their liver enzymes within 1 year on treatment (GFD) [4, 10-14]. Liver tests (especially transaminases) should be routinely checked in all patients with CD at diagnosis [15, 16]. The presence of normal physical examination and hypertransaminasemia < 5 times the upper limit of normal (especially if the ratio of AST to ALT is < 1) strongly suggests celiac hepatitis and no further evaluation to exclude other causes of liver injury is necessary [15, 16]. Liver enzymes should be re-checked after 6-12 months of a strict GFD [15, 16]. If the transaminases normalize on the GFD, yearly follow-up is recommended [4, 16]. The patient will require extended investigation for a concurrent liver disease including specific laboratory and imaging studies (also consider a liver biopsy) if: a) persistent hypertransaminasemia after 1 year on strict adherence to a GFD, and b) transaminases activities > 5 times upper limit of normal, physical signs that suggest chronic liver disorder, and/or AST to ALT ratio > 1 [16].

The secondary aim of the study was to evaluate whether liver pathology in CD is associated with determined selected demographic features and biochemical blood tests. The results revealed that pediatric patients with liver pathology had significantly lower Fe and folic acid concentrations. Increasing evidence suggests that altered methionine/folate metabolism may contribute to the development of hepatic injury [17]. It was observed that low serum folic acid concentrations and hyperhomocysteinemia were significantly associated with higher serum ALT activities [18] or liver damage – steatohepatitis [19]. In addition, our results showed a positive correlation between IgA anti-TG2 concentration

and ALT serum activity. The association between liver pathology in CD and demographic features or biochemical blood tests requires further studies.

Limitations of the study are mainly related to the retrospective character of the design. Biochemical tests from blood (Fe, ferritin, vitamin D, vitamin B12, folic acid) were not obtained from every patient. Children who did not have these laboratory parameters assayed were not taken into consideration in the statistical analysis.

In summary, liver pathology is present at the time of diagnosis in an important proportion of children with CD. It can be manifested as hypertransaminasemia and pathological changes of the organ in ultrasound. Patients with liver pathology had lower Fe and folic acid serum concentration compared to the rest of the children. Furthermore, a dependence between IgA anti-TG2 concentration and ALT serum activity was found. No additional specific demographic features or biochemical blood tests associated with liver abnormalities were identified. Therefore, screening for liver pathology in children with newly diagnosed CD and for CD in patients with unexplained hypertransaminasemia is a reasonable practice.

Conclusions

Liver pathology is present at diagnosis in a significant proportion of children with CD in the form of hypertransaminasemia and pathological changes of the organ in ultrasound. Patients with liver pathology had lower Fe and folic acid serum concentration compared to the rest of the children. There is a correlation between IgA anti-TG2 concentration and ALT serum activity.

Disclosure

Authors report no conflict of interest.

References

1. Husby S, Koletzko S, Korponay-Szabo IR, et al. European Society for Pediatric Gastroenterology, Hepatology, and Nutrition guidelines for the diagnosis of coeliac disease. *J Pediatr Gastroenterol Nutr* 2012; 54: 136-160.
2. Anania C, De Luca E, De Castro G, et al. Liver involvement in pediatric celiac disease. *World J Gastroenterol* 2015; 21: 5813-5822.
3. Bukowski JS, Mazan A, Mitrowski M, et al. Assessment of hypertransaminasaemia in children with newly diagnosed coeliac disease. *Pediatr Pol* 2018; 93: 139-143.
4. Lee GJ, Boyle B, Ediger T, et al. Hypertransaminasemia in newly diagnosed pediatric patients with celiac disease. *J Pediatr Gastroenterol Nutr* 2016; 63: 340-343.
5. Farrell RJ, Kelly CP. Celiac sprue. *N Engl J Med* 2002; 346: 180-188.

6. Jericho H, Sansotta N, Guandalini S. Extranitestinal manifestations of celiac disease: effectiveness of the gluten-free diet. *J Pediatr Gastroenterol Nutr* 2017; 65: 75-79.
7. Duggan JM, Duggan AE. Systematic review: the liver in coeliac disease. *Aliment Pharmacol Ther* 2005; 21: 515-518.
8. Hagander B, Berg NO, Brandt L, et al. Hepatic injury in adult coeliac disease. *Lancet* 1977; 2: 270-272.
9. Lindberg T, Berg NO, Borulf S, et al. Liver damage in coeliac disease or other food intolerance in childhood. *Lancet* 1978; 1: 390-391.
10. Farre C, Esteve M, Curcoy A, et al. Hypertransaminasemia in pediatric celiac disease patients and its prevalence as a diagnostic clue. *Am J Gastroenterol* 2002; 97: 3176-3181.
11. Arslan N, Büyükgebiz B, Oztürk Y, et al. The prevalence of liver function abnormalities in pediatric celiac disease patients and its relation with intestinal biopsy findings. *Acta Gastroenterol Belg* 2005; 68: 424-427.
12. Di Biase AR, Colecchia A, Scaiola E, et al. Autoimmune liver diseases in a paediatric population with coeliac disease – a 10-year single-center experience. *Aliment Pharmacol Ther* 2010; 31: 253-260.
13. Korpimäki S, Kaukinen K, Collin P, et al. Gluten-sensitive hypertransaminasemia in celiac disease: an infrequent and often subclinical finding. *Am J Gastroenterol* 2011; 106: 1689-1696.
14. Alavi Moghaddam M, Rostami Nejad M, Shalmani HM, et al. The effects of gluten-free diet on hipertransaminasemia in patients with celiac disease. *Int J Prev Med* 2013; 4: 700-704.
15. Rubio-Tapia A, Murray JA. The liver in celiac disease. *Hepatology* 2007; 46: 1650-1658.
16. Rubio-Tapia A, Murray JA. Liver involvement in celiac disease. *Minerva Med* 2008; 99: 595-604.
17. Qin X, Li J, Cui Y, et al. Effect of folic acid intervention on ALT concentration in hypertensives without known hepatic disease: a randomized, double-blind, controlled trial. *Eur J Clin Nutr* 2012; 66: 541-548.
18. Welzel TM, Katki HA, Sakoda LC, et al. Blood folate levels and risk of liver damage and hepatocellular carcinoma in a prospective high-risk cohort. *Cancer Epidemiol Biomarkers Prev* 2007; 16: 1279-1282.
19. Gulsen M, Yesilova Z, Bagci S, et al. Elevated plasma homocysteine concentrations as a predictor of steatohepatitis in patients with non-alcoholic fatty liver disease. *J Gastroenterol Hepatol* 2005; 20: 1448-1455.