

CASE REPORT/OPIS PRZYPADKU

Two types of hypersensitivity reaction including anaphylaxis and symmetrical drug-related intertriginous and flexural exanthema (SDRIFE) after aminopenicillin administration in the same patient

Dwa typy reakcji nadwrażliwości: anafilaksja oraz symetryczna, wyprzeniowa i zgięciowa osutka wywołana lekiem (SDRIFE), które wystąpiły u pacjenta po zażyciu aminopenicyliny

Lesia Rozłucka, Radosław Gawlik, Joanna Glück

Department of Internal Medicine, Allergology and Clinical Immunology, Medical University of Silesia, Katowice, Poland

ABSTRACT

We present a rare case of a patient who experienced both immediate and delayed types of drug hypersensitivity reaction (DHR) to aminopenicillin with good tolerance of another β -lactam. A 56-year-old female patient reported allergic reactions to several antibiotics. After the co-administration of nonsteroidal anti-inflammatory drugs (NSAIDs) and amoxicillin/clavulanic acid the patient presented with anaphylactic shock. At the same time, the patient reported good amoxicillin tolerance. During hospitalization, DHR to NSAIDs was excluded by oral provocation. Due to the unclear history of β -lactam allergy, after negative skin test results, an oral provocation test with amoxicillin was performed. Four hours after the administration of the last dose, the patient developed symmetrical drug-related intertriginous and flexural exanthema (SDRIFE) with temperature increase to 38.5°C. Laboratory tests showed increased inflammatory parameters. After treatment with dexamethasone, paracetamol and bilastine, a gradual regression of skin rash and normalization of inflammatory parameters were observed. Further work-up confirmed good tolerance of cefuroxime axetil.

KEY WORDS

anaphylaxis, SDRIFE, drug hypersensitivity, aminopenicillin allergy, β -lactam allergy.

ADDRESS FOR CORRESPONDENCE

Lesia Rozłucka, Department of Internal Medicine, Allergology and Clinical Immunology, Medical University of Silesia, Katowice, Poland, e-mail: lesia.rozlucka@gmail.com

INTRODUCTION

Even though the prevalence of patients labeled with penicillin allergy is estimated at 8–25%, after the complete allergological work-up, the percentage of the real penicillin allergy is established at < 5% [1]. Penicillin allergy most often occurs as type I immediate reactions, such as anaphylaxis and type IV-delayed reactions. Symmetrical drug-related intertriginous and flexural exanthema (SDRIFE), previously known as baboon-syndrome, is a rare manifestation of type IV hypersensitivity reaction [2].

We present, a rare case of a patient who experienced both immediate and delayed types of drug hypersensi-

tivity reaction to aminopenicillin with good tolerance of another β -lactam.

CASE REPORT

A 56-year-old female patient was admitted to the Allergy and Clinical Immunology Department due to drug allergy. The patient reported allergic reactions to several antibiotics including ampicillin and neomycin in childhood and spiramycin in 2017. In 2018, after the co-administration of nonsteroidal anti-inflammatory drugs (NSAIDs) and amoxicillin/clavulanic acid (*Augmentin*), the patient presented with anaphylactic shock

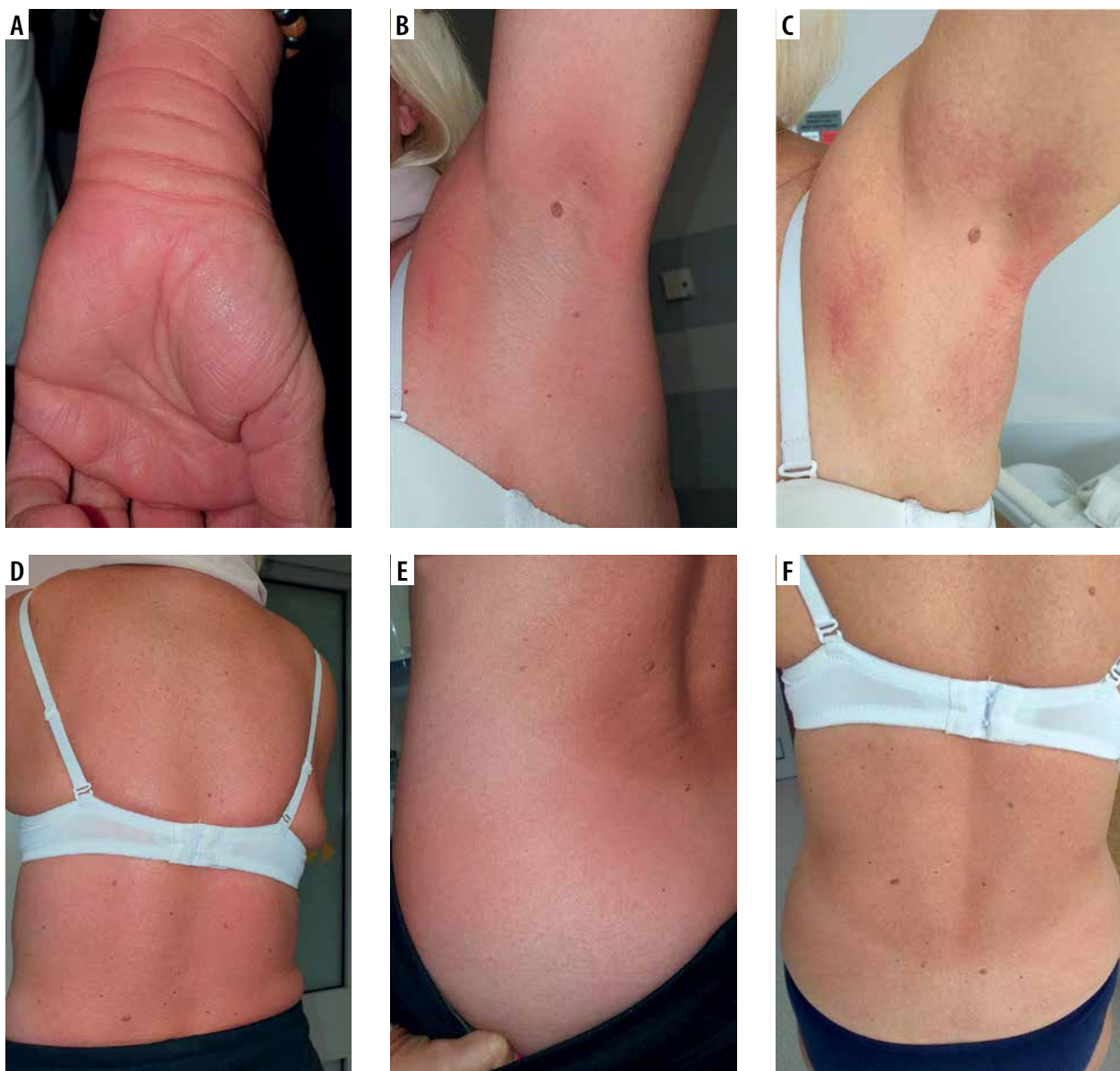


FIGURE 1. Symmetrical erythematous rash after oral provocation with amoxicillin located on the forearm (A), armpits before treatment (B), armpits during treatment (C), back before treatment (D), back during treatment (E, F)

with massive urticaria and loss of consciousness. On the other hand, she reported good amoxicillin (*Duomox*) tolerance. Upon admission, physical examination and laboratory parameters were within the normal range. Drug hypersensitivity reaction (DHR) to NSAIDs was excluded by oral provocation tests with celecoxib and acetylsalicylic acid. Due to the unclear history of β -lactam allergy, after negative skin test results, a direct oral provocation test with amoxicillin (up to 1000 mg) was performed. Four hours after the administration of the last dose, the patient developed symmetrical erythematous rash located on her trunk, limbs, armpits, and groins, along with temperature increase to 38.5°C. Laboratory tests showed increased inflammatory parameters: C-reactive protein increased from 3.4 mg/l to 53.8 mg/l (reference range < 5 mg/l), leukocyte count increased from $6.24 \times 10^3/\mu\text{l}$ to $13.99 \times 10^3/\mu\text{l}$ (reference range 4.0–10.0 $10^3/\mu\text{l}$), and neutrophil count increased from $3.61 \times 10^3/\mu\text{l}$ to $12.98 \times 10^3/\mu\text{l}$ (reference range 2.5–5.0 $10^3/\mu\text{l}$). Specific IgE (ImmunoCAP, Thermo-Fisher Scientific) to β -lactams including amoxicillin, ampicillin, penicillin G, penicillin V and cefaclor were negative (< 0.35 kU/l). After treatment with 8 mg of dexamethasone intravenously, 1000 mg of paracetamol and 80 mg of bilastine, a grad-

ual regression of skin rash (Figure 1) and normalization of inflammatory parameters were observed (Figure 2).

The patient was discharged home with the recommendation to continue oral and topical corticosteroid treatment. Further work-up with prick, intradermal skin tests and oral provocation test up to 500 mg, confirmed good tolerance of cefuroxime axetil.

DISCUSSION

Since 1984 over 100 cases of SDRIFE have been described [3]. SDRIFE may include both a type IV-a reaction involving CD4+ Th1 cells, macrophages, and a type of IV-c reaction with CD4 and CD8 T cells involvement [4]. Häusermann *et al.* proposed 5 criteria for SDRIFE diagnosis (Table 1) [5]. Our patient fulfilled 4 of 5 criteria. SDRIFE differential diagnosis should include other drug hypersensitivity reactions, such as acute generalized exanthematous pustulosis (AGEP), fixed drug eruption (FDE) and drug reaction with eosinophilia and systemic symptoms (DRESS). Clinical course of AGEP and DRESS is more severe with systemic symptoms and in case of DRESS with internal organ involvement such as hepatitis, nephritis, and lymphadenopathy. Asymmetrical localization of skin lesions with the late symptom onset

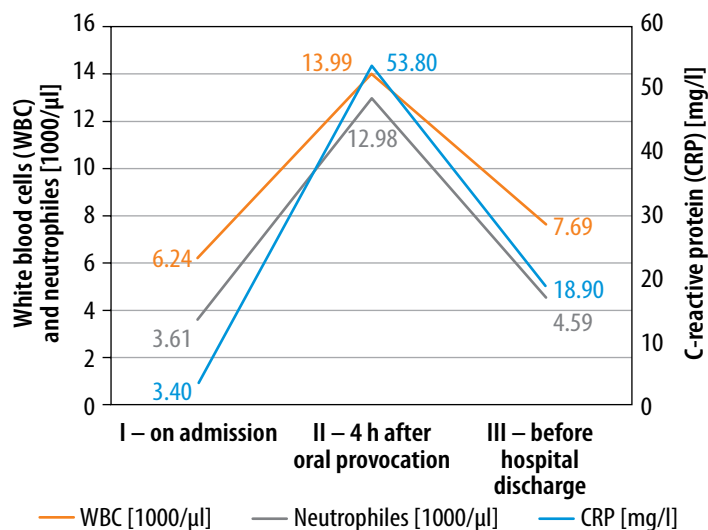


FIGURE 2. Inflammatory parameter change during the hospitalization

TABLE 1. Criteria proposed by Häusermann *et al.* for SDRIFE diagnosis [5]

1.	Exposure to a systemically administered drug, first or repeated doses (contact allergens excluded)
2.	Sharply demarcated erythema of the gluteal/perianal area and/or V-shaped erythema of the inguinal/perigenital area
3.	Involvement of at least one other intertriginous/flexural fold
4.	Symmetry of affected areas
5.	Absence of systemic symptoms and signs

(1–2 weeks after drug exposure) is more typical for FDE [5]. In the described case because of atypical symptoms such as fever and increased inflammatory parameters, differential diagnosis was required. The time of symptom onset, mild course of the disease and rapid skin symptoms regression after the treatment pointed to SDRIFE as a final diagnosis.

Clinically significant β -lactams DHR mainly occur due to side chain similarity, not to β -lactam ring sensitization [6, 7]. Despite the fact that cross-reactivity between penicillins and cephalosporins is very low, avoidance of cephalosporins in patients with penicillin allergy is still common [8]. Therefore, an allergy work-up in patients with confirmed aminopenicillin allergy should include cephalosporin testing as well.

CONFLICT OF INTEREST

The authors declare no conflict of interest.

REFERENCES

1. Stone CA Jr, Trubiano J, Coleman DT, et al. The challenge of de-labeling penicillin allergy. *Allergy* 2020; 75: 273-88.
2. Harbaoui S, Litaïem N. Symmetrical Drug-related Intertriginous and Flexural Exanthema. In: StatPearls. Treasure Island (FL): StatPearls Publishing; October 9, 2021.
3. Huynh T, Hughey LC, McKay K, et al. Systemic drug-related intertriginous and flexural exanthema from radio contrast media: a series of 3 cases. *JAAD Case Rep* 2015; 1: 147-9.
4. Tan SC, Tan JW. Symmetrical drug-related intertriginous and flexural exanthema. *Curr Opin Allergy Clin Immunol* 2011; 11: 313-8.
5. Häusermann P, Harr T, Bircher AJ. Baboon syndrome resulting from systemic drugs: is there strife between SDRIFE and allergic contact dermatitis syndrome? *Contact Dermatitis* 2004; 51: 297-310.
6. Torres MJ, Blanca M. The complex clinical picture of beta-lactam hypersensitivity: penicillins, cephalosporins, monobactams, carbapenems, and clavams. *Med Clin North Am* 2010; 94: 805-xii.
7. Chaudhry SB, Veve MB, Wagner JL. Cephalosporins: a focus on side chains and β -lactam cross-reactivity. *Pharmacy (Basel)* 2019; 7: 103.
8. Macy E, Blumenthal KG. Are cephalosporins safe for use in penicillin allergy without prior allergy evaluation? *J Allergy Clin Immunol Pract* 2018; 6: 82-9.