

(13)

Recurrence Rate and Corneal Astigmatism after 'Sliding Flap' Technique with Intraoperative Application of 0.05% Mitomycin C or 20% Ethanol for Pterygium Surgery

Częstość nawrotów oraz astygmatyzm rogówkowy po zabiegu usunięcia skrzydlika z przesunięciem płatk spojówki i śródoperacyjnym zastosowaniem 0,05% mitomycyny C lub 20% etanolu

Barbara Nowacka, Wojciech Lubiński

Department of Ophthalmology, Pomeranian Medical University, Szczecin, Poland
Head: Professor Wojciech Lubiński MD, PhD

Abstract:

Objectives: The aim of the study was to evaluate changes in corneal astigmatism and recurrence rates of two variants of 'sliding flap' techniques – with intraoperative use of 0.05% mitomycin C or 20% ethyl alcohol which could be an option for other pterygium surgeries.

Material and Methods: Fifty eyes from 45 patients with primary pterygia were included. All patients underwent the 'sliding flap' surgery performed by a single surgeon with adjunctive intraoperative 0.05% mitomycin C (group MMC–27 eyes) or 20% ethyl alcohol (group ALC–23 eyes) therapy. Follow-up visits were at months 1, 3, 6 and 12. Patients were examined in the slit lamp for pterygium recurrence defined as any fibrovascular growth of conjunctival tissue extending across the limbus. Moreover, before and 12 months after surgery keratometry was performed in order to estimate corneal astigmatism (only in eyes without pterygium recurrence).

Results: During 12 months of follow-up, only two recurrences (7.4%) were observed in the MMC group and 3 (13.0%) in the ALC group. In both groups, there was a visible but statistically insignificant reduction in corneal astigmatism compared to the preoperative measurement (before the surgery > MMC group: 1.2 ± 0.8 Dcyl, ALC group 1.3 ± 1.3 Dcyl, 12 months postoperatively > MMC group: 0.9 ± 0.7 Dcyl, 0.8 ± 0.6 Dcyl, respectively).

Conclusions: The 'sliding flap' techniques combined with intraoperative 0.05% MMC or 20% ethanol application are equally effective surgical alternatives for preventing recurrence of primary pterygium. The procedures are simple with a satisfactory cosmetic effect and lack of major complications.

Key words:

pterygium, sliding flap technique, Mitomycin C, ethyl alcohol, astigmatic changes.

Abstrakt:

Cel pracy: Celem pracy była ocena częstości nawrotów oraz zmian astygmatyzmu rogówkowego dwóch wariantów operacji usunięcia skrzydlika z przesunięciem płatk spojówki – ze śródoperacyjnym zastosowaniem 0,05% mitomycyny lub 20% alkoholu etylowego, które mogą stanowić alternatywę dla innych technik.

Material i metody: Do badania zakwalifikowano 50 oczu z pierwotnym skrzydlikiem od 45 pacjentów. U wszystkich pacjentów wykonano operację usunięcia skrzydlika z przesunięciem płatk spojówki oraz śródoperacyjnym zastosowaniem 0,05% mitomycyny C (grupa MMC – 27 oczu) lub 20% alkoholu etylowego (grupa ALC – 23 oczu). Zabiegi były wykonywane przez jednego operatora. Wizyty kontrolne miały miejsce w 1, 3, 6 i 12 miesiącu po zabiegu. Pacjentów badano za pomocą lampy szczelinowej pod kątem nawrotu skrzydlika, który definiowano jako jakikolwiek rozwój tkanki włóknisto-naczyniowej przekraczający rąbek rogówki. Ponadto, przed i 12 miesięcy po zabiegu wykonano keratometrię w celu oceny astygmatyzmu rogówki (tylko w oczach bez nawrotów skrzydlika).

Wyniki: W ciągu 12 miesięcy zaobserwowano tylko dwa nawroty (7,4%) w grupie MMC i 3 (13,0%) w grupie ALC. W obu grupach była widoczna, ale statystycznie nieistotna redukcja astygmatyzmu rogówki w porównaniu z przedoperacyjnym pomiarem (przed operacją > grupa MMC: $1,2 \pm 0,8$ Dcyl, grupa ALC $1,3 \pm 1,3$ Dcyl, 12 miesięcy po zabiegu > grupa MMC: $0,9 \pm 0,7$ Dcyl, $0,8 \pm 0,6$ Dcyl).

Wnioski: Techniki usunięcia skrzydlika z przesunięciem płatk spojówki oraz śródoperacyjnym zastosowaniem 0,05% mitomycyny lub 20% etanolu etylowego są równie skutecznymi chirurgicznymi metodami zapobiegania nawrotom skrzydlika, jak inne szeroko stosowane zabiegi. Procedury są proste, z satysfakcjonującym efektem kosmetycznym i brakiem poważnych komplikacji.

Słowa kluczowe:

skrzydlik, technika przesunięcia płatk, mitomycyna C, alkohol etylowy, zmiany astygmatyzmu.

The authors declare no conflict of interest/ Autorzy zgłaszają brak konfliktu interesów w związku z publikowaną pracą

Introduction

Pterygium is a wing-shaped growth of fibrovascular conjunctival tissue onto the cornea, which is not only a cosmetic nuisance, but also may affect vision and cause chronic discomfort due to tear film disturbances. The main method of pterygium treatment is surgical excision (1). The major problem of pterygium surgery is the prevention of recurrences. Although there is no standard definition of recurrence, it is generally accepted that it may be diagnosed when fibrovascular growth of conjunctival tissue crosses the limbus onto the cornea in the area of excised pterygium. The percentage of recurrences after surgery varies from 2% to even 60–88%, depending on surgical technique, type of pterygium, age of the patient and environmental factors (2). At least 97% of all recurrent pterygia manifest within a year after excision – mostly during first 6 months (3, 4).

There are many techniques of covering the pterygium excisional site – simple closure, sliding and rotational flaps, free (CAG) or limbal conjunctival autografts (CLAG), and lamellar corneal transplant or amniotic membrane graft (5). Moreover, various adjunctive therapies might be used to reduce pterygium recurrence risk. These include intraoperative application of mitomycin C (MMC) and the use of alcohol on the cornea prior to pterygium surgical excision (6, 7). A large number of procedures indicate that there is no clear-cut superior single treatment. Therefore, there is a need to continue the search for the best method that combines low recurrence rates with a short procedure and relatively low cost. According to our best knowledge, in available literature there is no research investigating the recurrence rate and changes in corneal astigmatism after pterygium excision by the 'sliding flap' technique with adjunctive intraoperative MMC or ethanol therapy. That is why our study is an interesting point in pterygium surgery discussion.

Aim

The aim of the study was to evaluate changes in corneal astigmatism and recurrence rates of two variants of 'sliding flap' techniques – with intraoperative use of 0.05% mitomycin or 20% ethyl alcohol which could be an option for other pterygium surgeries.

Subjects and Methods

A consecutive case series study. The surgical techniques used in the study were part of standard care provided in our clinic. Fifty eyes from 45 patients with primary pterygia were included. Before surgery, the pterygium size was determined using S1-S3 scale, where stage 1 (S1) was defined as pterygium head infiltration up to one fourth of corneal diameter, S2 – more than one fourth but less than half, and S3 was pterygium head crossing the center of the cornea. All patients underwent sliding flap surgery performed by a single surgeon with adjunctive intraoperative 0.05% mitomycin C (group MMC – 27 eyes) or 20% ethyl alcohol (group ALC – 23 eyes) therapy. Qualification for adjunctive therapy was random and depended on its availability on a given day. In all eyes the surgical technique has begun with a subconjunctival anesthetic injection of 0.2 ml 0.5% bupivacaine hydrochloride + 0.005% epinephrine under the pterygium body followed by the undermining and dissection of the pterygium neck and body. Then in the MMC group the pterygium head was teared off the cornea and ptery-

gium tissue remnants were gently scraped off with the surgical blade. Mitomycin C at a concentration of 0.05% was administered on the sponge scrap placed on bare sclera for 1 minute (Figure 1) and then washed out with 10 ml of normal saline. In the ALC group, before pterygium removal, a LASIK ring was placed over the pterygium head and topical 20% ethyl alcohol was administered into the ring for one minute (Figure 2). After this time, alcohol was cleared out with the sponge and the pterygium head was removed with the adjacent corneal epithelium. Next in both groups, a L-shaped incision and preparation of the flap was made from the upper conjunctiva. Then, the flap was transposed downwards with a rotation at the angle of 90 degrees to reverse the conjunctival vessels running from perpendicular to parallel to the cornea. That was our modification of the 'standard sliding flap' technique. The non-absorbable sutures 7/0 fixed the flap above the bare scleral bed (Figure 3). After surgery, antibiotic ointment (ofloxacinum, Floxal) was applied into the eye, and the eye patch was placed and maintain until the morning of the next day in order to prevent wound disruption due to excessive tension. Postoperatively, patients were treated with combined 0.3% tobramycin / 0.1% dexamethasone eye drops (Tobradex) and 0.05% dexpanthenol gel (Corneregel) 4 times daily for 4 weeks. Subsequently, patients were advised to use moisturizing eye drops with an UV filter and to wear sunglasses on

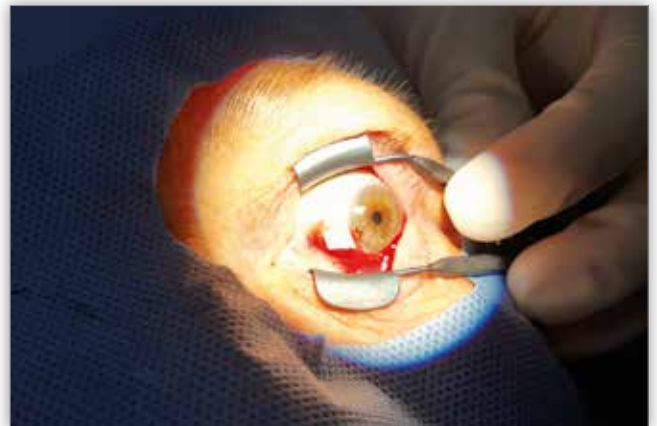

Fig. 1. Topical 0.05% mitomycin C administered on the sponge scrap placed on bare sclera.

Ryc. 1. Sposób aplikacji 0.05% mitomycyny C na odsłoniętą twardówkę.

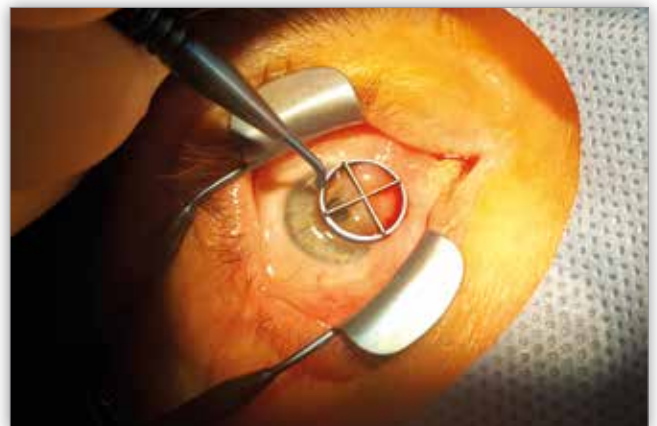


Fig. 2. LASIK ring placed over the pterygium head and filled topical 20% ethyl alcohol.

Ryc. 2. Pierścień do LASIK umieszczony na głowie skrzydlika i wypełniony 20% alkoholem etylowym.

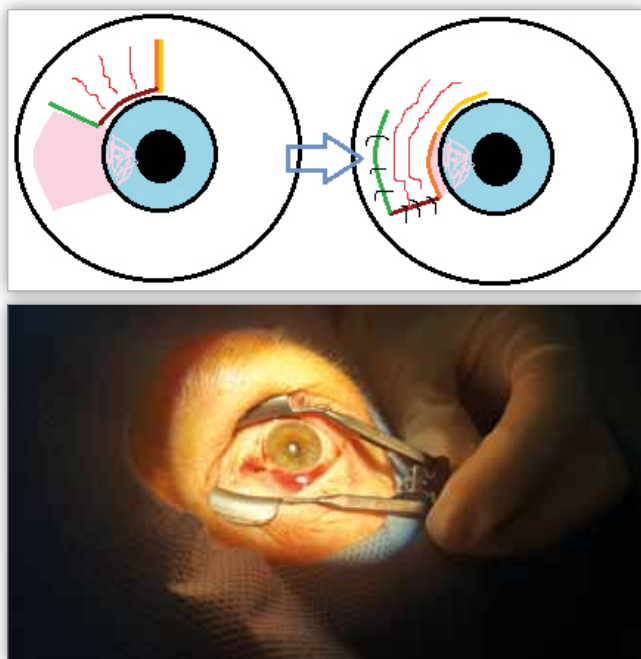


Fig. 3. Conjunctival appearance after „sliding flap” surgery.

Ryc. 3. Wygląd spojówki bezpośrednio po operacji techniką przesunięcia płatką spojówki.

sunny days. Sutures were removed 10 days after surgery. Follow-up visits were at months 1, 3, 6 and 12. Patients were examined in the slit lamp for pterygium recurrence defined as any fibrovascular growth of conjunctival tissue extending across the limbus. Moreover, before and 12 months after surgery keratometry was performed in order to estimate corneal astigmatism (only in eyes without pterygium recurrence). The non-parametric Mann-Whitney U test was used for comparisons between recurrence rates and changes in corneal astigmatism.

A p-value <0.05 was considered significant.

Results

All conjunctival flaps healed without significant (more than 1 mm) wound disruption resulted from retraction. No case of postoperative complications were observed. All patients self-administered combined 0.3% tobramycin and 0.1% dexamethasone eye drops (Tobradex) and dexpanthenol gel (Corneregel) 4 times daily for 4 weeks. However, compliance to later recommendations for eye moisturizing and wearing sunglasses was at a level of 50% in both groups. In the MMC group, 14 pterygia were classified as S1 (51.9%), 9 as S2 (33.3%) and 4 as S3 (14.8%), respectively. During 12 months follow-up, only two recurrences (7.4%) were observed at the 3rd and 6th month after pterygium excision. Before surgery, the mean corneal astigmatism was equal 1.2 ± 0.8 Dcyl and there was a visible reduction to 0.9 ± 0.7 Dcyl in the 12th month of follow-up. However, this difference turned out to be statistically insignificant ($p > 0.05$). In the ALC group, 14 pterygia were classified as S1 (60.9%), 8 as S2 (34.8%) and 1 as S3 (4.3%). The recurrences were 3 (13.0%) and they were observed at the 1st, 3rd and 6th month of 12-month follow-up. Although less recurrences were observed in the MMC group, the difference between investigated groups' recurrence rate turned out to be statistically insignificant ($p > 0.05$). The reduction of corneal astigmatism from

1.3 ± 1.3 Dcyl before surgery to 0.8 ± 0.6 Dcyl at 12th month of follow-up in the ALC group was statistically insignificant ($p > 0.05$). At the final follow-up, all eyes without recurrence had good cosmetic effect and the conjunctiva was less injected in comparison with the condition before the operation. The example of the eye appearance before and 12 months after the surgery is presented in Figure 4.

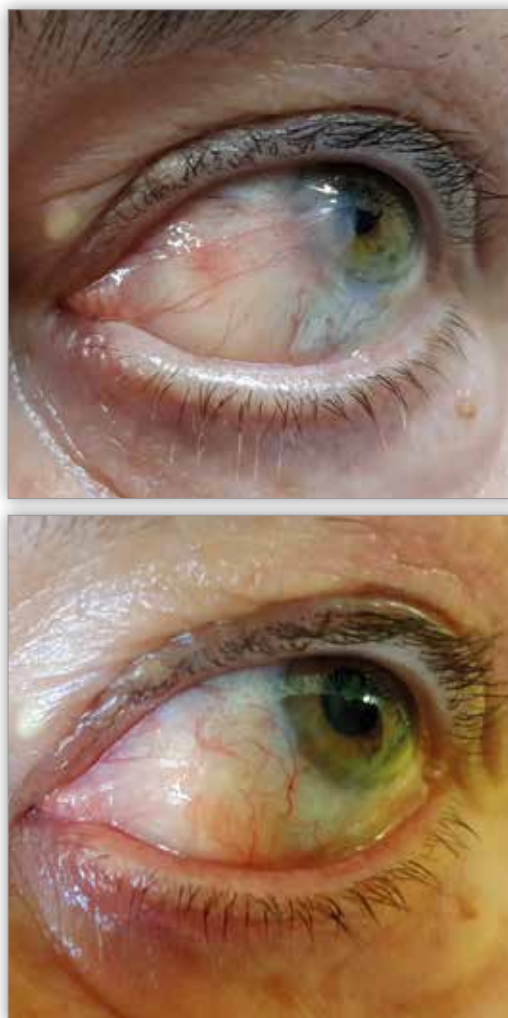


Fig. 4. The eye appearance before and 12 months after the “sliding flap” surgery.

Ryc. 4. Wygląd oka przed i po 12 miesiącach po usunięciu skrzydlika techniką przesunięcia płatką spojówki.

Discussion

Various attempts have been made to lower the recurrence rate after pterygium surgery. However, there is still no agreement on the best method of excision. The bare sclera or simple closure technique seem to be no longer acceptable due to high recurrence rates. Covering the bare sclera by autologous conjunctival tissue by using a sliding / rotational flap or free autograft is recommended. These procedures are not much time consuming and technically demanding when performed by a trained surgeon. The amount of research evaluating recurrences after 'sliding flap' techniques is small. McCoombes et al. (8) investigated a large group of 258 eyes for at least 1 year follow-up and reported pterygium recurrence only in 3.2%. However, despite the same name, the operative technique described by the Authors signifi-

cantly differs from ours. In this procedure two temporally slanted parallel incisions directed to the superior fornix were made to create a conjunctival flap instead of one L-shaped incision. In the smaller study, Tomas et al. (9) observed 1 recurrence of 20 pterygia (5%). The follow-up was also at least 12 months. The recent study, Pak and Lee (10) reported a recurrence of 0.8% but there was a short-term observation (3 months follow-up). On the other hand, Alpay et al. (11) found that the conjunctival flap technique have a recurrence rate of as much as 33.3% within 3 months (5 primary / 1 recurred pterygium). Thus, we can conclude that in our study the recurrence rate was acceptable (7.4% in MMC group and 13.0% in ALC group). However, further observations of larger groups of patients are needed. Since surgery itself seems not to prevent the pterygium recurrence enough, various adjuvant treatments were implemented. The most popular MMC has already been shown to lower recurrence rates. Mitomycin C is a metabolic inhibitor of fibroblast proliferation of the episclera (12, 13). Its concentration for intraoperative use varies from 0.1 to 0.5 mg/dl (0.01–0.05%) and it may be applied directly on the bare sclera over 1 to 5 minutes (6, 11, 14–17). The most common concentration of intraoperatively used MMC is 0.02% and it is applied on a cellulose sponge directly to the bare scleral bed over 3 minutes (18). MMC use is limited, due to uncommon but severe side effects such as scleral necrosis leading to perforation, infectious scleritis, uveitis and endophthalmitis (19, 20). That is why we decided to use a higher MMC concentration of 0.05% but reduced the time of application to 1 minute in order to prevent potential complications. Depending on the excision technique reported recurrence rates for intraoperative use of MMC range from 0% to 43% (6, 11, 14, 16, 17, 21–24). When bare sclera or simple closure techniques are used, the highest recurrence rates of 16–38% were observed (6, 11, 14, 16) whereas when combined with autografting it was equal to 0–13.3% (17, 23–25). According to our best knowledge in available literature there is no research investigating the recurrence rate after pterygium excision by the 'sliding flap' technique with adjuvant intraoperative MMC therapy. However, Khakshoor et al. (24) studied pterygium removal with 2-minute intraoperative application of 0.02% MMC and 'rotational flap', which is the most comparable with our study. The authors observed 4.3% recurrence rate which is not significantly different from our result of 7.4%. In the earlier study, Ucakhan and Kanpolat reported no recurrence in 43 eyes after one year of follow-up for the 'rotational flap' technique with 2-minute intraoperative 0.02% MMC application (26). Although this result seems to be much better than ours, statistical comparison of the data revealed no statistical significance ($p > 0.05\%$). Thus, we can conclude, that recurrence rate below 10% for conjunctival flap technique with MMC is acceptable and comparable with other reports. In available literature, there is only one study investigating the intraoperative use of 20% ethanol for pterygium surgery (7). The application of ethanol to the cornea is widely used in excimer laser refractory surgeries. In tissues, it causes a rapid denaturation of proteins/peptides including cytokines, enzymes and growth factors. Moreover, ethanol splits the basement membrane and destroys hemidesmosome junctions between corneal epithelial cells. Its use on the cornea and pterygium head prior to excision creates a smoother separation plane, and the pterygium head can be easily scrapped off from the underlying cornea, what

might cause better postoperative healing process (7). The use of ethanol might also have role in anti-scarring process. Unlike our study, Chen et al. applied 20% ethanol not only to the pterygium head, but also to the bare sclera bed for 60 seconds. The authors observed recurrence in 2 of 38 eyes (5.3%) which is not a statistically significantly better result than ours of 13.0% (2/23 eyes). However further research with higher numbers of patients may reveal significant differences.

Pterygium excision with CAG or CLAG is the method of choice for most surgeons. The results of recent studies indicate on 3–10% recurrence rate after CAG procedure (27–29) but it may range up to 30% (for recent review see 30). The limbal conjunctival autograft procedure seems to be a little more effective than CAG with recurrence rate varies between 0 and 15% (for recent review see 30) but this process requires more experience. Table 1 show obtained results in comparison to two most commonly performed pterygium excision procedures.

Procedure	SF+MMC	SF+ALC	CAG	CLAG
Recurrence rate	7.4%	13.0%	3-30%	0-15%

Tab. I. The comparison of the recurrence rate of sliding flap (SF) with mitomycin C (MMC) or ethyl alcohol (ALC), conjunctival autograft (CAG) and limbal conjunctival autograft (CLAG) procedures for pterygium surgery.

Tab. I. Porównanie częstości nawrotów po operacyjnym usunięciu skrzydlika z przesunięciem płata spojówki (SF) i mitomycyną C (MMC) lub alkoholem etylowym (ALC), autoprzyszczepem spojówki (CAG) oraz autoprzyszczepem spojówki i komórek rąbka (CLAG).

In both groups, there was a visible but statistically insignificant reduction of corneal astigmatism compared to the preoperative measurement (MMC group before the surgery: 1.2 ± 0.8 Dcyl, 12 months postoperatively: 0.9 ± 0.7 Dcyl; ALC group before the surgery: 1.3 ± 1.3 Dcyl, 12 months postoperatively: 0.8 ± 0.6 Dcyl). Previous studies' results indicate that after pterygium surgery there is a significant reduction of corneal astigmatism regardless of the surgical technique used (31–33). Up today, no research investigated corneal astigmatism after the 'sliding flap' technique with adjunctive MMC or ethanol. Moreover, in aforementioned reports the initial astigmatism was 2–3x higher than in our study. Low initial astigmatism and relatively small groups of investigated eyes may be a reason why our results did not achieve statistical significance. Nonetheless, the trend of astigmatism reduction was observed in both groups.

Conclusions

Our initial results indicate that the 'sliding flap' techniques combined with intraoperative 0.05% MMC or 20% ethanol application are equally effective surgical alternatives for preventing the recurrence of primary pterygium as other recommended methods. The procedures are simple, with satisfactory cosmetic effects and lack of major complications. Thus, we believe that they may be included in the group of recommended techniques of pterygium removal and the choice of technique would depend on the surgeon's preference. However, additional larger randomized clinical trials need to be performed in order to properly evaluate the efficacy of these treatment options.

References:

1. Mohammed I: *Treatment of pterygium*. Ann Afr Med 2011; 10: 197–203.
2. Janson BJ, Sikder S: *Surgical management of pterygium*. Ocul Surf 2014; 12: 112–119.
3. Hirst LW, Sebban A, Chant D: *Pterygium recurrence time*. Ophthalmology. 1994; 101: 755–758.
4. Kocamis O, Bilgec M: *Evaluation of the recurrence rate for pterygium treated with conjunctival autograft*. Graefes Arch Clin Exp Ophthalmol. 2014; 252: 817–820.
5. American Academy of Ophthalmology. Basic and Clinical Science Course 2011–2012, Section 8: External Disease and Cornea. LEO 2011; 332, 391–395.
6. Martins TG, Costa AL, Alves MR, Chammas R, Schor P: *Mitomycin C in pterygium treatment*. Int J Ophthalmol. 2016; 9: 465–468.
7. Chen KH, Hsu WM: *Intraoperative ethanol treatment as an adjuvant therapy of pterygium excision*. Int J Biomed Sci. 2006; 2: 414–421.
8. McCoombes JA, Hirst LW, Isbell GP: *Sliding conjunctival flap for the treatment of primary pterygium*. Ophthalmology. 1994; 101: 169–173.
9. Tomas T: *Sliding flap of conjunctival limbus to prevent recurrence of pterygium*. Refract Corneal Surg. 1992; 8: 394–395.
10. Pak KY, Lee J: *Short-Term Clinical Outcomes of Pterygium Treatment with Conjunctival Flap Advancement*. J Korean Ophthalmol Soc. 2012; 53: 1766–1771.
11. Alpay A, Uğurbaşı SH, Erdoğan B: *Comparing techniques for pterygium surgery*. Clin Ophthalmol. 2009; 3: 69–74.
12. Wakaki S, Marumo H, Tomioka K, Shimizu G, Kato E, Kamada H, Kudo S, Fujimoto Y: *Isolation of new fractions of antitumor mitomycins*. Antibiot Chemother (Northfield) 1958; 8: 228–240.
13. Chen CW, Huang HT, Bair JS, Lee C: *Trabeculectomy with simultaneous topical application of mitomycin-C in refractory glaucoma*. J Ocul Pharmacol. 1990; 6: 175–182.
14. Jiang J, Gong J, Li W, Hong C: *Comparison of intra-operative 0.02% mitomycin C and sutureless limbal conjunctival autograft fixation in pterygium surgery: five-year follow-up*. Acta Ophthalmol. 2015; 93: e568–572.
15. Manning CA, Kloess PM, Diaz MD, Yee R: *Intraoperative mitomycin in primary pterygium excision. A prospective, randomized trial*. Ophthalmology. 1997; 104: 844–848.
16. Paracha Q, Ayoob M, Dawood Z, Mirza SA: *Recurrence rate with use of intraoperative Mitomycin C versus Conjunctival Autograft following pterygium excision*. Pak J Med Sci. 2014; 30: 1243–1246.
17. Katircioglu YA, Altıparmak U, Engür Goktas S, Cakir B, Singar E, Ornek F: *Comparison of Two Techniques for the Treatment of Recurrent Pterygium: Amniotic Membrane vs Conjunctival Autograft Combined with Mitomycin C*. Semin Ophthalmol. 2015; 30: 321–327.
18. Ang LP, Chua JL, Tan DT. *Current concepts and techniques in pterygium treatment*. Curr Opin Ophthalmol. 2007; 18: 308–313.
19. Rubinfeld RS, Pfister RR, Stein RM, Foster CS, Martin NF, Stoleru S, et al.: *Speaker MG. Serious complications of topical mitomycin-C after pterygium surgery*. Ophthalmology. 1992; 99: 1647–1654.
20. Safianik B, Ben-Zion I, Garzosi HJ: *Serious corneoscleral complications after pterygium excision with mitomycin C*. Br J Ophthalmol. 2002; 86: 357–358.
21. Raiskup F, Solomon A, Landau D, Ilsar M, Frucht-Pery J: *Mitomycin C for pterygium: long term evaluation*. Br J Ophthalmol. 2004; 88: 1425–1428.
22. Enock ME, Omoti AE, Dawodu OA, Fuh UC, Eguaoje IE: *Effectiveness of intra-operative Mitomycin-C in reducing the recurrence of pterygium in Irrua, Nigeria*. Niger Postgrad Med J. 2010; 17: 55–59.
23. Kheirkhah A, Hashemi H, Adelpour M, Nikdel M, Rajabi MB, Behrouz MJ: *Randomized trial of pterygium surgery with mitomycin C application using conjunctival autograft versus conjunctival-limbal autograft*. Ophthalmology. 2012; 119: 227–232.
24. Khakshoor H, Razavi ME, Daneshvar R, Shakeri MT, Ghate MF, Ghooshkhanehi H. *Preoperative subpterygeal injection vs intraoperative mitomycin C for pterygium removal: comparison of results and complications*. Am J Ophthalmol. 2010; 150: 193–198.
25. Frucht-Pery J, Raiskup F, Ilsar M, Landau D, Orucov F, Solomon: *Conjunctival autografting combined with low-dose mitomycin C for prevention of primary pterygium recurrence*. Am J Ophthalmol. 2006; 141: 1044–1050.
26. Uçakhan OO, Kanpolat A: *Combined "symmetrical conjunctival flap transposition" and intraoperative low-dose mitomycin C in the treatment of primary pterygium*. Clin Exp Ophthalmol. 2006; 34: 219–225.
27. Chen Q, Li Y, Xu F, Yan Y, Lu K, Cui L, et al.: *Comparison of Inferior and Superior Conjunctival Autograft for Primary Pterygium*. Curr Eye Res. 2015; 40: 786–791.
28. Elwan SA: *Comparison between sutureless and glue free versus sutured limbal conjunctival autograft in primary pterygium surgery*. Saudi J Ophthalmol. 2014; 28: 292–298.
29. Sati A, Shankar S, Jha A, Kalra D, Mishra S, Gurunadh VS: *Comparison of efficacy of three surgical methods of conjunctival autograft fixation in the treatment of pterygium*. Int Ophthalmol. 2014; 34: 1233–1239.
30. Hacıoğlu D, Erdöl H: *Developments and current approaches in the treatment of pterygium*. Int Ophthalmol 2017; 37: 1073–1081.
31. Kheirkhah A, Safi H, Molaei S, Nazari R, Behrouz MJ, Raju VK: *Effects of pterygium surgery on front and back corneal astigmatism*. Can J Ophthalmol. 2012; 47: 423–428.
32. Altan-Yaycioglu R, Kucukerdonmez C, Karalezli A, Corak F, Akova YA: *Astigmatic changes following pterygium removal: comparison of 5 different methods*. Indian J Ophthalmol. 2013; 61: 104–108.
33. Khan FA, Khan Niazi SP, Khan DA: *The impact of pterygium excision on corneal astigmatism*. J Coll Physicians Surg Pak. 2014; 24: 404–407.

The paper was originally received 23.10.2018 (KO-00185-2018)/
Praca wpłynęła do Redakcji 23.10.2018 (KO-00185-2018)
Accepted for publication 09.01.2019/
Zakwalifikowano do druku 09.01.2019.

Reprint requests to (Adres do korespondencji):
Barbara Nowacka MD, PhD
e-mail: nowackamd@gmail.com