

(31)

# Acriva UD Reviol multifocal intraocular lens in patients undergoing cataract surgery – 6-month follow-up

*Wielogniskowa soczewka Acriva UD Reviol u pacjentów po operacji zaćmy – obserwacje 6-miesięczne*

Wojciech Lubiński, Karolina Podborczyńska-Jodko

Department of Ophthalmology, Pomeranian Medical University, Szczecin, Poland  
Head: Professor Wojciech Lubiński MD, PhD, FEBO

**Abstract:**

**Purpose:** To evaluate visual outcomes and complications in patients after binocular Acriva UD Reviol MFB 625 (VSY Biotechnology) multifocal intraocular lens implantation.

**Methods:** 40 eyes of 20 patients were reassessed at six months following bilateral IOL implantation. The following were evaluated: binocular UDVA and near, binocular uncorrected intermediate visual acuity, spectacle independence, uncorrected binocular photopic contrast sensitivity for distance and near, uncorrected binocular mesopic contrast sensitivity for distance (CS – CSV – 1000, F.A.C.T.); stereoscopic vision (Lang Stereotest II), patient satisfaction, subjective symptoms (modified NE VFQ-25) and postoperative complications.

**Results:** Six months after surgery the mean binocular UDVA was logMAR  $-0.05 \pm 0.07$ , UIVA was  $+0.04 \pm 0.09$  and uncorrected near visual acuity was  $+0.06 \pm 0.08$ . At six months postoperatively, all patients were totally spectacle-independent. Contrast sensitivity under different conditions was within the normal range at all spacial frequencies. Stereoscopic vision was normal in all patients. Low level of glare/halo perception was detected in 55% of patients. General vision quality was high and rated as 1.85 (1 – the best, 5 – the worst). No severe postoperative complications were observed.

**Conclusion:** Cataract surgery with Acriva UD Reviol MFB 625 implantation in a selected group of patients was very effective for all distances and provided excellent patient satisfaction.

**Key words:**

cataract surgery, Acriva UD Reviol MFB 625, visual outcomes, complications.

**Abstrakt:**

**Cel:** ocena funkcji wzroku i powikłań u pacjentów po obuocznym wszczępiu soczewki wielogniskowej Acriva UD Reviol MFB 625 (VSY Biotechnology).

**Metody:** sześć miesięcy po obuocznej operacji w 40 oczach (u 20 pacjentów) oceniano: obuoczną nieskorygowaną ostrość wzroku do dali i bliży oraz obuoczną nieskorygowaną ostrość wzroku do widzenia pośredniego, niezależność od okularów, nieskorygowaną obuoczną czułość kontrastową fotopową i mezopową do dali oraz fotopową do bliży (CS – CSV – 1000, F.A.C.T.); widzenie stereoskopowe (Lang Stereotest II), stopień zadowolenia pacjentów, objawy subiektywne (zmodyfikowany NE VFQ-25) oraz powikłania.

**Wyniki:** sześć miesięcy po obuocznej operacji średnia obuoczna nieskorygowana ostrość wzroku do dali wynosiła logMAR  $-0,05 \pm 0,07$ , obuoczna nieskorygowana ostrość wzroku do widzenia pośredniego wynosiła  $+0,04 \pm 0,09$ , a średnia obuoczna nieskorygowana ostrość wzroku do bliży wynosiła  $+0,06 \pm 0,08$ . Wszyscy pacjenci byli całkowicie niezależni od okularów. Czułość kontrastowa w różnych warunkach była w zakresie normy. Widzenie stereoskopowe było prawidłowe u wszystkich pacjentów. Niski poziom percepcji glare/ halo wykryto u 55% pacjentów. Ogólne zadowolenie z widzenia było wysokie i wynosiło 1,85 (1 – najlepiej, 5 – najgorzej). Nie było żadnych poważnych powikłań pooperacyjnych.

**Wniosek:** u pacjentów poddanych operacji zaćmy z wszczępieniem Acriva UD Reviol MFB 625 uzyskano bardzo dobre wyniki funkcjonalne narządu wzroku do różnych odległości, wszyscy byli zadowoleni z efektów operacji.

**Słowa kluczowe:**

operacja zaćmy, Acriva UD Reviol MFB 625, funkcja wzroku, powikłania.

**Introduction**


Nowadays, the number of multifocal intraocular lens (IOLs) implanting procedures during cataract or refractive surgery is increasing steadily (1). The key determinants of treatment success in cataract and refractive lens exchange surgery providing pseudoaccommodation are the improved visual acuity for distance, near, and intermediate distances as well as the incre-

ased spectacle independence. Each year, several companies offer ophthalmic surgeons new models of multifocal intraocular lenses. One of them is a foldable, hydrophobic, diffractive, multifocal Acriva UD Reviol MFB 625 IOL (VSY Biotechnology). The goal of this study was to evaluate visual outcomes and complications in patients after binocular implantation of the discussed lens at 6 months postoperatively. To the best

of our knowledge it is one of the first publications to report visual outcomes achieved with this lens.

**Patient and methods**

40 eyes of 20 patients (14 females, 6 males) at the mean age of  $62.55 \pm 6.61$  (age range of 51 to 74 years), who underwent uneventful cataract surgery with implantation of a diffractive one-piece Acriva UD Reviol MFB 625 intraocular lens (Fig. 1) in both eyes (at 3-week interval) were enrolled in the study. All patients gave their informed consent and the study was performed in accordance with the Declaration of Helsinki.



**Fig. 1.** Acriva UD Reviol MFB 625 intraocular lens.  
**Ryc. 1.** Fotografia soczewki Acriva UD Reviol MFB.

The study inclusion criteria included: age – between 40 and 75 years, bilateral cataract, preoperative corneal astigmatism  $< 1.0$  D (Corneal Videokeratography Zeiss). The patients were also required to have a strong motivation for spectacle independence and agree to comply with a scheduled scheme of follow-up visits.

The exclusion criteria included other eye diseases (except for cataract) and oculomotor dysfunction. The subjects were also excluded if they were under 40 or over 75 years of age, had unrealistic visual outcome expectations, a profession that demands visual precision, mental health issues, history of stroke, dyslexia, were dissatisfied with progressive glasses and if the axial length of their eyes was shorter than 22 mm or longer than 24 mm.

**Surgical technique**

Target refraction was emmetropia. The IOL power values were calculated using IOL Master (Carl Zeiss-Meditec, Jena, Germany – the 2011 version of the software), the A-constant as recommended by the manufacturer and SRK-T formula. The same surgeon (WL) performed all procedures under topical anesthesia implanting the lens in the capsular bag through the 2.2 mm temporal, clear corneal incisions. The diameter of the continuous, curvilinear capsulorhexis was approximately 5 mm.

The Acriva UD Reviol MFB 625 intraocular lens was inserted using the injector system for ACRIVA UD REVIOL multifocal intraocular lens (Fig. 1) (Tab. I).

<b>Materiał/ Material</b>	Hydrofilowa, akrylowa z hydrofobową powierzchnią i absorpcją UV/ Hydrophilic, acrylic with hydrophobic surface and UV absorption
<b>Wzór optyczny/ Optic design</b>	Wielogniskowa, związalna, asferyczna jedno-częściowa, dwuogniskowa, dwuwypukła, 28 pierścieni, dodatek +3.75 D/ multifocal, foldable, aspheric one-piece, biconvex, 28 rings, +3.75 D add at IOL plane
<b>Haptyka/ kąt/ Haptic/ Angulation</b>	plate/ 0°
<b>Średnica/ Diameter (mm)</b>	Optyka/ Optic 6 mm Całkowita/ Total 12.5 mm
<b>Wzór haptyki/ Haptic design</b>	Zmodyfikowane C/ Balance modified C
<b>Dioptraż/ Diopter range</b>	Od -20.00 D do +45.00 D (przyrosty 0.5 D)/ From -20.00 D to +45.00 D (0.5 D increments) Specjalna produkcja od +32.00 do 45.00 D (przyrosty 0.5 D) / Special production from +32.00 do/ to 45.00 D (0.5 D increments)
<b>Stała A (ultradźwięki)/ A constant (ultrasound)</b>	118.0
<b>Stała A (optyczna)/ A constant (optic)</b>	SRK-T 118.3, SRK II-118.5

**Tab. I.** General IOL characteristics.

**Tab. I.** Ogólna charakterystyka soczewki.

**Outcome measures**

Six months after surgery, the following parameters were assessed: binocular uncorrected distance visual acuity [UDVA – logMAR – ETDRS chart (4 m)], binocular uncorrected near visual acuity [UNVA – logMAR – 35 cm], uncorrected intermediate visual acuity [UCIVA – logMAR (60 cm)], spectacle independence, binocular uncorrected contrast sensitivity – photopic (85 cd/m<sup>2</sup>) and mesopic (3 cd/m<sup>2</sup>) for distance (2.5 m) as well as photopic for near (35 cm) (CS – 1.5, 3, 6, 12, 18 c/deg, CSV – 1000, F.A.C.T.) and stereoscopic vision (Lang Stereotest II). Additionally, the subjects were questioned for subjective symptoms level of satisfaction (modified National Eye Institute Visual Function Questionnaire-25; NEI VFQ-25) (2) and complications.

The visual acuity and astigmatism results at baseline and at 6 months following surgery were compared using Wilcoxon test. P value  $< 0.05$  was considered statistically significant.

**Results**

The mean preoperative refractive error was  $1.97 \pm 2.37$  D, (range: -10.0 D to +2.5 D). Six months after surgery the same value was 0.00.

The difference in the mean pre- and postoperative corneal astigmatism was not statistically significant ( $0.79 \pm 0.33$  vs.  $0.78 \pm 0.58$ ).

**Distance and near vision**

Six month after binocular implantation of Acriva Reviol IOLs, no refractive error was found in our study subjects.

Table II shows the mean binocular uncorrected visual acuity for distance and near at baseline and at six months following cataract surgery.

	UDVA	UNVA
At baseline/ Przed operacją	0.64 ± 0.58	0.73 ± 0.61
At 6 months following surgery/ 6 miesięcy po operacji	-0.05 ± 0.07	0.06 ± 0.08

**Tab. II.** Mean binocular uncorrected visual acuity (UCVA) for distance and near, at baseline and at six months following cataract surgery.

**Tab. II.** Średnia obuoczna nieskorygowana ostrość wzroku do dali i bliży przed operacją zaćmy i 6 miesięcy po operacji zaćmy.

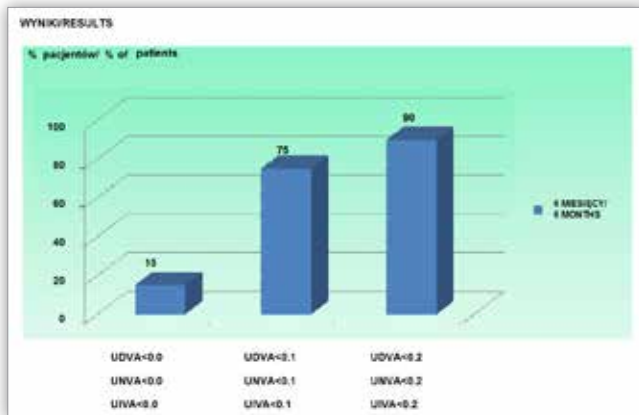
The binocular UDVA of <0.1 was achieved in 75% of patients and UNVA of <0.2 was achieved in 90% of patients.

The binocular uncorrected visual acuity values for distance and near were significantly better at 6 months postoperatively, as compared to baseline (UDVA: 0.64 ± 0.58 vs. -0.05 ± 0.07; p < 0.005; UNVA: 0.73 ± 0.61 vs. 0.06 ± 0.08 p < 0.005).

**Intermediate vision**

At six months postoperatively, the mean binocular UIVA was 0.04 ± 0.09. The binocular UIVA of logMAR 0.10 or better was achieved in 85% (17/20) of patients.

The cumulative UDVA, UCIVA and UCNVA values at 6 months following bilateral multifocal IOL implantation are shown in Figure 2.



**Fig. 2.** The cumulative percentage distribution of UDVA, UNVA and UIVA at 6 months following binocular multifocal IOL implantation.

**Ryc. 2.** Skumulowany rozkład procentowy UDVA, UNVA i UIVA 6 miesięcy po obuocznym wszczępieniu soczewek wielogniskowych.

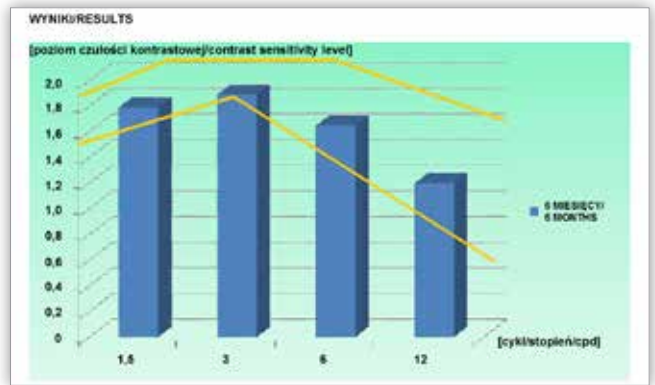
The binocular uncorrected visual acuity of logMAR <0.2 for distance, intermediate and near were achieved in 90% of patients.

**Spectacle independence**

Six months after surgery, all patients (20/20 – 100%) were totally spectacle- independent (for distance, intermediate and near vision).

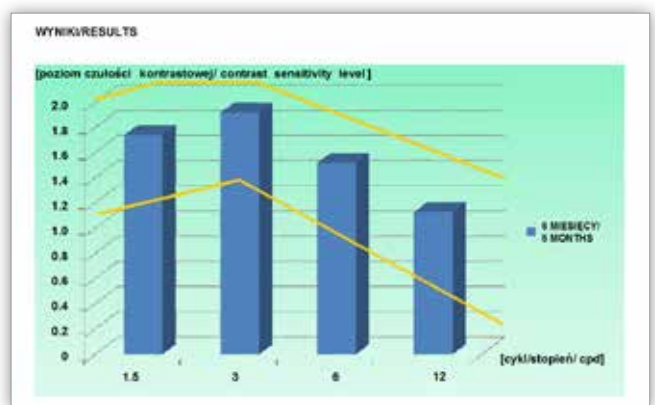
**Contrast sensitivity**

Six months postoperatively, binocular uncorrected photopic and mesopic contrast sensitivities for distance and photopic for near were found to be within normal limits in comparison to the normal population in the range of 50 to 75 years. (Fig. 3–5).



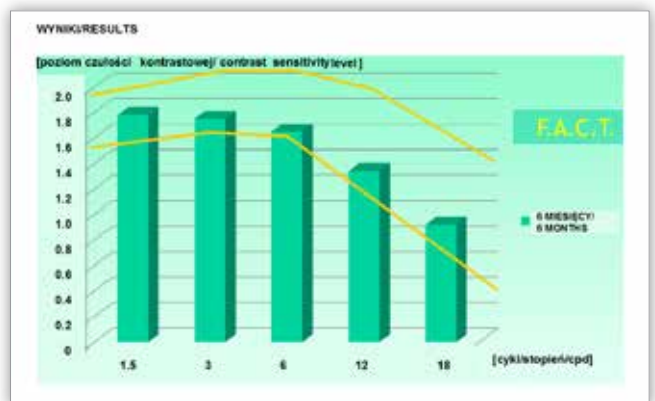
**Fig. 3.** Mean binocular uncorrected photopic contrast sensitivity for distance at six months following surgery.

**Ryc. 3.** Średnia obuoczna nieskorygowana fotopowa czułość kontrastowa do dali 6 miesięcy po zabiegu.



**Fig. 4.** Mean binocular uncorrected mesopic contrast sensitivity for distance at six months following surgery.

**Ryc. 4.** Średnia obuoczna nieskorygowana mezopowa czułość kontrastowa do dali 6 miesięcy po zabiegu.



**Fig. 5.** Mean binocular uncorrected photopic contrast sensitivity for near at six months following surgery.

**Ryc. 5.** Średnia obuoczna nieskorygowana fotopowa czułość kontrastowa do bliży 6 miesięcy po zabiegu.

**Stereoscopic vision**

Stereoscopic vision, measured using the screening Lang Stereotest II, was normal at 6 month’s follow-up.

**Patient satisfaction**

The results of the patient satisfaction evaluation are shown in Figure 6.

RESULTS-WYNIKI		
Patient's satisfaction – modified VFQ-25 / stopień zadowolenia z widzenia – zmodyfikowany test VFQ-25 (binocular, unaided vision)(obuocznicie, bez korekcji)		
	THE BEST - THE WORST NAJLEPSZY - NAJGORSZY	Acriva Reviol
Reading newspapers/czytanie gazet	(1 - 5)	1.35
Using computer/praca przy komputerze	(1 - 5)	1.45
Seeing signs /rozpoznanie znaków drogowych	(1 - 5)	1.05
Daytime driving/prowadzenie samochodu w dzień	(1 - 5)	1.00
Night driving/prowadzenie samochodu w nocy	(1 - 5)	1.57
Difficult situation driving/prowadzenie samochodu w trudnych warunkach	(1 - 5)	1.14
Seeing up close/widzenie do blizy	(1 - 5)	1.30
Steps and stairs/chodzenie po schodach	(1 - 5)	1.00
General VA quality/ogólne zadowolenie z widzenia	(1 - 5)	1.85
Worried about VA/niepokoje związane z widzeniem	(1 - 5)	2.25
Accomplish less due to VA/zmniejszenie aktywności życiowej z powodu widzenia	(5 - 1)	4.85
Frustrated due to VA/frustracja z powodu widzenia	(5 - 1)	4.90
Level of glare/haloposition spostrzeżenia olśnienia/halo	(0 - 4)	1.00

**Fig. 6.** Patient satisfaction results – modified VFQ-25 questionnaire.  
**Ryc. 6.** Stopień zadowolenia pacjentów oceniony zmodyfikowanym kwestionariuszem VFQ-25.

The general VA quality was rated as 1.85. Mean patient satisfaction scores for distance, intermediate and near activities were below 1.57 on the 5-point scale (1 – the best; 5 – the worst).

The patients (55%) who reported such unwanted effects as glare or halo rated their severity as 1 on the 4-point scale.

### Complications

At six months after surgery, slight decentration of the multifocal IOL was observed (without an influence on the VA and increase of visual phenomena) in 6 eyes (15%). None of the patients presented with the central posterior capsule opacification requiring Nd: YAG laser treatment.

### Discussion

Today, the goal of cataract surgeons is not only to remove the opacified lens, but also to restore vision at different distances. The growing patient expectation to be spectacle independent after cataract surgery accelerates the development of novel intraocular lens designs which improve vision at at least both distance and near and reduce the unwanted symptoms such as glare and halo. The Acriva UD Reviol MFB 625 intraocular lens, whose characteristics are shown in Figure 2, is one of such new lenses.

All patients presented with the better visual acuity at six months postoperatively. The implantation of Acriva UD Reviol MFB 625 intraocular lenses through the 2.2 mm incision did not induce significant postoperative astigmatism.

In our study, postoperative binocular UDVA and UNVA were significantly better ( $p < 0.005$ ) in comparison with preoperative values (Tab. II). Ninety percent of eyes achieved excellent binocular UDVA, UNVA and UIVA over logMAR 0.2 (Fig. 3). Visual acuity results presented in this study are near data described by Akova et al (3). In the study by Akova et al., binocular mean uncorrected visual acuity for distance, near and intermediate distance (Snellen, Jaeger tables) was 0.92 ( $< \log \text{MAR } 0.1$ ), 1.0 ( $\log \text{MAR } 0.00$ ), 1.1 ( $\log \text{MAR } 0.00$ ), respectively.

All patients in our study group did not need glasses for distance, near and intermediate vision anymore. Typically, multifocal diffractive IOLs direct the light at two fixed focal points, each of them representing 2 fixed working distances (far

and near). Working distances between these points are associated with suboptimal visual acuity (4). More recently, trifocal diffractive IOLs have been proposed to improve vision at intermediate distances (5). The introduction of diffractive multifocal IOLs with lower near additions (6) has increased vision at intermediate distance without compromising near and distance vision. In our study, very good intermediate vision achieved with Acriva UD Reviol MFB 625 intraocular lens may result from the slightly reduced near addition (+3.75 D) and unique optic design (ring height, width and intervals between them).

Like other authors, we have previously observed a complete spectacle independence in patients after binocular implantation of different multifocal IOLs like Acri.Lisa 366D or Acriva Reviol MFM 611 (7, 8). These excellent results might be explained by the very accurate patient selection for multifocal IOL, precise power calculation, perfect surgical technique and relatively young patients (mean age of 63 years) with a good brain plasticity, which offers potential for neuroadaptation to the new optic conditions.

It is known that multifocal IOL implantation can reduce contrast sensitivity. It should be noted that this reduction does not appear to differ between different types of multifocal IOLs (9). In our series of patients, contrast sensitivity was very good. Six month after surgery, binocular photopic and mesopic contrast sensitivity for distance as well as photopic contrast sensitivity for near were within normal limits established for healthy individuals between 50 and 75 years of age (10) (Fig. 4–6). Akova et al. reported similar contrast sensitivity results (3).

The normal results of stereoscopic vision suggest that patients with implanted Acriva UD Reviol MFB 625 intraocular lenses can see objects precisely.

In our study, vision quality was very high (Fig. 7). During six month follow-up, the patients only reported mild difficulties when performing different activities mentioned in VFQ-25 questionnaire. The most prominent difficulty was driving at night but, fortunately, its level of perception was low. Some of our patients worried about their visual acuity, as it is commonly known that multifocal IOLs cause such photic phenomena as glare and halo with the variable frequency ranging from 10% to 80% across studies (11, 12). In our study, 55% of patients reported mild glare/halo problems with no severe symptoms. It should be emphasized that the reported visual phenomena did not affect normal activity and all patients accepted them. These mild unwanted effects can be attributed to the successful design of the diffractive steps in Acriva UD Reviol MFB 625 intraocular lens.

In our series of eyes after multifocal IOL implantation, there were no serious complications at six months postoperatively. There was no case of posterior capsule opacification (PCO) which would require Nd: YAG laser treatment. It shows that Acriva UD Reviol MFB 625 intraocular lens has good uveal biocompatibility as well as design protective against PCO formation. The literature makes it clear that IOL decentration and tilt can cause comatic aberration and reduce vision quality (13). We observed slight IOL decentration in 15% of eyes, however it did not affect significantly the subjective vision quality.

In conclusion, our first experience with bilateral cataract surgery and simultaneous implantation of Acriva UD Reviol

MFB 625 in a selected group of patients suggests it is a very effective procedure providing outstanding vision quality for all distances and excellent patient satisfaction, as well. Acriva UD Reviol MFB 625 intraocular lens can be offered cataract surgeons and their patients as a good, predictable and relatively inexpensive lens.

#### Financial disclosure

The authors have no financial interest.

#### References:

1. De Vries NE, Nuijts R: *Multifocal intraocular lenses in cataract surgery : literature review of benefits and side effects*. J Cataract Refract Surg. 2013; 39: 268–278.
2. Mangione CM, Lee PP, Gutierrez PR, Spritzer K, Berry S, Hays RD: *Development of the 25-item National Eye Institute Visual Function Questionnaire (VFQ-25)*. Archives of Ophthalmology 2001; 119: 1050–1058.
3. Akova Y, Arslan O, Baykara M, Cinh M, Takmaz T, Usta Y: *Safety and effectiveness of Acriva Reviol MFB 625 multifocal intraocular lens: a prospective multicenter clinical study*. ESCRS 2012, www.es CRS.org/milan2012/.../free-paper-details.
4. Alfonso JF, Fernandez-Vega L, Puchades C, Monte-Mico R: *Intermediate visual function with different multifocal intraocular lens models*. J Cataract Refract Surg. 2010; 36: 733–739.
5. Gatinel D, Pagnouille C, Houbrechts Y, Gobil L: *Design and qualification of a diffractive trifocal optical profile for intraocular lenses*. J Cataract Refract Surg, 2011; 37: 2060–2067.
6. Hutz WW, Eckhardt HB, Rohring B, Grolmus R: *Intermediate vision and reading speed with Array, Tecnis and Restor intraocular lenses*. J Refract Surg. 2008; 24: 251–256.
7. Lubiński W, Podboraczyńska-Jodko K, Gronkowska-Serafin J, Karczewicz D: *Visual outcome three and six months after implantation of Acri.LISA 366D lenses*. Klin Oczna. 2012; 114(4): 249–254.
8. Can I, Bostanci Cerean B, Soyugelen G, Takmaz T: *Comparison of clinical outcomes with two small-incision diffractive multifocal intraocular lenses*. J Cataract Refract Surg. 2012; 38: 60–67.
9. Gierek-Ciaciura S, Cwalina L, Bednarski L, Mrukwa-Kominek E: *A comparative clinical study of the visual results between three types of multifocal lenses*. Graefes Arch Clin Exp Ophthalmol. 2010; 248(1): 133–140.
10. Pomerance G, Evans D: *Test – retest reliability of the CSV – 1000 contrast test and its relationship to glaucoma therapy*. Invest Ophthalmol Vis Sci. 1994; 35(9): 3357–3361.
11. Alio JL, Elkady B, Ortiz D, Bernabeu G: *Clinical outcomes and intraocular optical quality of a diffractive multifocal intraocular lens with asymmetrical light distribution*. J Cataract Refract Surg. 2008; 34: 942–948.
12. Kaymak H, Mester U: *Erste Ergebnisse mite inter neunen aberrationskorrigierten intraokularen Bifokallinse*. Ophthalmologe 2007; 104: 1046–1051.
13. Wang L, Koch DD: *Effect of decentration of wavefront-corrected intraocular lenses on the higher-order aberrations of the eye*. Arch Ophthalmol. 2005; 123: 1226–1230.

The study was originally received 23.03.2014 (890737)/  
Praca wpłynęła do Redakcji 23.03.2014 r. (890737)  
Accepted for publication 08.08.2014/  
Zakwalifikowano do druku 08.08.2014 r.

Adres do korespondencji (Reprint requests to):  
Professor Wojciech Lubiński MD, PhD  
Księżycowa 6  
72-006 Mierzyn, Poland  
e-mail: lubinski@pro.onet.pl

**Zapraszamy na naszą stronę internetową**

**[www.okulistyka.com.pl](http://www.okulistyka.com.pl)**