



Received: 2016.05.11
Accepted: 2016.06.27
Published: 2017.02.13

Authors' Contribution:

- A** Study Design
- B** Data Collection
- C** Statistical Analysis
- D** Data Interpretation
- E** Manuscript Preparation
- F** Literature Search
- G** Funds Collection

Ultrasound Elastography for Determination of the Age of Venous Thrombi. Evaluation of Thrombus Evolution in Patients After Sclerotherapy

Łukasz Paluch¹**ABCEFG**, Ewa Nawrocka-Laskus¹**CD**, Agnieszka Dąbrowska^{1a},
Tadeusz Popiela²**ABCEFG**, Jerzy Walecki¹**ABCEFG**

¹ Department of Radiology, Gruca Orthopedic and Trauma Teaching Hospital, Center of Postgraduate Medical Education, Otwock, Poland

² Department of Diagnostic Imaging, Injury Center of Emergency Medicine and Disaster, Jagiellonian University, Cracow, Poland

Author's address: Łukasz Paluch, Department of Radiology, Gruca Orthopedic and Trauma Teaching Hospital, Center of Postgraduate Medical Education, Otwock, Poland, e-mail: lpaluch@op.pl

Background:

Venous thrombosis is a multicausal disease involving intravenous clot formation. It may occur spontaneously or after provoking events, such as traumatic injuries to the pelvis, upper and lower extremities, immobilization, intravascular procedures, including venous catheterization or injection. Color Doppler ultrasonography is a rapid and non-invasive technique for evaluation of venous disease. It is a very sensitive method for detection of thrombi, but has some limitations, e.g. inability to distinguish between an old and fresh thrombus. Elastography as a method for evaluation of tissue elasticity and allows more accurate assessment of venous thrombosis. The thrombus solidifies significantly during the process of remodeling, thereby changing elasticity, while the tissues located around the vessel remain unchanged. Moreover, the homogeneity of the thrombus is also changed. These factors allow for exact determination of the age of the thrombus depending on changes of its elasticity.

Material/Methods:

The object of this study was to assess thrombus age in patients with saphenous vein insufficiency treated with sclerotherapy. We examined 34 patients, 30 women and 4 men, aged 18–62 years. All short-listed patients with initial 7–8 mm vessel diameter underwent treatment with 3% Aetoxysklerol mixed with CO₂ and other respiratory gases. Data acquisition was performed using an Esaote MyLab Twice device with LA523 linear probe.

Results:

On the sixth day after the treatment 31 patients presented uniform, hypoechogenic thrombus in B-mode image. Ultrasound-based elasticity images (elastography) showed significant predominant red and green areas. Blue area was either invisible or appeared in insignificant grade on examined area. The mosaic image of colors appeared on 2 patients. On the fourteenth day of study 21 patients still presented hypoechogenic thrombus, whereas mixed echogenicity of thrombus appeared on 11 patients.

On 28 examined patients mosaics of red, green and blue colors were observed, with blue color significantly predominating over red color. 3 patients presented mosaics of colors without a predominate color.

Conclusions:

Elastography as a method of thrombus evaluation, provides information about relative shrinkage of blood clot. It seems that elastography can improve accurate assessment of the exact age of thrombus.

MeSH Keywords:

Elasticity Imaging Techniques • Ultrasonography • Ultrasonography, Doppler, Color

PDF file:

<http://www.polradiol.com/abstract/index/idArt/899517>

Background

Venous thrombosis is a well-known disease that accompanies various pathological states. It frequently coexists with injuries of the pelvis, upper, and lower limbs [1]. It may also occur during immobilization, hospitalization, after accidents or procedures, such as venous catheterization, injections, or intravascular procedures [2]. Surgical or post-surgical compression alone may facilitate thrombus formation [3]. Analogous process may be observed following therapeutic procedures, e.g. sclerotherapy [4].

Diagnostic method of choice for assessment of limb thrombosis is ultrasonography. Thrombus is detected during a compression test, while cruor is evaluated in B-mode (gray-scale) imaging. This method is very sensitive with regard to detection of the thrombus, but is burdened by significant error with respect to the assessment of its duration [5].

Proper assessment of the time of thrombus formation is essential to making proper decision regarding management or possible occurrence of complications, such as migration of a thrombus fragment leading to pulmonary embolism. Thrombi of shorter age (below 7 days) are characterized by better response to therapy and greater risk of generating pulmonary embolism. It is believed that hypoechogenic thrombi correspond to shorter and hyperechogenic lesions – longer duration. Change in echogeneity is explained by thrombus remodeling. Elastography, as a method of assessment of relative tissue elasticity enables more precise evaluation of the thrombus. The lesion becomes organized, meaning that its elasticity changes, while the surrounding tissues retain their properties. Thrombus homogeneity also undergoes alterations. These factors enable assessment of thrombus age depending on changes of its elasticity. Literature reports demonstrate such relationships [6].

In our study we presumed that the state after administration of sclerosing agent resembles the conditions after thrombosis [4]. Examination of patients after sclerotherapy provided the means for precisely determining the duration of lesions and selection of thrombi caused by a similar factor.

Material and Methods

Study included patients who had been previously treated for venous insufficiency with sclerotherapy due to insufficiency of the saphenous vein. We examined a total of 34 individuals, 30 women and 4 men aged 18–62 years. The study included patients with vessel diameter of 7–8 mm at baseline, undergoing treatment with 3% Aetoxysklerol mixed with CO₂ and respiratory gases. Procedures were carried out in various centers by experienced operators. Patients were examined on the 6th and 14th day after surgery. The study was not associated with postoperative follow-up and was not related in any way to the treatment. The study was conducted using Esaote MyLab Twice device with a LA523 linear probe.

The study was conducted on a group of patients treated with sclerotherapy for venous insufficiency. A study on such a group of subjects provides very

thorough assessment of evolution of the lesion over time. Establishing the time of thrombus formation with such a high accuracy is difficult among patients with spontaneous thrombosis. Formation of thrombus in the vessel following injection of a sclerosing agent is not identical to the natural process, but both of these phenomena seem to be very similar. They may lead to formation of a clot in a vessel and possible subsequent fibrosis [4]. The aim of the study was to evaluate only those thrombi, which are subject to the fibrosis process.

Saphenous vein was considered a reference vessel due to its relatively superficial location and homogeneous character of surrounding tissues.

During the first examination performed on the 6th day post-op we assessed the appearance of the vessel in cross-sectional and longitudinal projections using B-mode. Possible features of recanalization were evaluated using power Doppler and color Doppler. Patients with features of recanalization on the 6th or the 14th day were excluded from the study.

Saphenous vein was assessed around the ostial valve and around 10 cm and 20 cm from the ostial valve. The vessel was assessed at each of those points in cross-sectional and longitudinal projections using B-mode, dual elastography and elastography. During the examination the vessel was positioned to take up about 1/3 of the screen. ROI was positioned in such a way that 80% of its area accounted for the vessel and 20% for the surrounding tissue. During the examination the probe was placed parallel to the vessel, with vibration amplitude of about 1/s and a depth of about 2 mm. Subsequent study, 14 days after treatment, was carried out analogously to the first test at the 6th day.

Results

Stable images were obtained by uniform application of pressure. We attempted to eliminate from the examined field any vessels or tissues with differing elasticity. Cross-sectional studies were considered non-diagnostic due to lack of repeatability of the results.

For evaluation we employed the color scale, where red corresponded to a lesion characterized by greatest flexibility, green to intermediate, and blue to least flexible changes.

In 2 patients we observed the signs of recanalization on the 6th day and on the 14th day in one patient. These subjects were excluded from the study.

The study ultimately included 31 patients – 27 women and 4 men. In 31 patients (100%) B-mode examination on the 6th day after procedure revealed homogeneous, hypoechogenic thrombus (Figure 1). On elastographic examination 29 patients (94%) (Figure 2). The blue area was either invisible or occupied a very small part of the examined field of view. In 2 patients (6%) we obtained a mosaic of colors without a predominating color (Figure 3).

On the examination performed in B-mode on the 14th day after procedure in 21 patients (68%) thrombus was still

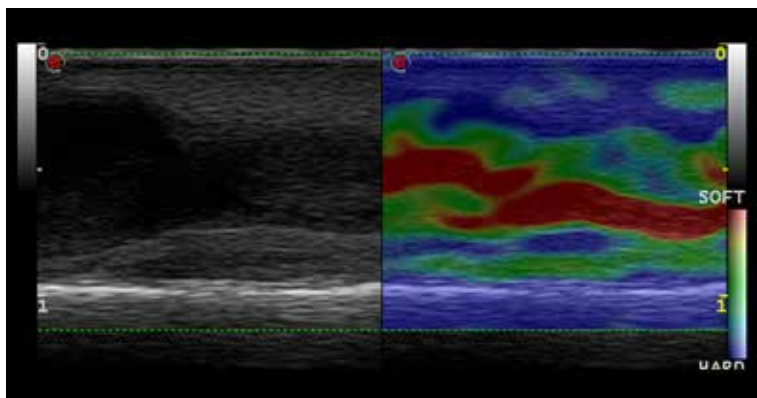


Figure 1. Follow-up ultrasound examination 7 days after detection of the thrombus. B-mode ultrasound image showing hypoechoic thrombus (left). US elastogram presenting a thrombus with a red area in the middle and green area peripherally (intermediate elasticity) (right).

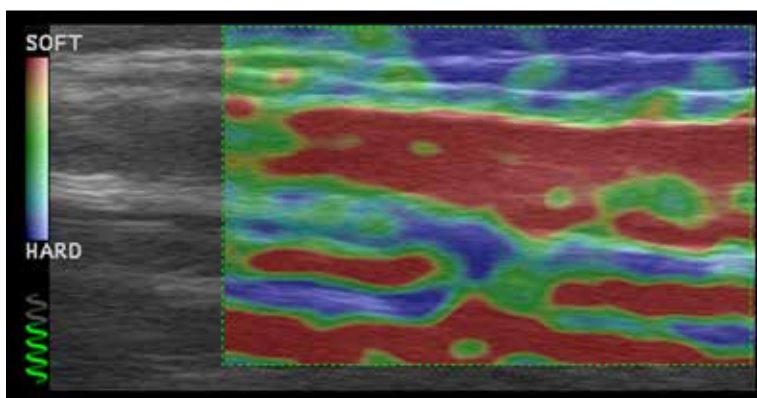


Figure 2. Follow-up ultrasound examination 7 days after detection of the thrombus. US elastogram presenting a thrombus with predominance of red color – high elasticity.

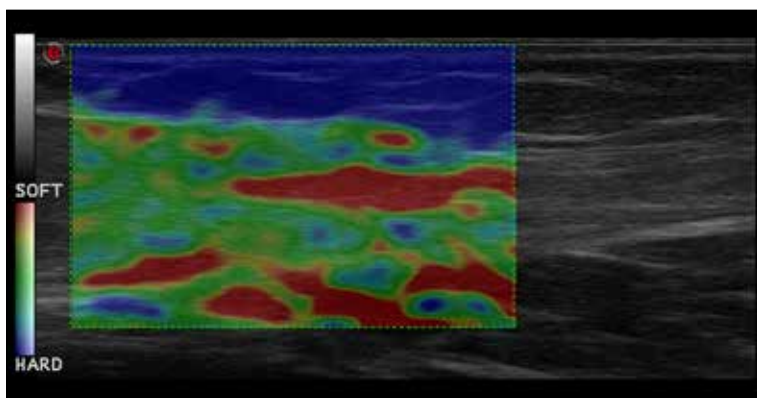


Figure 3. Follow-up ultrasound examination 7 days after the initial test. US elastogram presents a mosaic of colors.

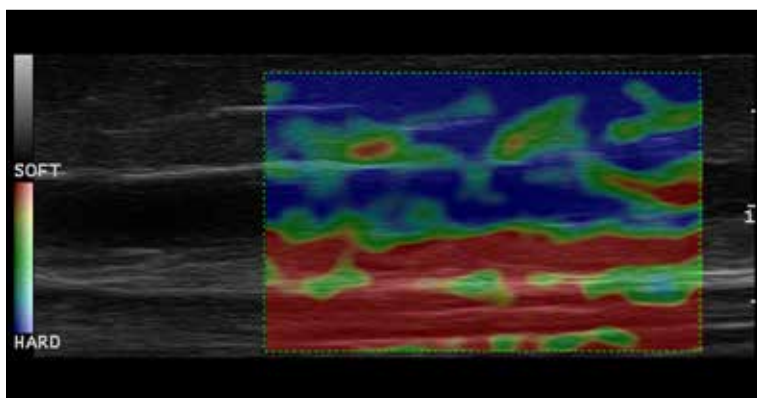


Figure 4. Follow-up ultrasound examination 14 days after the initial test. The thrombus with low-strain signal (blue) in US elastogram.

hypoechoic, while in 10 subjects (32%), it was characterized by mixed echogenicity. On elastographic examination in 28 patients (90%) we observed a mosaic of red,

green and blue, with predominance of blue color over red (Figure 4). In 3 individuals (10%) we observed a mosaic of colors without a leading color (Figure 5).

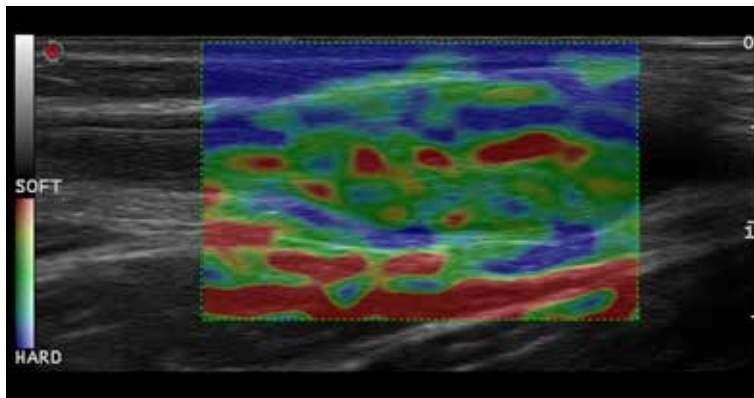


Figure 5. Follow-up ultrasound examination 14 days after detection of the thrombus. US elastogram showing a mosaic of colors.

Discussion

Morphology of a spontaneously formed thrombus may be different from a thrombus provoked with Aetoxysklerol. The key, however, is to present possibilities of assessment of thrombus evolution over time. Use of this modality enabled very accurate assessment from the moment thrombus begins forming. Elastographic examination demonstrated a dependence of thrombus elasticity on time of its creation. Our study showed a significant difference between relative flexibility of the lesions on the 6th and 14th day.

At the beginning of the study the apparent difficulty was to carry out a series of reproducible diagnostic images. It was also problematic to exert appropriate, uniform pressures. During the course of the study, cross-sectional images were rendered non-diagnostic and excluded the analysis. Only the images obtained in longitudinal projection were considered diagnostic.

Results of the study are consistent with our assumptions regarding possibility of thrombus evaluation using elastography. We are not aware of any other reports depicting the problem of assessing duration of thrombosis in such manner.

Conclusions

In order to assess the age of the thrombus in elastographic study the most important thing is to evaluate the red and

blue colors and their mutual relationship. The green color does not seem to be diagnostic. The presence of red color only, or its substantial predominance over blue indicates the early changes (6 days), while the presence of blue alone, or its substantial predominance over red characterizes changes older than 7 days. Mosaic of colors may be present both in early as well as late thrombi and its significance is unclear.

Traditional B-mode ultrasound examination allowed accurate assessment in 100% of thrombi (31 patients) on the 7th day, elastography – 94% (29 patients), while in 6% of cases (2 patients) elastographic image was considered ambiguous.

On the 14th day conventional B-mode ultrasound examination revealed change in thrombus structure in 32% of cases (10 patients) while no change in structure was noted in 68% (21 patients). Elastography performed on the 14th day showed change in elasticity in of 90% of cases (24 patients), while in 10% of cases (3 patients) the images were considered ambiguous.

These results show slightly smaller effectiveness of elastography in assessment of early and very early thrombosis (up to 7th day) compared to conventional examination. On the 14th day we observed significant superiority of elastography compared to traditional imaging.

References:

1. Ikpeme A, Akintomide A, Ukweh O, Effanga S: Duplex ultrasound: Indications and findings in a newly created facility at the University of Calabar Teaching Hospital, Calabar. *Niger J Clin Pract*, 2016; 19(3): 339–43
2. Paydar S, Sabetian G, Khalili H et al: Management of deep vein thrombosis (DVT) prophylaxis in trauma patients. *Bull Emerg Trauma*, 2016; 4(1): 1–7
3. Ordi J, Salmerón L, Acosta F et al., Investigators of the ESPOT-TVP study: Study of prognostic factors and prevalence of post-thrombotic syndrome in patients with deep vein thrombosis in Spain. *Med Clin*, 2016; 146(2): 49–54
4. Jacobson BF, Franz RC, Hurly EM et al: Mechanism of thrombosis caused by sclerotherapy of esophageal varices using sodium tetradecyl sulphate. *Surg Endosc*, 1992; 6(1): 4–9
5. Anvari A, Barr RG, Dhyani M, Samir AE: Clinical application of sonoelastography in thyroid, prostate, kidney, pancreas, and deep venous thrombosis. *Abdom Imaging*, 2015; 40(4): 709–22
6. Geier B, Barbera L, Muth-Werthmann D et al: Ultrasound elastography for the age determination of venous thrombi. Evaluation in an animal model of venous thrombosis. *Thromb Haemost*, 2005; 93(2): 368–74