



Received: 2016.06.07
Accepted: 2016.07.01
Published: 2017.03.28

Authors' Contribution:

- A** Study Design
- B** Data Collection
- C** Statistical Analysis
- D** Data Interpretation
- E** Manuscript Preparation
- F** Literature Search
- G** Funds Collection

Routine Use of Contrast Swallow After Total Gastrectomy and Esophagectomy: Is it Justified?

Nader El-Sourani^{ABCDEF}, Helge Bruns^{AD}, Achim Troja^{AD}, Hans-Rudolf Raab^A, Dalibor Antolovic^{AD}

European Medical School, University Hospital for General and Visceral Surgery, Klinikum Oldenburg, Oldenburg, Germany

Author's address: Nader El-Sourani, European Medical School, University Hospital for General and Visceral Surgery, Klinikum Oldenburg, Rahel-Straus-Str. 10, 26133 Oldenburg, Germany, e-mail: el-sourani.nader@klinikum-oldenburg.de

Background:

After gastrectomy or esophagectomy, esophagogastrostomy and esophagojejunostomy are commonly used for reconstruction. Water-soluble contrast swallow is often used as a routine screening to exclude anastomotic leakage during the first postoperative week. In this retrospective study, the sensitivity and specificity of oral water-soluble contrast swallow for the detection of anastomotic leakage and its clinical symptoms were analysed.

Material/Methods:

Records of 104 consecutive total gastrectomies and distal esophagectomies were analysed. In all cases, upper gastrointestinal contrast swallow with the use of a water-soluble contrast agent was performed on the 5th postoperative day. Extravasation of the contrast agent was defined as anastomotic leakage. When anastomotic insufficiency was suspected but no extravasation was present, a computed tomography (CT) scan and upper endoscopy were performed.

Results:

Oral contrast swallow detected 7 anastomotic leaks. Based on CT-scans and upper endoscopy, the true number of anastomotic leakage was 15. The findings of the oral contrast swallow were falsely positive in 4 and falsely negative in 12 patients, respectively. The sensitivity and specificity of the oral contrast swallow was 20% and 96%, respectively.

Conclusions:

Routine radiological contrast swallow following total gastrectomy or distal esophagectomy cannot be recommended. When symptoms of anastomotic leakage are present, a CT-scan and endoscopy are currently the methods of choice.

MeSH Keywords:

Contrast Media • Esophagectomy • Gastrectomy • Multidetector Computed Tomography • Swallows

PDF file:

<http://www.polradiol.com/abstract/index/idArt/899951>

Background

Anastomotic leakage is considered to be one of the most serious complications after gastric and esophageal surgery for an underlying malignancy. The incidence of anastomotic leakage has been reported to be up to 53% and correlated to factors such as surgical experience, case-load, and general health of the patient [1,2]. Multiple pathophysiological factors have been discussed [3–5]. Ischemia of the conduit as well as mistakes in the surgical technique are believed to be the most important factors contributing to anastomotic leakage [6]. Typically, anastomotic insufficiency becomes clinically apparent between the 5th and 8th postoperative day [7]. Clinical signs such as fever, pain, ileus and laboratory findings such as elevated acute-phase

proteins, leucocytosis and increased serum creatinine are common but have a low positive predictive value. A serum albumin level <3.5 g/dl, anaemia <8 g/dl, hypotension, blood transfusion and the use of inotropes seem to be the most important non-surgical factors that are independently associated with an increased risk of anastomotic leakage [8]. Anastomotic leakage is associated with a high postoperative mortality ranging between 12–50% and resulting in a prolonged hospital and intensive care unit stay, which leads to increased hospital costs and negative outcomes such as the long-time survival and quality of life [9–11].

Due to the high clinical relevance of anastomotic leakage and its clear association with postoperative complications and mortality, a routine water-soluble contrast swallow

is performed in many surgical departments in the early post-operative period [12]. However, the clinical relevance of this examination in patients with no clinical signs and symptoms is debatable, since its sensitivity is documented to be low in comparison to an upper endoscopy or computed tomography (CT) [13,14].

The aim of this retrospective analysis was to assess the clinical relevance of a routinely performed water-soluble contrast swallow in the early post-operative period after gastric and esophageal surgery.

Material and Methods

The records of 104 consecutive gastric and esophageal resections for cancer of the upper gastrointestinal tract from January 2009 until December 2013 at our centre were retrospectively analysed. Only patients who were still intubated on the 5th postoperative day were excluded from the analysis, since these patients did not receive a contrast swallow. At the time of the study, an oral contrast swallow was performed in all patients after total gastrectomy and esophagectomy. A total number of 74 patients underwent total gastrectomy for gastric cancer (Figure 1). Of these 74 patients, 49 were male (66%) and 25 were female (34%). The median age of these patients was 70 (range 42–86) years. In the remaining 30 cases, esophagectomy for distal esophageal cancer was performed. Of these 30 patients, 25 were male (83%) and 5 were female (17%). The median age of these patients was 63 (range 22–79). In all 104 cases, an upper gastrointestinal contrast swallow with diatrizoic acid, which is a water-soluble contrast agent, was routinely performed on the 5th postoperative day. Extravasation

of the contrast agent during the swallow examination was defined as the detection of anastomotic leakage. Moreover, clinical parameters such as postoperative symptoms of anastomotic leakage (fever, tachycardia, abdominal pain), co-morbidities and the use of upper endoscopy and CT-scan were examined. An upper endoscopy was performed in all patients with a positive water-soluble contrast swallow to further evaluate the anastomosis, while all symptomatic patients with a negative water-soluble contrast swallow received a CT with oral contrast. Diagnostic accuracy was calculated based on the rate of true positive and true negative findings from our study and calculated for each theoretically possible percentage of anastomotic insufficiencies in a hypothetical group.

Results

Full datasets could be extracted from all 104 consecutive esophageal and gastric resections and all cases were included in this retrospective analysis.

In total, anastomotic leakage was seen in 15 patients (14.4%) with 7/74 (9.4%) cases after total gastrectomy and 8/30 (26.6%) cases after esophagectomy. In 97 patients, the oral water-soluble contrast swallow did not show any extravasation. However, in 12 of those patients, anastomotic leakage was identified after a CT-scan and upper endoscopy were performed due to clinical symptoms. In 7 cases, an extravasation after the water-soluble contrast swallow was detected. After an upper endoscopy was performed in these patients, only 3 of these cases had true positive findings (Figure 2). The sensitivity and specificity of the oral

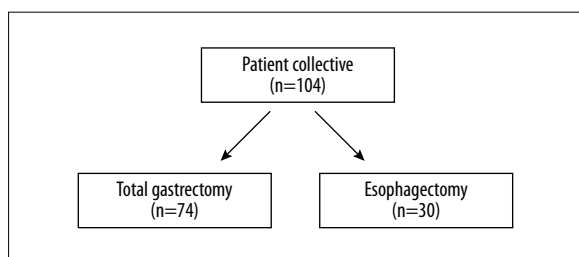


Figure 1. Patients grouped into total gastrectomies and esophagectomies.

Table 1. Statistical analysis of water-soluble contrast swallow.

False negatives, n	12
False positives, n	4
True negatives, n	85
True positives, n	3
Specificity, %	96%
Sensitivity, %	20%

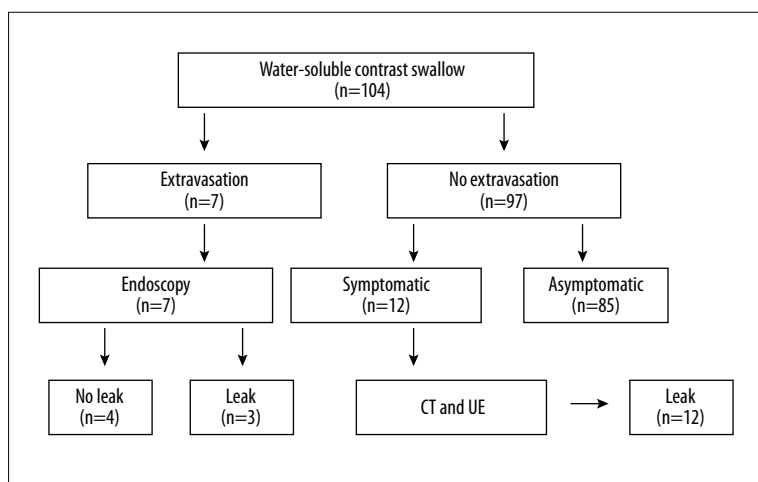


Figure 2. Flow-diagram of diagnostic screening in 104 patients.

Table 2. Efficiency of contrast swallow, computed tomography (CT) and upper endoscopy (UE).

	Positive CT/UE	Negative CT/UE	Total
Positive swallow	3	4	7
Negative swallow	12	85	97
Total	15	89	104

water-soluble contrast swallow was 20% and 96%, respectively (Table 1). The sensitivity of the upper endoscopy and CT was 100% (Table 2). Based on these findings, diagnostic accuracy of the oral contrast swallow was calculated for each percentage of patients with anastomotic leakage.

In 12 patients without extravasation after the water-soluble contrast swallow, anastomotic leakage was detected using a CT-scan, which was performed when clinical symptoms such as fever, increased leucocytes and acute-phase proteins or an acute abdomen were apparent. In all of those cases, upper endoscopy was performed and an anastomotic leakage was confirmed (Table 2). Nine patients were treated with a self-expanding metal stent, one patient needed a surgical revision, one patient was treated with endoluminal vacuum therapy and one patient did not require any intervention. Of the remaining three patients who had an anastomotic leakage and extravasation in the oral contrast swallow, 2 were treated using a self-expanding metal stent and one did not require any intervention.

Discussion

Anastomotic leakage and anastomotic insufficiency are considered to be the most serious complication after gastric or esophageal resection. Since mortality is increased, early detection and treatment in order to minimize morbidity is crucial. Therefore, a routine water-soluble contrast swallow is performed in many surgical departments following upper gastrointestinal surgery. Most centres carry out a radiological evaluation of the anastomosis within the first postoperative week [15]. Although the available evidence suggests that such a radiographic evaluation of the anastomosis with a water-soluble contrast swallow has a low sensitivity, it still is the current standard and was the first investigative technique used to detect postoperative complications such as insufficiency, stricture or stenosis in our department during the study period. It was routinely performed in all 104 patients on the 5th postoperative day.

The contrast agent of choice is diatrizoic acid, which is water-soluble and rapidly absorbed following extravasation. Barium can lead to intense inflammatory responses and cause granulomata formation in the mediastinum and therefore is reserved for other applications [16]. However, a water-soluble contrast is less radiopaque than barium and more rapidly absorbed following extravasation, which might result in false negative results [17]. This is in accordance with the findings demonstrated in this retrospective analysis. Several studies have shown that water-soluble agents were unable to detect 15–25% of thoracic and 50% of cervical esophageal insufficiencies [18]. In comparison, barium has a greater density than diatrizoic acid. Agha

et al. demonstrated that approximately 25% of anastomotic insufficiencies are detected when only barium is used [19,20].

In a prospective, blinded, intraindividually controlled diagnostic study carried out by Schaible et al., endoscopy was described as superior to the contrast study in detecting pathological findings after reconstruction and was possible in all patients without complications. Schaible et al. concluded that a radiologic contrast swallow in the early postoperative period is often not feasible, lacks further relevance and should be replaced by an endoscopic evaluation [21]. This is in accordance with other studies that identified leaks that remained asymptomatic even after reintroduction of oral feeding [13,14,22].

The present analysis demonstrates a higher rate of anastomotic leakage in intrathoracic anastomoses compared to intraabdominal anastomoses (26.6% vs. 9.4%, respectively). This is in accordance with the findings from other studies [23–25].

In the present study, the water-soluble contrast swallow had a very high false-negative rate and a low sensitivity. CT and upper endoscopy on the other hand were able to detect clinically relevant anastomotic leaks with a sensitivity of 100%. This might overestimate the true sensitivity of CT-scanning, since it has not been evaluated in this context as a routine tool and has been employed only when anastomotic leakage has been suspected. In general, employing any method to detect anastomotic leakage as a routine practice might not be reasonable, since smaller insufficiencies might be detected that are not clinically relevant. Moreover, CT-scans and endoscopy offer the advantage not to be used only as diagnostic tools, but also for the placement of interventional drainages, stents and endoluminal vacuum sponges. Because of its low sensitivity and low positive predictive value, a routine use of oral water-soluble contrast swallow examination after upper gastrointestinal surgery for evaluating anastomoses cannot be recommended. The current method of choice seems to be CT-scan and endoscopy. Therefore, a routine contrast water swallow is outdated and should not be performed for the evaluation of anastomoses. If there is no clinical suspicion for an anastomotic leakage, enteral feeding should be initiated. If a leak is clinically suspected (e.g. fever, leucocytosis, elevated CRP, suspicious fluid in the drain) a CT-scan with oral contrast should be performed. In addition to its diagnostic value, infectious fluid collections can be drained before managing the anastomotic leak via endoscopy (e.g. stenting vs. vacuum-therapy).

Conclusions

Taken together, this retrospective analysis does not support a routine use of water-soluble contrast swallow for the detection of anastomotic leaks after upper gastrointestinal surgery. Diatrizoic acid swallow performed on the 5th postoperative day has a poor sensitivity and a high false negative detection rate in predicting an anastomotic leak. Therefore, it cannot be recommended as a diagnostic tool. When an anastomotic insufficiency is suspected and

clinical signs such as fever, leucocytosis or sepsis are present, methods with a higher sensitivity such as a CT-scan and endoscopy should be employed.

Statement

There is no conflict of interest. There was no funding of this original research. An ethical approval was not required.

References:

- Lagarde SM, de Boer JD, ten Kate FJ et al: Postoperative complications after esophagectomy for adenocarcinoma of the esophagus are related to timing of death due to recurrence. *Ann Surg*, 2008; 247(1): 71–76
- Rizk NP, Bach PB, Schrag D et al: The impact of complications on outcomes after resection for esophageal and gastroesophageal junction carcinoma. *J Am Coll Surg*, 2004; 198(1): 42–50
- Koruda MJ, Rolandelli RH: Experimental studies on the healing of colonic anastomoses. *J Surg Res*, 1990; 48(5): 504–15
- Tagart RE: Colorectal anastomosis: Factors influencing success. *J R Soc Med*, 1981; 74(2): 111–18
- Wagner OJ, Egger B: Influential factors in anastomosis healing. *Swiss Surg*, 2003; 9(3): 105–13
- Urschel JD: Esophagogastronomy anastomotic leaks complicating esophagectomy: A review. *Am J Surg*, 1995; 169(6): 634–40
- Daams F, Luyer M, Lange JF: Colorectal anastomotic leakage: Aspects of prevention, detection and treatment. *World J Gastroenterol*, 2013; 19(15): 2293–97
- Choudhuri AH, Uppal R, Kumar M: Influence of non-surgical risk factors on anastomotic leakage after major gastrointestinal surgery: Audit from a tertiary care teaching institute. *Int J Crit Illn Inj Sci*, 2013; 3(4): 246–49
- Holscher AH, Vallbohmer D, Brabender J: The prevention and management of perioperative complications. *Best Pract Res Clin Gastroenterol*, 2006; 20(5): 907–23
- Karl RC, Schreiber R, Boulware D et al: Factors affecting morbidity, mortality, and survival in patients undergoing Ivor Lewis esophagogastrctomy. *Ann Surg*, 2000; 231(5): 635–43
- Singh D, Maley RH, Santucci T et al: Experience and technique of stapled mechanical cervical esophagogastric anastomosis. *Ann Thorac Surg*, 2001; 71(2): 419–24
- Bains MS: Ivor Lewis esophagectomy. *Chest Surg Clin N Am*, 1995; 5(3): 515–26
- Honing J, Pultrum BB, van der Jagt EJ et al.: Routine or on demand radiological contrast examination in the diagnosis of anastomotic leakage after esophagectomy. *J Surg Oncol*, 2009; 100(8): 699–702
- Tirnaksiz MB, Deschamps C, Allen MS et al: Effectiveness of screening aqueous contrast swallow in detecting clinically significant anastomotic leaks after esophagectomy. *Eur Surg Res*, 2005; 37(2): 123–28
- Sauvanet A, Baltar J, Le Mee J, Belghiti J: Diagnosis and conservative management of intrathoracic leakage after oesophagectomy. *Br J Surg*, 1998; 85(10): 1446–49
- Ginai AZ, ten Kate FJ, ten Berg GM, Hoornstra K et al: Experimental evaluation of various available contrast agents for use in the upper gastrointestinal tract in case of suspected leakage: Effects on mediastinum. *Br J Radiol*, 1985; 58(691): 585–92
- Dodds WJ, Stewart ET, Vlymen WJ: Appropriate contrast media for evaluation of esophageal disruption. *Radiology*, 1982; 144(2): 439–41
- Phillips LG, Jr., Cunningham J: Esophageal perforation. *Radiol Clin North Am*, 1984; 22(3): 607–13
- Agha FP, Orringer MB: Colonic interposition: Radiographic evaluation. *Am J Roentgenol*, 1984; 142(4): 703–8
- Agha FP, Orringer MB, Amendola AM: Gastric interposition following transhiatal esophagectomy: radiographic evaluation. *Gastrointest Radiol*, 1985; 10(1): 17–24
- Schaible A, Sauer P, Hartwig W et al: Radiologic versus endoscopic evaluation of the conduit after esophageal resection: A prospective, blinded, intraindividually controlled diagnostic study. *Surg Endosc*, 2014; 28(7): 2078–85
- Lamb PJ, Griffin SM, Chandrashekar MV et al: Prospective study of routine contrast radiology after total gastrectomy. *Br J Surg*, 2004; 91(8): 1015–19
- Biere SS, Maas KW, Cuesta MA, van der Peet DL: Cervical or thoracic anastomosis after esophagectomy for cancer: A systematic review and meta-analysis. *Dig Surg*, 2011; 28(1): 29–35
- Klink CD, Binnebösel M, Otto J et al: Intrathoracic versus cervical anastomosis after resection of esophageal cancer: A matched pair analysis of 72 patients in a single center study. *World J Surg Oncol*, 2012; 10: 159
- Lantos JE, Levine MS, Rubesin SE et al: Comparison between esophagography and chest computed tomography for evaluation of leaks after esophagectomy and gastric pull-through. *J Thorac Imaging*, 2013; 28(2): 121–28