



Received: 2016.07.24
Accepted: 2016.09.09
Published: 2017.06.16

Authors' Contribution:

- A** Study Design
- B** Data Collection
- C** Statistical Analysis
- D** Data Interpretation
- E** Manuscript Preparation
- F** Literature Search
- G** Funds Collection

A Newborn with an Alternative Porto-Caval Shunt

Çağrı Damar^{1AEE}, Ayşe Gül Alımlı^{2AEE}, Betül Emine Derinkuyu^{2AEE}, Kudret Ebru Özcan^{3AEE},
Asburçe Olgaç^{4AEE}, Ali Murat Koç^{5AEE}

¹ Department of Radiology, Gaziantep Children's Hospital, Gaziantep, Turkey

² Division of Pediatric Radiology, Department of Radiology, Medical Faculty, Gazi University, Ankara, Turkey

³ Division of Neonatology, Department of Pediatrics, Medical Faculty, Gazi University, Ankara, Turkey

⁴ Division of Inborn Errors of Metabolism and Nutrition, Department of Pediatrics, Gazi University, Medical Faculty, Ankara, Turkey

⁵ Department of Radiology, Gazi University, Faculty of Medicine, Ankara, Turkey

Author's address: Çağrı Damar, Department of Radiology, Medical Faculty, Gazi University, 06500, Beşevler, Ankara, Turkey,
e-mail: cagridamar@hotmail.com

Summary

Background:

Absent ductus venosus (ADV) is a rare condition, but it should be known that this embryonic anomaly may be detected by fetal echocardiographic or newborn ultrasound examinations.

Case Report:

We present a baby with an ADV and an accompanying alternative porto-caval shunt between the right portal vein and inferior vena cava detected on postnatal ultrasound examination.

Conclusions:

Variations in the fetal umbilical or porto-systemic circulations should be detected by fetal or newborn ultrasound examinations and kept in mind before common interventions such as UV catheterizations.

MeSH Keywords:

Catheterization • Portal System • Single Umbilical Artery • Ultrasonography, Doppler • Umbilical Veins

PDF file:

<http://www.polradiol.com/abstract/index/idArt/900726>

Background

The physiological role of the ductus venosus (DV) is to carry some portion of oxygenated umbilical venous blood to the right atrium as an embryonic porto-caval shunt. We present a newborn with the absence of ductus venosus and an accompanying alternative porto-caval shunt.

Case Report

A baby born at 37 weeks, one of twins, was admitted to the intensive care unit with tachypnea and hypothermia with an increased hematocrit (70%). He had a single umbilical artery detected on fetal ultrasound examinations, but no other accompanying anomalies were identified.

Abdominal ultrasound findings were as follows: dilations of the right-left portal vein, a thin hypoechoic tract between the right portal vein and inferior vena cava (IVC) (Figure 1A). Color Doppler US confirmed blood flow in these vessels (Figure 1B, 1C). The DV was not detected in the normal anatomical location. It became clear that the tract was

an alternative intrahepatic porto-caval shunt that was carrying oxygenated blood from the right portal vein to the IVC during fetal life. Blood flow through the shunt gradually decreased on follow-up Doppler ultrasound examinations which closed on the 33rd day since birth and became a thin, hyperechoic ligamentous structure equivalent to the 'ligamentum venosum' (Figure 1D).

Discussion

DV is an embryonic vessel which connects the umbilico-portal confluence to the IVC. The umbilico-portal confluence connects the umbilical vein (UV) and fetal left portal vein, also known as the portal sinus (PS) [1]. Normally, the aperture of the UV and the ostium of the DV are aligned in PS (Figure 1E) [2]. Thus, in utero, some portion of oxygenated blood from the placenta flows through the PS into the DV and then to the IVC, bypassing the liver. DV also regulates the blood flow rate in order to prevent the fetus from volume overload. Absence of DV with variations in direct blood flow from UV to IVC (or heart) can lead to high output cardiac failure and hydrops fetalis [3,4]. Functional

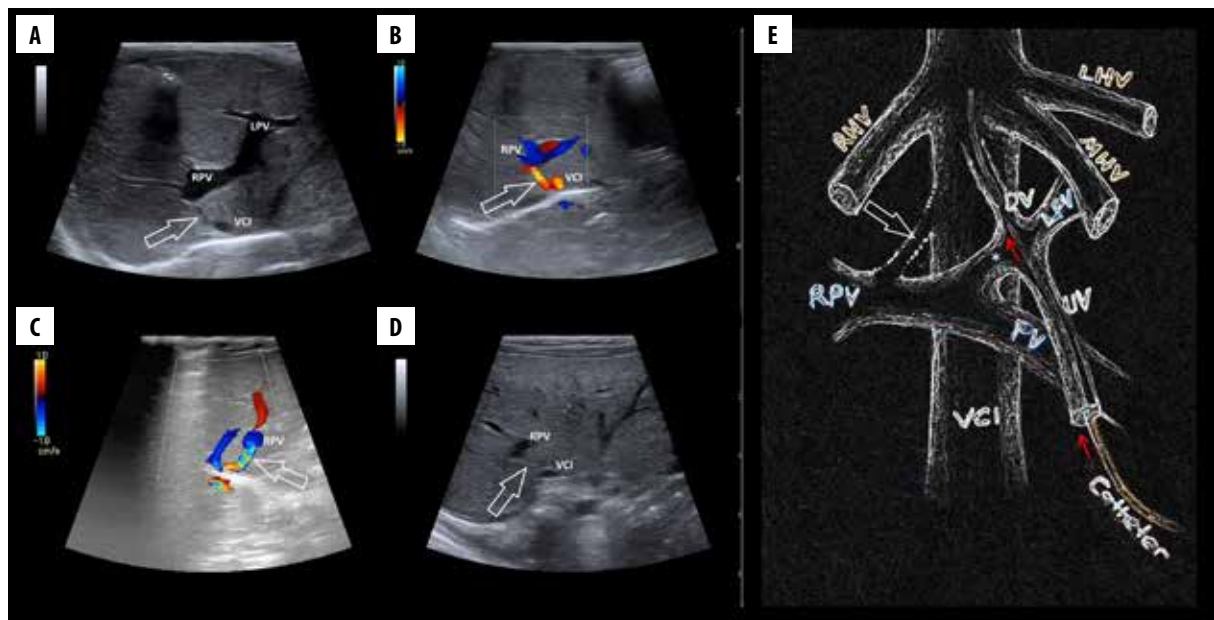


Figure 1. B mode ultrasound image (A) shows the hypoechoic tract (arrow) which is extending from R PV to the IVC. Color Doppler ultrasound images (B, C) reveal blood flowing from R PV to IVC via this porto-caval shunt (arrows). B mode ultrasound image obtained on the 33rd day after birth (D) shows that the shunt closed and became a fibrotic ligamentous structure (arrow). Illustration (E) shows the normal pathway of umbilical vein catheterization (red arrows) and the abnormally located shunt (white open arrow). IVC – vena cava inferior; R HV – right hepatic vein; M HV – middle hepatic vein; L HV – left hepatic vein; P V – portal vein; R P V – right portal vein; L P V – left portal vein; U V – umbilical vein; D V – ductus venosus; * portal sinus.

closure of the DV occurs shortly after birth, however, anatomical closure takes several weeks. It may be delayed due to some factors such as prematurity, genetics, accompanying cardiac malformations and prematurity [1].

UV catheterization is common and is performed normally in a straight trace through the following vessels: UV, left portal vein, DV, IVC (Figure 1E). The catheter tip is preferably placed at the IVC-right atrium junction [5]. UV catheterization was not required in our case, but if it had been needed, the process would have quite possibly been complicated by an abnormal course of alternative porto-caval shunt.

Moreover, persistent intrahepatic porto-caval shunts may lead to an increase in toxic metabolites and cause hypergalactosemia or hyperammonemia upon initiation of enteral feeding [6]. Therefore, if the shunt had not closed spontaneously, an intervention may have been required in this case. However, the flow rate of the shunt gradually

decreased and it closed on follow-up Doppler ultrasound examinations.

One study determined the prevalence of absent ductus venosus to be 0.6% in fetal echocardiographic examinations. Moreover, it identified five anatomic variants of abnormal fetal porto-systemic connections [7], one of which was similar but not identical to the connection found in our patient. Some cardiac and extracardiac comorbidities have also been described in the literature (cardiomegaly, duodenal atresia, intestinal malrotation, etc.), but our patient had none of them [3,4,7].

Conclusions

Variations of the fetal umbilical or porto-systemic circulations should be revealed by fetal or newborn ultrasound examinations and kept in mind before interventions such as UV catheterizations.

References:

- Collardeau-Frachon S, Scoazec JY: Vascular development and differentiation during human liver organogenesis. *Anat Rec (Hoboken)*, 2008; 291(6): 614–27
- Mavrides E, Moscoso G, Carvalho JS et al: The anatomy of the umbilical, portal and hepatic venous systems in the human fetus at 14–19 weeks of gestation. *Ultrasound Obstet Gynecol*, 2001; 18(6): 598–604
- Oztunc F, Gokalp S, Yuksel MA et al: Absent ductus venosus in the fetus. *J Obstet Gynaecol*, 2014; 34: 741
- Jatavan P, Kemthong W, Charoenboon C et al: Hemodynamic studies of isolated absent ductus venosus. *Prenat Diagn*, 2016; 36: 74–80
- Schlesinger AE, Braverman RM, DiPietro MA: Pictorial essay. Neonates and umbilical venous catheters: normal appearance, anomalous positions, complications, and potential aid to diagnosis. *Am J Roentgenol*, 2003; 180(4): 1147–53
- Yoshimoto Y, Shimizu R, Saeki T et al: Patent ductus venosus in children: A case report and review of the literature. *J Pediatr Surg*, 2004; 39(1): E1–5
- Acherman RJ, Evans WN, Galindo A et al: Diagnosis of absent ductus venosus in a population referred for fetal echocardiography: Association with a persistent portosystemic shunt requiring postnatal device occlusion. *J Ultrasound Med*, 2007; 26(8): 1077–82