

CASE REPORT

Use of ultrasound in differential diagnosis of soft tissue foreign bodies in children – a case series

Agata Maria Kawalec

Department of Anatomy, Institute of Medical Sciences, University of Opole, Opole, Poland

ABSTRACT

There are many types of foreign bodies found in soft tissues in children. Ultrasound is a very useful tool in diagnosis. The article presents a series of cases – children with foreign bodies located in soft tissues – in which the diagnosis was confirmed with the use of ultrasound. Different features of different foreign bodies can provide information about the foreign body type (gravel, glass, wooden splinter, metal). The foreign bodies could be successfully removed under local anesthesia.

Ultrasound can be used to confirm the presence of soft tissue foreign bodies in suspected patients. Moreover, the features of the image can provide information about the foreign body type. In the pediatric population, the main advantage of ultrasound is the reduction of X-rays performed.

KEY WORDS:

children, foreign body, ultrasound, soft tissue.

INTRODUCTION

Penetrating foreign body injuries in children are common [1]. Many types of foreign bodies can be found in soft tissues in children, e.g. metal, ceramic, stone, wood, plastic, clothing, flesh, bone, or vegetable matter [1, 2].

Since sometimes they do not cause acute symptoms, the diagnosis and the removal can be delayed [1]. The prolonged presence of the foreign body in the soft tissues can cause complications. For example, cellulitis, deep tissue infection, sinus, restriction of joint movements, necrotizing fasciitis, osteomyelitis, or tumor-like masses can be found [1].

Taking a medical history can be challenging. The parents are not always sure that the foreign body can be present in the soft tissues. Moreover, the child does not always remember the moment of the injury. In case of suspicious foreign bodies in the soft tissue, diagnostic imaging is very useful and can confirm the diagnosis. Among the diagnostic tools used to confirm the diagnosis are X-ray, ultrasonography (USG), computed tomography (CT) scan,

and magnetic resonance imaging (MRI) [1]. However, MRI is generally contraindicated for initial evaluation of foreign bodies until one ensures they are not ferromagnetic. The advantage of ultrasound is the reduction of exposure to electromagnetic waves and the fact that general anesthesia is not required to perform the examination. Moreover, it is an accessible and relatively cheap diagnostic tool. Ultrasound guidance is useful for a rising number of pediatric emergency medicine procedures [3]. The increasing role of ultrasound was confirmed during care of patients with SARS-CoV-2 virus infections [4]. Lung ultrasound was a very useful diagnostic tool, called “the stethoscope of the 21st century” [4].

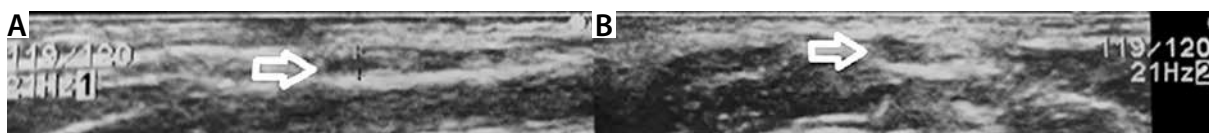
CASE REPORTS

CASE 1

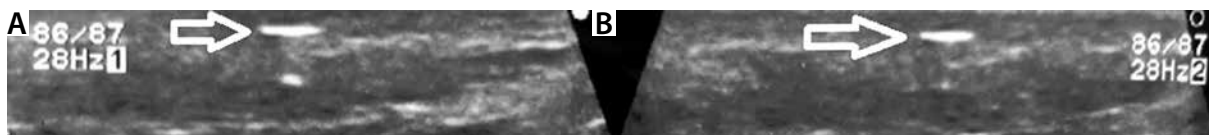
A 7-year-old girl with a small round tumorous mass on the right side of the neck was observed for 2 weeks. The parents tried to remove the spike of the plant. But

ADDRESS FOR CORRESPONDENCE:

Agata Maria Kawalec, PhD, Department of Anatomy, Institute of Medical Sciences, University of Opole, 48 Oleska St., 45-052 Opole, Poland, e-mail: agata_kawalec@wp.pl



FIGURES 1A, B. An ultrasound examination of the neck revealed a tiny stone found under the skin (arrows). Scanner type – Aloka; transducer used – linear



FIGURES 2A, B. Ultrasound examination of the right hand's soft tissues in the area of a palpated thickening revealed the hyperechoic structure 3.9 mm × 5.2 mm × 0.4 mm (arrows). Scanner type – Aloka; transducer used – linear

they were able to fully evacuate the foreign body. The inflammation around the lesion decreased. The girl had no fever. Allergies to drugs were not found. She was vaccinated according to the Immunization Program.

During the visit, on the right side of the girl's neck, a small soft tissue nodule was present. It was moderately painful during palpation. The skin had slightly damaged epidermis. A dark spot (spike?) was visible through the skin. Signs of inflammation were not seen. Local lymph nodes were not enlarged.

In ultrasound, the change had a diameter of 0.27 mm × 0.14 mm and was demarcated from the surrounding tissues. There were no features of increased flow in the CD option (Figures 1A, B).

The patient was qualified for revision under local anesthesia. Under local anesthesia, a foreign body – a tiny stone – was removed. The postoperative course was uncomplicated.

CASE 2

The case concerns a 12-year-old boy, who 2 months previously injured his right hand as a result of a fall on a construction site. The wound affected the skin and the soft tissues near the 5th metacarpal bone. The wound had healed, but the boy complained of pain in this area. The child suspected that soft tissue, probably gravel, was present.

In the soft tissues near the proximal epiphysis of the 5th right metacarpal bone, a palpable thickening was present. The boy said it was painful at the time of palpation. The surrounding skin was without signs of inflammation.

An ultrasound examination of soft tissues in the area of a palpated thickening revealed the hyperechoic structure 3.9 mm × 5.2 mm × 0.4 mm (Figures 2A, B).

The presence of a foreign body was also confirmed in the X-ray (Figure 3).

The patient was scheduled for revision under local anesthesia. Under local anesthesia, a foreign body – glass – was removed. The postoperative course was uncomplicated.

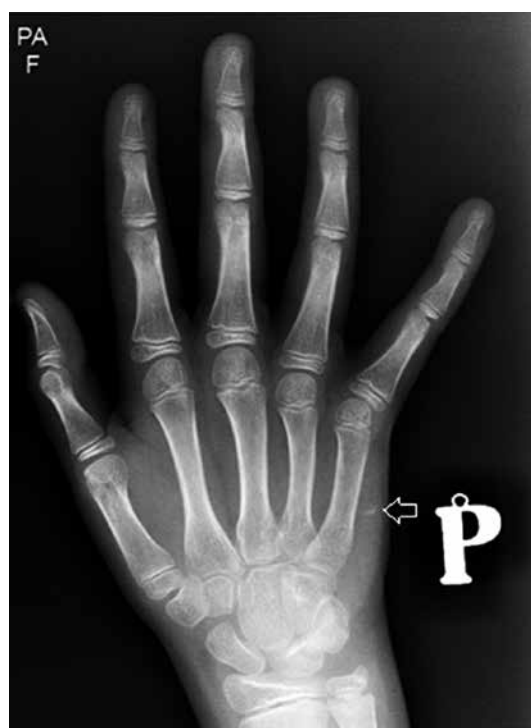

FIGURE 3. A foreign body is seen in the X-ray (arrow)

CASE 3

The case concerns a 9-year-old boy, who about 3 months previously suffered an injury – a foreign body (splinter) stuck in the right thigh while sitting on a wooden bench. He reported pain when sitting on his right thigh on a hard metal chair. In June this year, a fragment of a splinter was removed by his family doctor. The patient did not have a fever. The patient was not vaccinated.

During the physical examination, a slight thickening of tissues of the right thigh was present. The skin over the lesion had a bruise, and there were no signs of inflammation.

The ultrasound performed in the region of palpable thickening revealed a hyperechogenic structure (foreign body) surrounded by a hypoechogenic structure (proba-

bly fluid). The diameter of the finding was approximately 1 mm × 1 mm × 8 mm. The image corresponds to an encapsulated foreign body (splinter). The patient was scheduled for surgery under local anesthesia – removal of the foreign body.

CASE 4

A 7-year-old girl had her ears pierced 4 months previously. For about 3 weeks she could not find the plug of the right earring. Due to the painful thickening of the right ear lobe, ingrowth of the earring in the right earlobe was suspected. A few days before the visit, leakage of purulent content from the earlobe was present.

In the ultrasound, hyperechoic structures were seen. The diameter of the structures was similar to the diameter of the earplug from the left earring (2.8 mm × 1.6 mm × 4.2 mm).

The ingrown earring was successfully removed under local anesthesia.

DISCUSSION

A variety of foreign bodies can be found in children. The caregivers are not always able to establish the date and circumstances of the situation. Moreover, in the case of foreign bodies such as gravel or glass, the number of foreign bodies can be difficult to establish. Thus, it seems advisable to perform imaging of the suspected area.

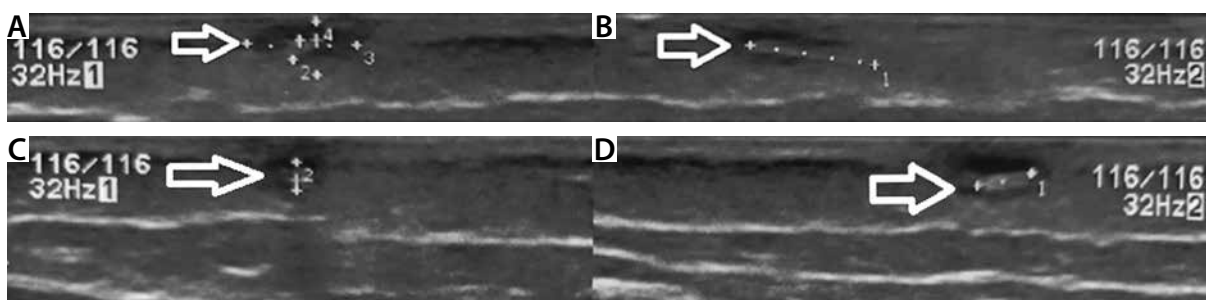
According to Rooks *et al.*, the use of USG in cases of suspected soft-tissue foreign bodies provides excellent detection, localization, and characterization of soft-tissue foreign bodies [2]. The ultrasound-guided foreign body removal is a minimally invasive procedure that facilitates the treatment and helps to avoid complications [2]. A variety of methods used to detect soft tissue foreign bodies can be found in the literature. For example, Su *et al.* performed a randomized controlled trial to compare the effects of using methylene blue as a marker to find and remove tiny metallic foreign bodies embedded in the soft tissues of children in comparison to the traditional methods (using a C-arm) [5]. According to their results, the methylene blue method significantly reduced operation time, incision length, and radiation exposure compared to the conventional method [5].

However, ultrasound seems to be a very good diagnostic option in the detection of soft tissue foreign bodies [1–3, 6, 7]. The advantage is not only the reduction of exposure to the X-rays, but also the possibility to establish the relationship between adjacent structures such as muscles, tendons, bone, and vessels [7]. Also, the Doppler mode can be used when needed [7]. The description of the relationship between adjacent structures and the foreign body can be difficult on the basis of X-ray examination. More detailed imaging tests, such as CT, are related to exposure to radiation, which should be avoided when unnecessary. Performing MRI is more expensive and requires general anesthesia in younger children.

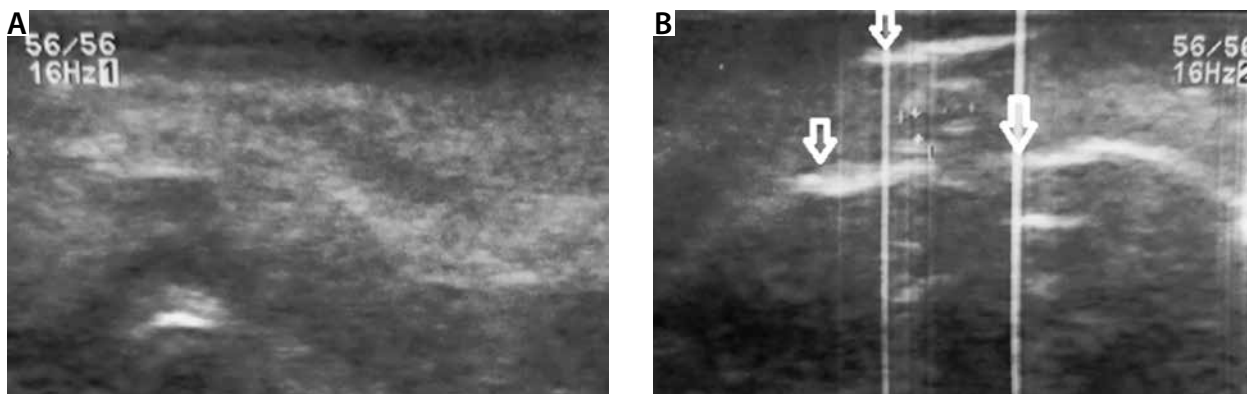
A very detailed examination is necessary to detect foreign bodies (especially very small ones), because minimally echogenic foreign bodies can be sonographically subtle and mistaken as a muscle fibril or fascial tissue plane [2]. Shiels *et al.* proposed the use of small standoff pads to facilitate the localization on small surfaces [6]. Among possible distractions are gas, proteinaceous echogenic fluid, or multiple small foreign bodies [2]. Also very important is co-operation with parents during the examination. The cooperative patient and caregivers can facilitate adequate visualization, which is crucial for successful foreign body diagnosis and removal [8].

Ultrasound has become the imaging technique of choice for evaluating suspected foreign bodies [9]. It must be underlined that, thanks to ultrasound, it is possible to detect foreign bodies that are not seen in the X-ray. X-rays are useful for imaging radiopaque foreign bodies (metal, glass, plastics) of a certain size. The foreign bodies detected in the ultrasound can present different degrees of echogenicity. The degree of echogenicity of the foreign body seen in the ultrasound depends on the object's material and thickness and the angle of insonation [9].

Wooden foreign bodies can be seen as linear echogenic structures with pronounced acoustic shadowing [7, 10–12]. The presence of acoustic shadowing is seen behind the foreign body and is caused by the surface attributes of the foreign body rather than its composition [8]. It can be observed that smooth surfaces generate dirty acoustic shadows, while irregular surfaces and those with a small radius of curvature produce clean shadows [8, 13]. It is important to underline that wood and other organic foreign bodies lose echogenicity over time [13].



FIGURES 4A–D. The ultrasound image corresponds to an encapsulated foreign body (splinter). Scanner type – Aloka; transducer used – linear



FIGURES 5A, B. The ingrown earring seen in the ultrasound (arrows). Scanner type – Aloka; transducer used – linear

Moreover, the foreign bodies can be surrounded by hypoechoic halos caused by edema, abscess, or granulation tissue [6]. A hypoechoic halo can be seen in Patient 3 (Figures 4A–D). According to del Cura *et al.*, a hypoechoic halo is frequently observed around the echogenic foreign body present within the soft tissues for over 24 hours and is caused by perilesional inflammation [9]. The presence of a hypoechoic halo can help detect the foreign body location because the size of the lesion is bigger [9].

Hyperechoic comet-tail artifacts (reverberation artifacts) can be seen in the case of metallic foreign bodies and glass fragments [6]. They are frequently depicted with metal or glass foreign bodies with a flat surface and depend on the angle of insonation [8]. Metal foreign bodies are highly hyperechogenic and generate a comet-tail artifact or reverberation due to their smooth surface [13]. The reverberations caused by the metallic foreign body can be observed in Patient 4 (Figures 5A, B). Glass foreign bodies are hyperechogenic and can present a reverberation artifact as was seen in Patient 2 (Figures 2A, B) [13].

Gravel produces acoustic shadowing on ultrasound. Thorns and splinters are generally hyperechogenic. However, their echogenicity is lower than that of the foreign bodies from glass and metal. Plastic foreign bodies appear hyperechoic with posterior acoustic shadowing [13].

To avoid false positives it is necessary to remember several ultrasound findings which may mimic the presence of a foreign body. The most common diagnostic errors during ultrasound assessment are calcifications, sesamoid bones, scar tissue, acute hematomas, intermuscular septa, hyperechogenic muscle fibers, and air trapped in the soft tissue [13].

An important aspect of the problem of foreign bodies found in children is the negative attitude of some parents to the Immunization Program. It is important to check the vaccination status of the child in case of a dirty wound affecting the skin and soft tissues [8]. Unfortunately, some children are not vaccinated despite the obligatory vaccination against tetanus in the Polish Immunization Program.

The problem of ingrown earrings in children, mostly girls, is related to the improper care of the earlobe after

the piercing. Piercing in minors is a controversial issue. Among the possible complications related to improper aseptic piercing technique, insufficient training, and trauma to the soft tissue during high pressure are infections, bleeding, and microfractures [14]. Other possible complications are embedded earrings, keloids, hypertrophic scarring, and cutaneous hypersensitivity [14]. Children who are unable to remove the earrings on their own may suffer due to an ingrowing earring plug. The clinical presentation of embedded earrings (usually the back side of the earring) usually features red, swollen, and painful edema present on the posterior side of the earlobe [14]. In addition, in the case of earrings made of base metals, inflammation or allergic reaction may occur [15]. It seems that in children who are not mature enough to take care of the earrings on their own, the earrings can cause unnecessary medical visits and procedures.

CONCLUSIONS

Ultrasound can be used to confirm the presence of soft tissue foreign bodies in suspected patients. Moreover, the features of the image can provide information about the foreign body type. In the pediatric population, the main advantage of ultrasound is the reduction of X-rays performed. The experience of the medical provider and the cooperation with the caregiver are crucial to establish the diagnosis and provide successful treatment.

DISCLOSURE

The authors declare no conflict of interest.

REFERENCES

1. Yhosu E, Chaudhary G, Gupta MK. Retained wooden foreign body in groin in a child: a case report and review of literature. *Afr J Paediatr Surg* 2020; 17: 127-130.
2. Rooks VJ, Shiels WE, Murakami JW. Soft tissue foreign bodies: a training manual for sonographic diagnosis and guided removal. *J Clin Ultrasound* 2020; 48: 330-336.

3. Shaahinfar A, Ghazi-Askar ZM. Procedural applications of point-of-care ultrasound in pediatric emergency medicine. *Emerg Med Clin North Am* 2021; 39: 529-554.
4. Przybył M, Machura E. Lung ultrasound in children. *Pediatr Pol* 2022; 97: 39-43.
5. Su Y, Nan G. Using methylene blue as a marker to find and remove tiny metallic foreign bodies embedded in the soft tissues of children: a randomised controlled trial. *Int J Surg* 2016; 29: 43-48.
6. Shiels WE, Babcock DS, Wilson JL, et al. Localization and guided removal of soft-tissue foreign bodies with sonography. *Am J Roentgenol* 1990; 155: 1277-1281.
7. Pan P. Ultrasound-guided percutaneous removal of soft-tissue foreign bodies in children. *J Indian Assoc Pediatr Surg* 2021; 26: 436-438.
8. Rupert J, Honeycutt JD, Odom MR. Foreign bodies in the skin: evaluation and management. *Am Fam Physician* 2020; 101: 740-747.
9. Del Cura JL, Aza I, Zabala RM, et al. US-guided localization and removal of soft-tissue foreign bodies. *Radiographics* 2020; 40: 1188-1195.
10. Peterson JJ, Bancroft LW, Kransdorf MJ. Wooden foreign bodies. *Am J Roentgenol* 2002; 178: 557-562.
11. Park HJ, Lee SM, Lee SY, et al. Ultrasound-guided percutaneous removal of wooden foreign bodies in the extremities with hydro-dissection technique. *Korean J Radiol* 2015; 16: 1326-1331.
12. Tantray MD, Rather A, Manaan Q, et al. Role of ultrasound in detection of radiolucent foreign bodies in extremities. *Strateg Trauma Limb Reconstr* 2018; 13: 81-85.
13. Marín-Díez E, Landeras Álvaro RM, Lamagrande Obregón A, et al. Ultrasonography of subcutaneous foreign bodies: differences depending on their nature, complications, and potential diagnostic errors. *Ecografía de los cuerpos extraños subcutáneos: diferencias según naturaleza, complicaciones y potenciales errores diagnósticos*. *Radiologia (Engl Ed)* 2020; 62: 3-12.
14. Kim MM, Goldman RD. Ear-piercing complications in children and adolescents. *Can Fam Physician* 2022; 68: 661-663.
15. Wennervaldt M, Ahlström MG, Menné T, et al. Nickel release from metallic earrings: a survey of the Danish market and validation of the nickel spot test [published online ahead of print, 13.03.2021]. *Contact Dermatitis* 2021; 10.1111/cod.13832.