

Fusion of a maxillary canine with a geminated central incisor

Złanie kła w szczęce z bliźniaczym zębem siecznym przyśrodkowym

Aydin Gülses¹, Mustafa Ayna²

¹ Aydin Gülses: Dental Service, Sarikamis State Hospital, Kars, Turkey
Przychodnia Stomatologiczna, Szpital Sarikamis State, Kars, Turcja
Head: dr A. Gülses

² Private practice in general dentistry and implantology, Duisburg-Zentrum, Germany
Prywatna praktyka stomatologii ogólnej i implantologii, Duisburg-Zentrum, Niemcy
Head: dr M. Ayna

Abstract

The aim of this paper is to present a unique case of a fused maxillary canine with a geminated central incisor. Dental abnormalities collectively form a body of knowledge with which all dentists should be familiar. Each condition should be discussed and clarified in order to determine the classification and specific management options.

Streszczenie

Celem pracy jest przedstawienie szczególnego przypadku, w którym kiel w szczęce uległ złaniu z bliźniaczym siekaczem przyśrodkowym. Anomalie zębowe to wiedza, która nie powinna być obca żadnemu dentyście. Każda patologia powinna być omówiona i wyjaśniona w celu ustalenia jej klasyfikacji i metod postępowania.

KEYWORDS:

fusion, gemination, impacted canine

HASŁA INDEKSOWE:

zęby złane, zęby bliźniacze, zatrzymany kiel

Introduction

Many congenital and developmental abnormalities resulting in alterations of the size, shape and number of teeth have been described in the dental literature. In spite of clinically being often confused with each other, fusion and gemination are two well described dental abnormalities. While fusion is the joining of two adjacent tooth germs to form a single large tooth, gemination is an attempt by a single tooth germ to form two teeth. In order to overcome the correct determination of both entities, counting of the teeth is usually recommended. If a tooth is missing, it is fusion, if one is not missing, it is gemination. In both

situations, anterior maxilla is the most commonly involved region.

The aim of this paper is to present a unique case of a fused maxillary canine with a geminated central incisor.

Case report

A 22-year-old healthy male was referred to the Dental Service at Mevki Military Hospital due to a chronic abscess involving the lower first molar tooth. The tooth was extracted and the adjacent inflammatory granulation tissue was curetted. On the first week follow-up examination, an abnormality of the upper central incisor was noted.

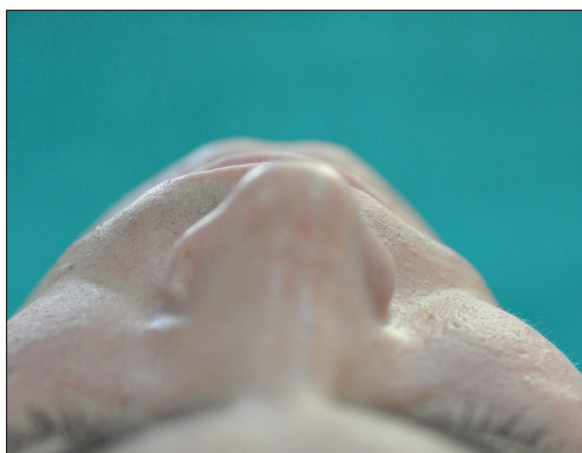

Fig. 1. Extra-oral view of the patient. Please note the asymmetry of the upper lip.

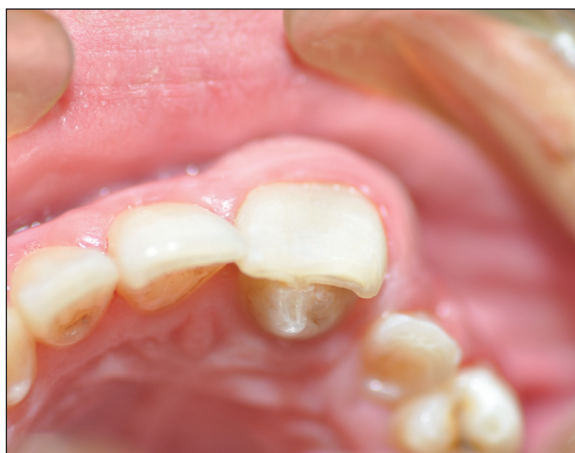

Fig. 2. Intra-oral view.

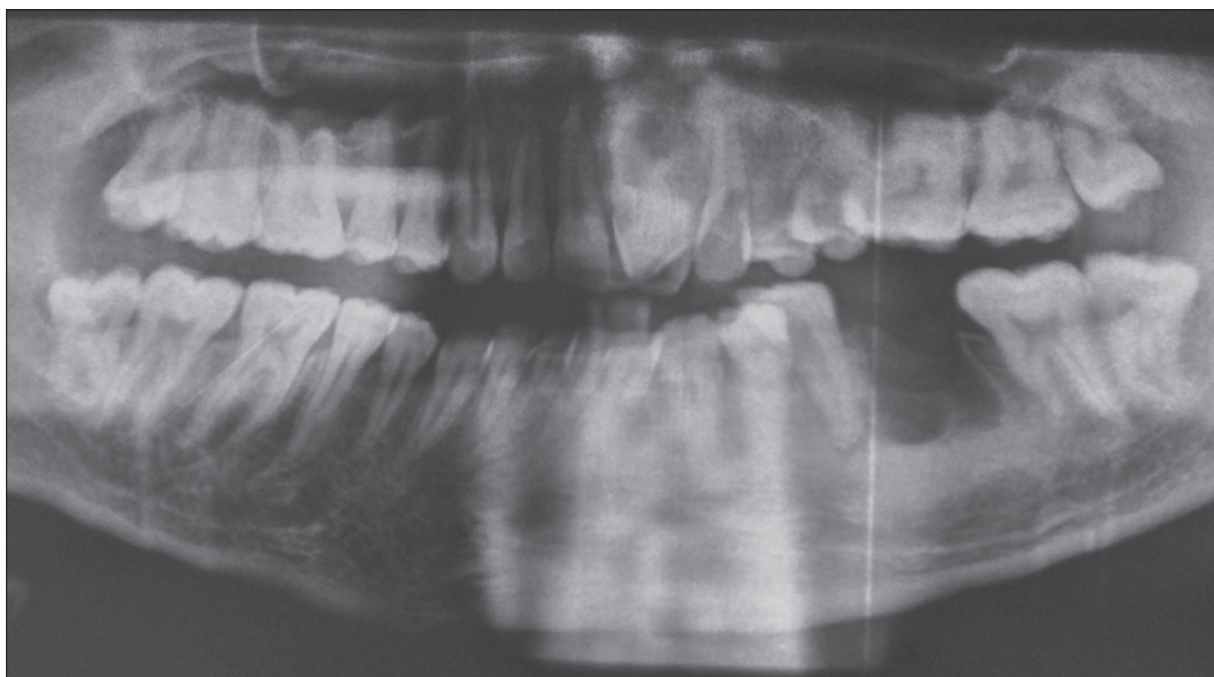

Fig. 3. Orthopantomogram of the patient.

On the extra-oral examination, an asymmetry secondary to a slight bulking on the left side of the upper lip was present (Fig. 1).

Careful intra-oral examination revealed a huge, geminated left central incisor in conjunction with a palatally located tooth-like structure. An

examination of the dental arch showed that the left maxillary canine was missing (Fig. 2).

Panoramic and periapical radiographs revealed ill-defined opaque, calcified masses with two roots and canals resembling a fused canine and a central incisor (Fig. 3, 4) No impaction of the canine was

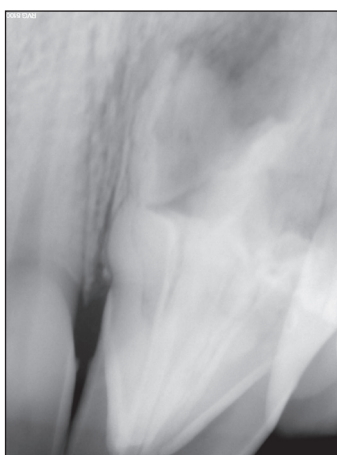


Fig. 4. Periapical radiograph of the patient.

seen on the left side. The patient denied having symptoms such as swelling or pain.

After consultations with the Department of Prosthetics and the Department of Orthodontics, it was decided to remove the teeth and insert a dental implant following alignment of the maxillary dental arch. However, the patient refused to undergo dental therapy and the condition was left untreated. The patient was informed about the condition and discharged.

Discussion

Fused teeth arise from the union of two normally separated tooth germs, and depending upon the stage of development of the teeth at the time of union, it may be either complete or incomplete. As described in the present case, on some occasions, two independent pulp chambers and root canals can be seen. In the current case, the maxillary canine had its characteristic morphogenetic form and shape, both clinically and radiographically.

It is well known that maxillary canines are one of the most malpositioned teeth following the mandibular and maxillary wisdom teeth.¹ Considering the development and the eruption process of the maxillary canine, it can be speculated that the entity reported herein might have resulted from a traumatic fusion of the canine to the central incisor, which continued by a transection of the central incisor resembling gemination.

The cross-sectional histopathological examination would provide more detailed information about the current entity; however, according to the patient's decision, the condition remained untreated. In conclusion, the first case of a fusion with a geminated tooth has been described herein. Dental abnormalities collectively form a body of knowledge with which all dentists should be familiar.² Each condition should be discussed and clarified in order to determine the classification and specific management options.

References

1. Bedoya MM, Park JH: A review of the diagnosis and management of impacted maxillary canines. *J Am Dent Assoc* 2009; 140: 1485-1493.
2. http://dentistry.umkc.edu/Practicing_Communities/asset/AbnormalitiesofTeeth.pdf

Address: Mevki Military Hospital, 06130 Diskapi Altindag, Ankara, Turkey
Tel.: +905326954048, Fax:+903123114609
e-mail: aydingulses@gmail.com

Received: 4th February 2016

Accepted: 3rd August 2016