

# ACTIVATED IRRIGATION BY GENTLEFILE DURING ROOT CANAL THERAPY

Agata Koprowicz, Halina Pawlicka, Joanna B. Grącka-Mańkowska

Department of Endodontics, Medical University of Łódź, Poland

## ABSTRACT

**INTRODUCTION:** The development of modern dentistry has changed the nature of endodontic therapy. Formerly arduous and strenuous root canal treatment has become a sequence of precise procedures, usually with no, or negligible, side-effects. The introduction of rotary nickel-titanium (NiTi) files onto the market has considerably shortened the time of canal preparation. Unchangeably, the mechanical preparation is aimed at shaping the canal, having preserved its original curvature, removing the infected tissue from the root canal system, and allowing dense and homogeneous obturation of the canal. Regardless of the cross-section of traditional rotary files, it has been confirmed that contact zones of rotary NiTi instruments never negotiate the canal walls in their entirety. The remaining wall surface of the canal is intact and therefore remains untreated. To improve the root canal disinfection, the preparation stage should include a chemical phase with the use of rinsing agents. Current published research findings indicate that activation of the irrigation solutions improves their cleansing properties. As a consequence, many researchers constantly develop the new methods and aim for new equipment to allow efficient irrigation of the root canal system.

**CASE DESCRIPTION:** The article presents four clinical cases managed with the use of a new instrument called the Gentlefile (MedicNRG, Israel), which serves not only for mechanical preparation but also for the activation of rinsing agents during endodontic treatment.

**CONCLUSIONS:** After completing the mechanical preparation of the root canals, the application of the appropriate protocol of rinsing seems to be an elementary stage for successful endodontic treatment. Activation of rinsing agents with the Gentlefile, by improving the effectiveness of cleaning, enables an impermeable, fluid tight seal within the entire root canal, increasing the success rate in endodontic treatment.

**KEY WORDS:** irrigation, Gentlefile, root canal therapy.

J Stoma 2019; 72, 1: 34–42

DOI: <https://doi.org/10.5114/jos.2019.86495>

## INTRODUCTION

The main goal of endodontic treatment is to remove the irreversibly inflamed pulp, disinfect the root canals, and shape them, which will enable three-dimensional obturation, healing of periapical lesions, and protection against reinfection [5]. Both manual and mechanical canal preparation results in the creation of the smear

layer (of different thickness) on the walls of the canal [17]. Studies confirm that removal of the smear layer by activation of rinsing agents increases the adhesion of the filling material and reduces the occurrence of micro-leakage along the canal wall [6]. Various methods of activation of the rinsing agents are described in the literature, some of which are as simple as mixing the solutions using a gutta-percha cone or an irrigation

**JOURNAL OF  
STOMATOLOGY**  
CZASOPISMO STOMATOLOGICZNE

OFFICIAL JOURNAL OF THE POLISH DENTAL ASSOCIATION | ORGAN POLSKIEGO TOWARZYSTWA STOMATOLOGICZNEGO



ADDRESS FOR CORRESPONDENCE: Agata Koprowicz, Department of Endodontics, Medical University of Łódź, 251 Pomorska St., 92-213 Łódź, Poland, e-mail: [agata.koprowicz@umed.lodz.pl](mailto:agata.koprowicz@umed.lodz.pl)

RECEIVED: 27.01.2019 • ACCEPTED: 26.05.2019 • PUBLISHED: 28.06.2019

needle, and others are as sophisticated as expensive laser-based protocols. There are ultrasonic and sonic devices [7, 11], flexible micro-brushes [8, 17], and innovative files such as the Self-Adjusting File (ReDent-Nova, Israel) or the XP-endo Finisher (FKG, Switzerland) [1, 19]. Recently, MedicNRG (Israel) has introduced a product called the Gentlefile, which is a rotary endodontic system (Figure 1). It consists of a wireless micro-motor, a disposable head, and a set of steel files. An inconspicuous and very light micro-motor achieves the rotation speed of up to 6500 rpm, which, besides being used for root canal preparation, can be applied to activate rinsing agents. The highest theoretically achievable torque is 90 Gr/cm; however, when a file is blocked, a specially programmed controller decreases the speed of the machine automatically. The file set consists of six disposable files of innovative design (022/20 mm, 034/25 mm, 029/25 mm, 026/25 mm, 023/25 mm, and 021/25 mm), which are formed by rolled-up steel wire made of several layers with a delicate abrasive surface. The files are inserted into the micro-motor without any lock, which allows the micro-motor head to be removed when the file is blocked in the curved canal. In such a case, to remove the file from the canal, the file should be manually rotated in a clockwise direction. Its tip establishes only the direction of preparation, which decreases the risk of perforation. The root canal is prepared by the crown-down method using three files, with a three- to five-time insertion of each instrument (“pecking motion”) for about five seconds. An additional element in the kit is the Gentlefile brush, consisting of seven steel filaments rolled around its axis. According to the manufacturer’s instructions, it mainly serves to activate rinsing agents. The Gentlefile brush is suitable for cleaning canal walls during endodontic re-treatment or root canal preparation in order to perform a prosthetic post and core restoration.

The aim of the study was to present four cases of endodontic treatment with usage of the Gentlefile system as an irrigating solution activator.

## CASE DESCRIPTION

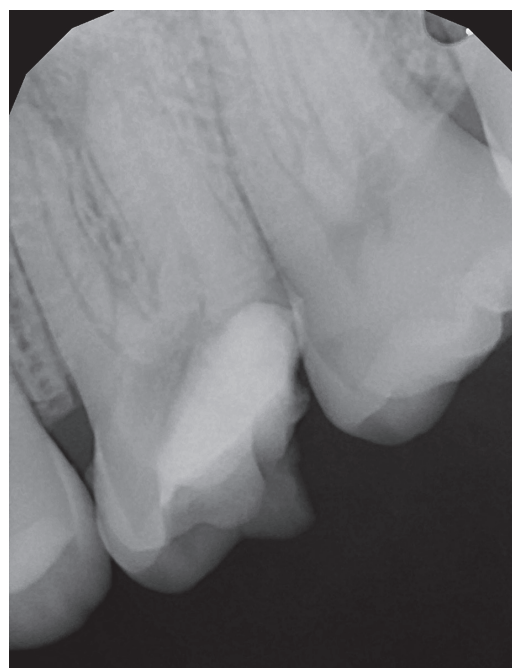
### CASE 1

A patient, aged 29 years, was referred by a general dental practitioner in April 2017 to have the specialist endodontic treatment of tooth 26 performed. The medical history showed no clinical significance. The root canal treatment had been started about six months earlier. The patient admitted that for financial reasons and due to his negligence, he did not continue the treatment. On the day of the appointment, the tooth was asymptomatic. The X-ray revealed extensive destruction of the tooth crown and inflammatory lesions in the periapical tissues (Figure 2). The examination confirmed the radiographic result, and palpation showed a slight and tender swelling

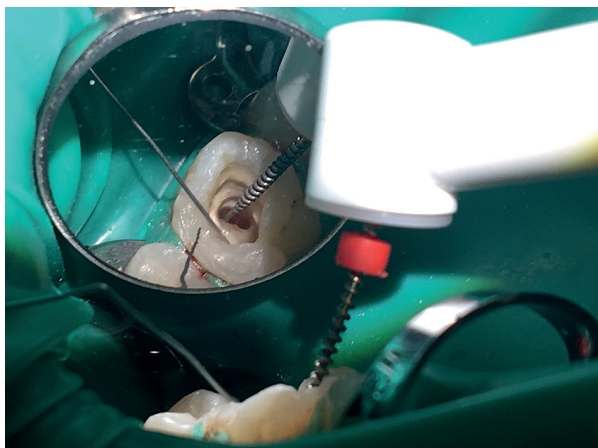

**FIGURE 1.** The Gentlefile system: files and micro-motor

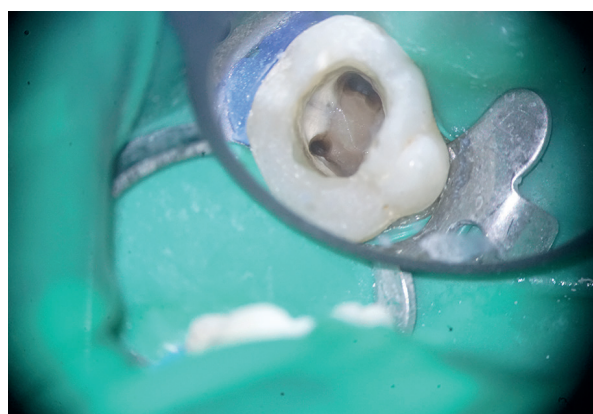in the vestibule region. However, no pathological mobility of tooth 26 was observed. The shared patient-doctor decision was made to perform root canal treatment. After the preparation of the carious lesion, the wall on the disto-occlusal surface was restored with Evetric A2 (Ivoclar Vivadent, Liechtenstein), followed by rubber dam placement. Using an OPMI PROergo microscope (Zeiss, Germany), the additional canal (MB2) was found and the localisation of the other root canals, i.e. mesiobuccal, distobuccal, and lingual (MB1, DB, and L), was confirmed; their working length was measured using an Endopilot (Schlumbohm GmbH & Co., KG, Germany). Canal preparation was performed with C-pilot hand files (VDW, Germany): 8.02, 10.02, 15.02 and Reciproc R25 file (VDW, Germany). During the mechanical preparation each canal was rinsed with 6 ml



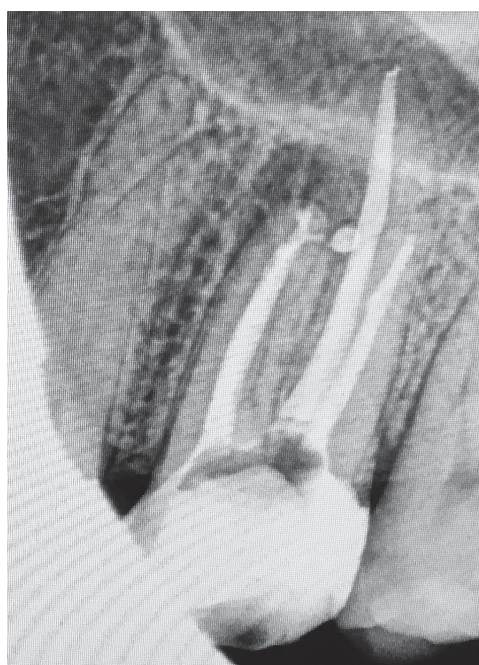**FIGURE 2.** X-ray of tooth 26 before root canal treatment (April 2017)



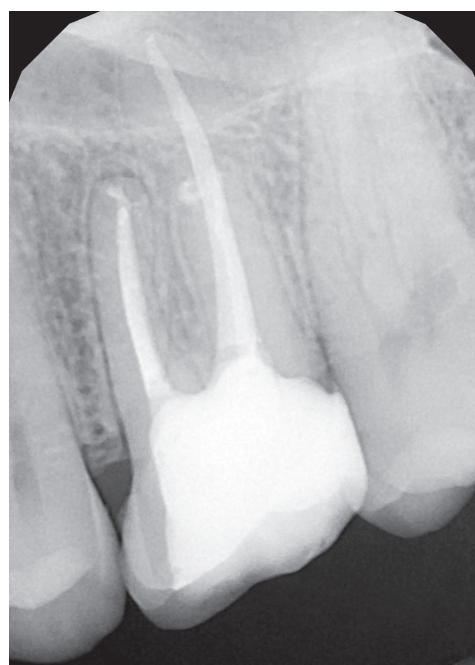
**FIGURE 3.** The Gentlefile activation of the rinse solution



**FIGURE 4.** The connection of canals MB1 and MB2 before obturation using continuous wave method



**FIGURE 5.** X-ray of tooth 26 after canal obturation



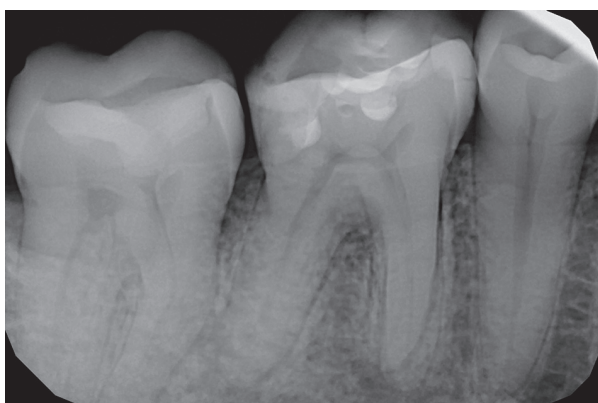
**FIGURE 6.** Control X-ray of tooth 26 after 9 months

of 5.25% sodium hypochlorite solution (CHLORAXiD, Cerkamed, Poland). To remove the smear layer 6 ml of 17% EDTA solution (Endo-Solution, Cerkamed, Poland) was used and activated with Gentlefile (size 023) for two minutes (Figure 3). The last irrigation was performed with 2 ml of 5.25% sodium hypochlorite solution per canal and activated for two minutes by Gentlefile (size 023), which was introduced at the working length. A sterile sponge was placed in the pulp chamber and it was temporarily closed with Cavit (3M, ESPE, USA). Five days after the visit, the patient began to feel severe pain, and soft tissue swelling also appeared. After submucosal abscess incision, the patient visited the dental office several times for a change of surgical dressing. Antiseptic root canal treatment was continued during antibiotic therapy, the canals were prepared to

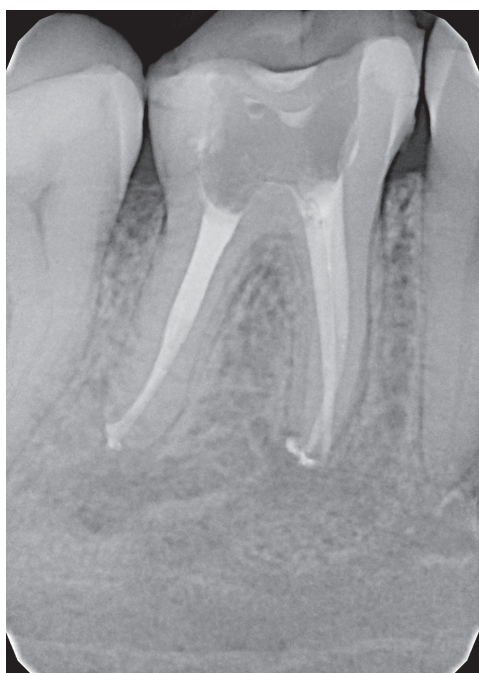the following sizes: MB1 and MB2 – 50.02, DB – 40.02, L – 45.02 and the antibiotic-corticosteroid material was applied (Figure 4). After another two weeks, the canal system was filled with gutta-percha and AH Plus sealer (Dentsply, USA) using the lateral compaction technique (of lingual and buccal canals) and continuous wave method (DownPack and BackFill with Endopilot) (of joined MB1 and MB2 canals). Canal orifices were marked with flowable resin composite material and FUJI IX GP (GC, Japan). The control X-ray confirmed a tight and homogeneous filling, with a slight overflow of the sealer around the mesiobuccal root (Figure 5). The patient was referred to have the final restoration performed and the follow-up was recommended. The first control X-ray of tooth 26 was taken after nine months (Figure 6).

## CASE 2

In March 2017, a 34-year-old patient, with medical anamnesis of no clinical significance, was referred to the Department of Endodontics at the Medical University of Lodz for root canal treatment of tooth 46. The patient reported severe, spontaneous pain aggravated by heat and biting. X-ray did not reveal any periapical lesions (Figure 7). Clinical examination was conducted using pulp testing: the ethyl chloride test and electrical test with a Pulp Tester (VDW, Germany). The electrical test gave a false positive result due to the presence of humid necrotic pulp. Infiltration and block anaesthesia were performed (Citocartin 100, Molteni Dental, Poland). After field isolation using a rubber dam, the access to the pulp chamber and the orifices of mesiobuccal

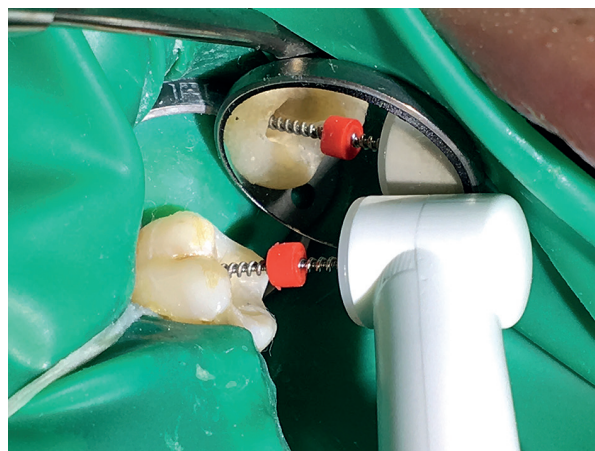


**FIGURE 7.** X-ray of tooth 46 before endodontic treatment (April 2017)

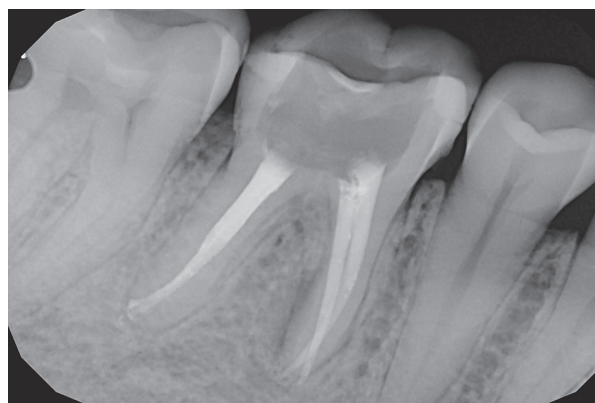

**FIGURE 9.** X-ray of tooth 46 after endodontic treatment

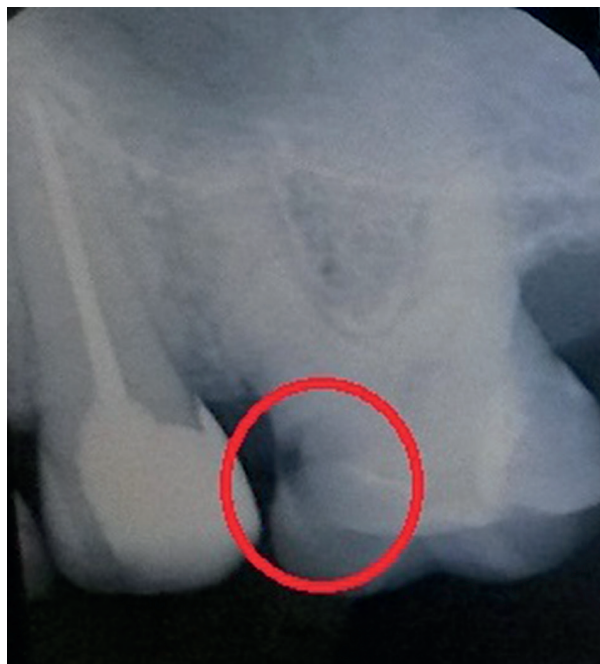(MB), mesiolingual (ML), and distal (D) canals were found and prepared using Gates Glidden burs (sizes 1 # and 2 #) (Mani, Japan). C-Pilot files of sizes 08.02, 10.02, and 15.02 were used to measure the working length of the canals (Raypex 5 apex locator, VDW, Germany). The chemo-mechanical preparation of the root canals was performed by ProGlider (16.02), ProTaper Next X1 (17.04), and X2 (25.06) instruments (Dentply, USA), rinsing with 2.5% sodium hypochlorite (CHLORAXiD) and 17% EDTA (Endo-Solution). Calcium hydroxide temporary dressing was introduced into the canals, a sterile cotton pellet was placed into the pulp chamber and a Fuji IX GP (GC, Japan) temporarily closed the cavity. During the next appointment, the final canal preparation using ProTaper Next (Dentply, USA) X2 and X3 (30.07) instruments was performed, activating all of the above-mentioned rinsing agents by the Gentlefile (023) in the same manner as in the first case (Figure 8). The canals were filled with thermoplasticised gutta-percha and AH Plus sealer using the Endopilot. The canal orifices were covered with a flowable composite material and a temporary glass-ionomer (Fuji IX). The follow-up X-ray showed a tight, homogeneous filling of the canals with a slight overfill of the sealer in the apical area



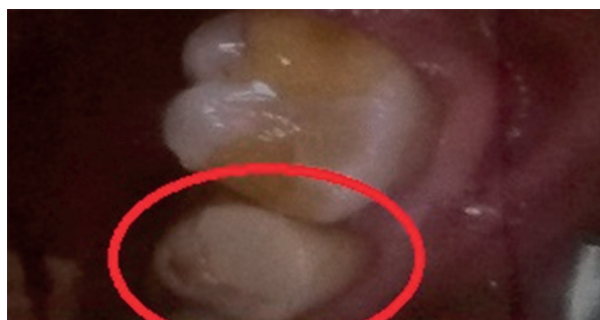**FIGURE 8.** Activation of rinsing solution with the Gentlefile



**FIGURE 10.** Control X-ray of tooth 46 after 12 months



**FIGURE 11.** X-ray of tooth 26 before root canal treatment (July 2016)



**FIGURE 12.** Photograph of teeth 25 and 26 before endodontic therapy of tooth 26

(Figure 9). The control X-ray of tooth 46 was taken after 12 months (Figure 10).

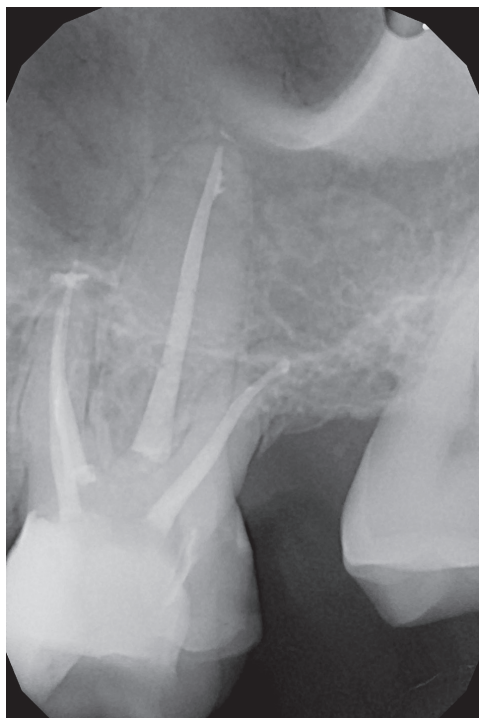
### CASE 3

A patient, aged 45 years, presented to the dental office for comprehensive dental treatment including prosthetic and implant reconstruction. The medical history was collected, and a clinical examination was completed with intraoral photographs and X-rays (Figures 11 and 12). The patient did not report any pain. Caries reaching the pulp horn was observed in tooth 26. During the removal of caries, the pulp tissue was exposed. After caries tissue removal, the missing wall was rebuilt with Evetric A3 (Ivoclar, Vivadent, Liechtenstein) and the pulp was covered with antibiotic-steroid cream. During the next visit, local anaesthesia was performed with Ubistesin

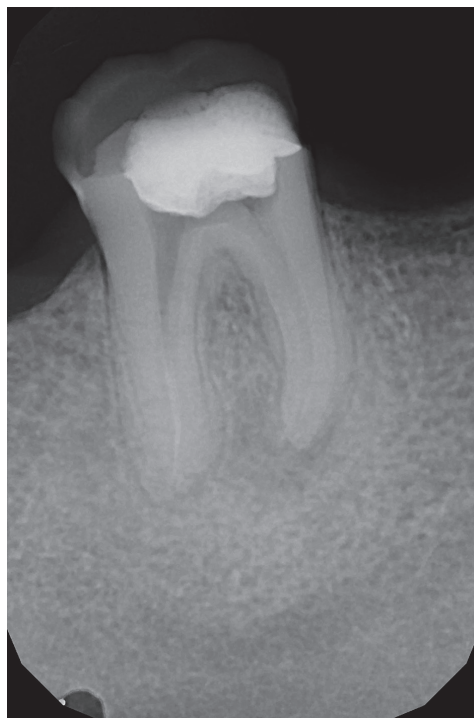forte (1 amp, 3M ESPE, USA), and then the tooth was isolated with a rubber dam, and straight-line access to four canals (MB1, MB2, DB, L) was achieved using magnifying loupes (2.5x, Heine, Germany). Single-appointment root canal treatment was performed. Chemo-mechanical canal preparations were used with Reciproc R25 (25.08) and R50 (50.05) (VDW, Germany) and rinsing agents in following sequence as 2.5% sodium hypochlorite (CHLORAXiD) and 17% EDTA (Endo-Solution) and 2.5% sodium hypochlorite (CHLORAXiD) (10 ml NaOCl and 2 ml EDTA per canal). Both irrigating agents were activated with the Gentlefile (026) for two minutes at the working lengths. Canal obturation was performed using 4% taper gutta-percha cones previously coated with AH Plus sealer, and then the canals were filled with gutta-percha heated to 150°C with the use of an Endopilot. The canal orifices were covered with a flowable composite material and the pulp chamber with a RIVA LC material (SDI, Australia). The X-ray image confirmed the correct filling with a small amount of the gutta-percha material extruded beyond the apex of the MB root canal (Figure 13). Due to the further planned dental treatment CBCT was performed after seven months (Figure 14).

### CASE 4

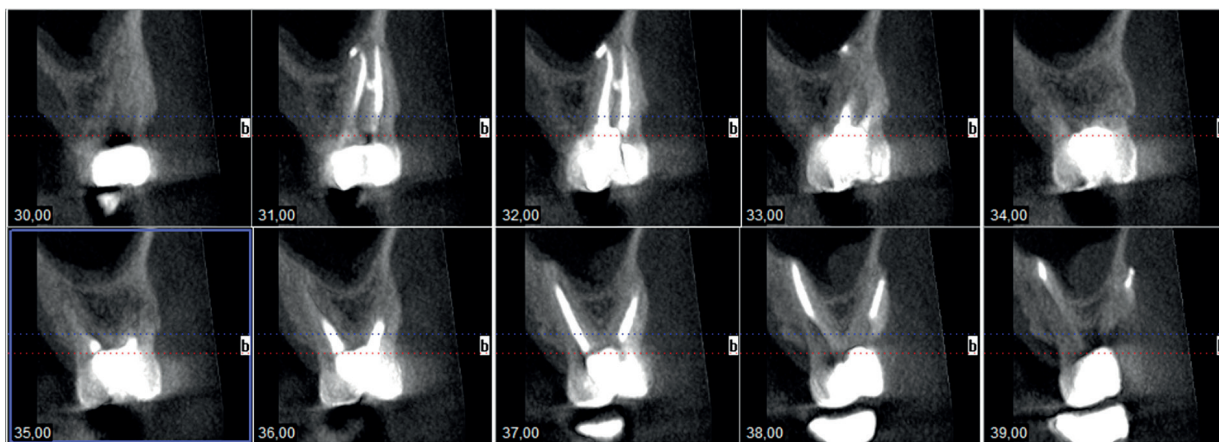
A 40-year-old patient came to the dental office in April 2017 to continue treatment of tooth 46. Canal treatment had been started in 2015; however, the patient did not continue the treatment. After a detailed conversation with the patient, a shared patient-doctor decision was made to perform re-treatment. The current X-ray revealed the presence of secondary caries and periapical lesions (Figure 15). The patient did not report any pain and no oedema was found on an intra-oral examination. Endodontic re-treatment was performed in a rubber dam under the operating microscope (Leica, Germany). The mechanical canal preparation of four root canals (MB, ML, DB, and DL) was performed using Reciproc R50 files (50.05) (Endopilot) and 5.25% sodium hypochlorite solution (CHLORAXiD) as well as 15% EDTA (Endo-Solution) (10 ml NaOCl and 2 ml EDTA per canal). The Gentlefile (021) was used for both solution activations at the working lengths for two minutes (Figure 16). The canals were filled with gutta-percha and AH Plus root canal sealer using continuous wave compaction (Endopilot), and the orifices were covered with Flow Berry composite material (Arkona, Poland). The cavity was filled with Ketac Molar glass-ionomer (3M ESPE, USA). The control X-ray showed a tight, homogeneous filling of the canals with a slight overflow of the material into the periapical region (Figure 17). According to the implantologist's and prosthodontist's reconstructive dental plan, CBCT was taken three months after the root canal treatment (Figure 18).



**FIGURE 13.** X-ray of tooth 26 after canal obturation (March 2017)



**FIGURE 15.** X-ray of tooth 46 before treatment

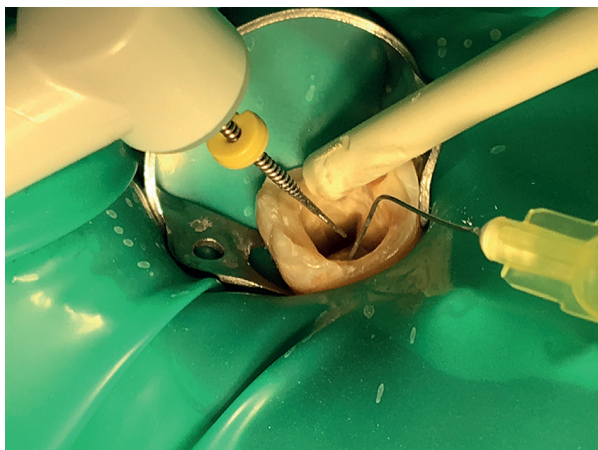


**FIGURE 14.** Cone beam computed tomography after 7 months

## DISCUSSION

The use of nickel-titanium rotary files for endodontic therapy resulted in a significant reduction of treatment time dedicated to root canal shaping [14]. The research proves that during the mechanical preparation of root canals, the contact surface of the rotary files with the canal wall is about 40-45% [12]. To achieve the best possible disinfection of the root canal system, the saved time should be used for so-called active irrigation. Recently, the importance of using special syringe infusion pumps (B. Braun, Germany), which continuously provide rinsing agents, or the activation of solutions by using various devices have been discussed.

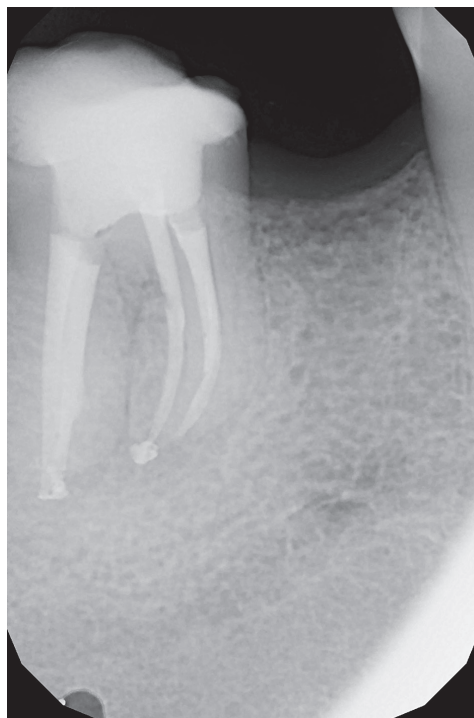
After mechanical preparation, canal walls are covered with the smear layer that contains dentinal or pulpal residues and microorganisms [17]. The presence of this layer, particularly in the apical region of the canal, is disadvantageous from the clinical point of view because the bacteria colonising the smear layer may contribute to the failure of the root canal therapy. In addition, this layer obliterates the dentinal tubules and reduces the effect of rinsing agents, having an impact on both the quality of filling and the effect of endodontic treatment [16]. Physical and chemical properties of the rinsing solutions allow the smear layer to be dissolved and partially removed [13]. It is necessary to use a combination of two rinsing agents, a disinfectant such as sodium



**FIGURE 16.** Photograph taken during the Gentlefile activation with continuous irrigation of sodium hypochlorite

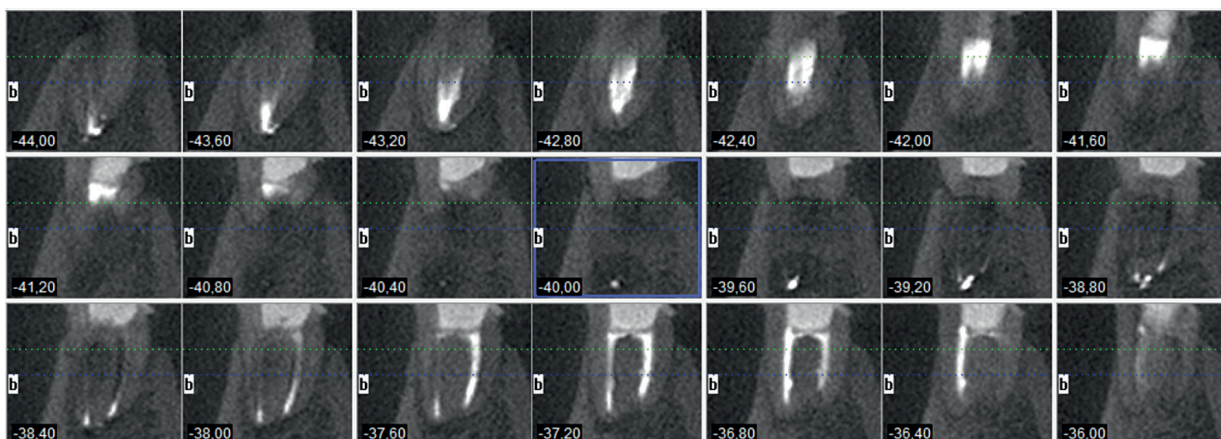
hypochlorite, and a chelating solution such as EDTA or citric acid. Sodium hypochlorite removes the organic part of the smear layer, including bacteria, while the chelating solution eliminates the inorganic part. Additional activation of rinsing solutions increases their effect. Research confirms that removal of the smear layer from the walls of the canal by activating the rinsing agent increases the adhesion of the filling material and reduces the occurrence of microleakage along the canal wall [2, 6].

The presented clinical cases describe the use of the Gentlefile to activate sodium hypochlorite, remove the smear layer, and provide better disinfection of the root canal and the canal obturation. In all cases, the canals were filled with the same method (the continuous wave method, except distal and lingual canals in the first case), the same material (gutta-percha and AH Plus paste as a sealer), and by the same operator. The Gentlefile can be used to activate rinsing agents in both primary root canal treatment and endodontic re-treatment. The Gentlefile has to be selected according to its size (the files are 021, 023, and 026) as well as to the working time. The manufacturer recommends activation of a solution in each canal for 20-30 seconds, using the smallest file,



**FIGURE 17.** X-ray of tooth 46 after endodontic treatment

which was applied during the root canal preparation procedures mentioned above. In the cases presented, sodium hypochlorite and EDTA were activated for 60-120 seconds with a constant flow of solutions in the amount of 10 ml per root canal, due to permanent cooperation with a professional dental assistant. Until now, there have not been many extensive pre-clinical or clinical studies conducted on the Gentlefile system. There is a study comparing the fracture strength of the file during simulated canal preparation [9], which indicates that the time and the amount of rotation of Gentlefile, after which file fracture occurs, are greater than those of compared NiTi instruments. In the authors' opinion, therefore, there is a need to study and specify the effects of the system on canal preparation as well as the activation of rinsing.



**FIGURE 18.** Cone beam computed tomography taken 3 months after the root canal treatment

In literature, traditional rinsing activation methods, such as manual irrigation with a gutta-percha cone or needle irrigation, are compared extensively with passive ultrasound irrigation or laser irradiation [7, 15]. Research shows that none of the devices used removes the biofilm completely; however, the best results are achieved with Passive Ultrasonic Irrigation (56.6% of the non-smear layer surface compared to Nd: Yag laser 30%, CanalBrush, Coltene Whaledent, Germany – 23.4%, and ProTaper Universal, Dentsply Maillefer, Switzerland – 13.4%) [15]. Another study comparing Aseptim Plus, Laser Diode, and ultrasonic activation confirms these results [4]. The comparison of the efficacy of removal of calcium hydroxide from the root canals using different methods of rinsing activation shows that the cleanliness was obtained in  $80.9 \pm 25.9\%$  in the PUI group, while in the CanalBrush and EndoActivator groups (Dentsply Maillefer, Switzerland) it was from 45% to 49.1% [18].

Various root canal irrigation devices are currently present on the dental market. Among others, the proposed file is XP-endo finisher (FKG, Switzerland), which, according to studies, enables effective removal of the biofilm from hard-to-reach areas [19], and provides better results than passive ultrasonic irrigation [10]. The Self-Adjusting File (Re-Dent-Nova, Israel) may be a competitive product because there are studies proving its superiority over other methods (EndoVac, Discus Dental, Culver City, CA or passive ultrasonic irrigation) [3].

The Gentlefile, which is a rotary endodontic system, serves for the mechanical canal preparation. According to the manufacturer's instructions, it may agitate canal irrigation solutions as well. Therefore, the authors are introducing this system to clinics gradually. The file's properties ensure good results in efficacy of rinsing activation; however, it is a new system that still requires clinical and laboratory analyses. Compared to NiTi files, the production of stainless-steel files is more cost-effective, and therefore the price of the system is reduced. Thanks to its innovative design and high elasticity, the instrument can reach deeper areas in the canal system, improving its cleanliness. Due to the small number of studies published on the use of the system, further observations and comparative analyses are required.

## CONCLUSIONS

Activation of rinsing agents using the Gentlefile system is one of the new methods available in the dental market. In addition to the mechanical preparation of root canals, the system is said by the manufacturer to enhance the rinsing effect during root canal treatment. Because of its ease of use, low cost, and positive therapeutic effects, it can become an alternative tool for dentists. However, further research is required because the Gentlefile is a novel product.

## CONFLICT OF INTEREST

The authors declare no potential conflict of interests with respect to the authorship and/or publication of this article.

## References

- Ahmetoğlu F, Şimşek N, Keleş A, Ocak MS, Er K. Efficacy of self-adjusting file and passive ultrasonic irrigation on removing calcium hydroxide from root canals. *Dent Mater J* 2013; 32: 1005-1010.
- Baldissera R, Rosa RA, Wagner MH, et al. Adhesion of real seal to human root dentin treated with different solutions. *Braz Dent J* 2012; 23: 521-526.
- Bao P, Shen Y, Lin J, Haapasalo M. In vitro efficacy of XP-endo Finisher with 2 different protocols on biofilm removal from apical root canals *J Endod* 2017; 43: 321-325.
- Da Costa Lima GA, Aguiar CM, Câmara AC, Alves LC, Dos Santos FAB, Do Nascimento AE. Comparison of smear layer removal using the Nd:YAG Laser, ultrasound, ProTaper Universal System, and CanalBrush methods: an in vitro study. *J Endod* 2015; 41: 400-404.
- Fleming CH, Litaker MS, Alley LW, Eleazer PD. Comparison of classic endodontic techniques versus contemporary techniques on endodontic treatment success. *J Endod* 2010; 36: 414-418.
- Fróes JA, Horta HG, da Silveira AB. Smear layer influence on the apical seal of four different obturation techniques. *J Endod* 2000; 26: 351-354.
- Guerisoli DM, Marchesan MA, Walmsley AD, Lumley PJ, Pecora JD. Evaluation of smear layer removal by EDTAC and sodium hypochlorite with ultrasonic agitation. *Int Endod J* 2002; 35: 418-421.
- Kamel WH, Kataia EM. Comparison of the efficacy of smear clear with and without a canal brush in smear layer and debris removal from instrumented root canal using WaveOne versus ProTaper: a scanning electron microscopic study. *J Endod* 2014; 40: 446-450.
- Moreinos D, Dakar A, Moshonov J, Stone NJ. Evaluation of time to fracture and vertical forces applied by a novel gentlefile system for root canal preparation in simulated root canals *J Endod* 2016; 42: 505-508
- Muhammad Omid H, Chevalier M, Rocca JP, Brulat-Bouchard N, Medioni E. Photodynamic therapy versus ultrasonic irrigation: Interaction with endodontic microbial biofilm, an ex vivo study. *Photodiagnosis Photodyn Ther* 2014; 11: 171-185.
- Neuhaus KW, Liebi M, Stauffacher S, Sigrun E, Lussi A. Antibacterial efficacy of a new sonic irrigation device for root canal disinfection. *J Endod* 2016; 42: 1799-1803.
- Poggio C, Dagna A, Chiesa M, Scribante A, Beltrami R, Colombo M. Effects of NiTi rotary and reciprocating instruments on debris and smear layer scores: an SEM evaluation. *J Appl Biomater Funct Mater* 2014; 12: 256-262.
- Ruddle CJ. Cleaning and shaping root canal system. Cohen S, Burns RC. *Pathways of the pulp*. 8<sup>th</sup> ed. St. Louis: Mosby; 2002: 231-291.
- Sharma G, Kakkar P, Vats A. A comparative SEM investigation of smear layer remaining on dentinal walls by three rotary NiTi files with different cross sectional designs in moderately curved canals. *J Clin Diagn Res* 2015; 9: 43-47.
- Takeda FH, Harashima T, Kimura Y, Matsumoto K. Efficacy of Er:YAG laser irradiation in removing debris and smear layer on root canal walls. *J Endod* 1998; 24: 548-551.
- Torabinejad M, Handysides R, Khademi AA, Bakland LK. Clinical implications of the smear layer in endodontics: a review. *Oral Surg Oral Med Oral Pathol Oral Radiol Endod* 2002; 94: 658-666
- Violich DR, Chandler NP. The smear layer in endodontics – a review. *Int Endod J* 2010; 43: 2-15.
- Wujec P, Pawlicka H. Skuteczność usuwania wodorotlenku wapnia z kanałów korzeni zębów. *E-Dentico* 2012; 40: 66-77.
- Živković S, Nešković J, Jovanović-Medojević M, Popović-Bajić M, Živković-Sandić M. XP-endo Finisher: a new solution for smear layer removal. *Serbian Dent J/Stom Glas Srb* 2015; 62: 122-129.