

presence of a detectable leak has a low predictive value and does not exclude PES or the need for re-intubation, even though they also pointed to the concern that the absence of a leak should alert the clinician to a higher risk of PES. Again, a recent study by Patel *et al.* [10] demonstrated that the CLT or a combination of the CLT with laryngeal parameters failed to accurately predict PES. Moreover, the probability that the CLT can increase the risk of oropharyngeal and subglottic secretions into the airway during cuff deflation and mechanical ventilation does exist and cannot be denied.

Extubation of intensive care unit (ICU) patients is potentially a high risk procedure. There is no single test that can reliably predict post-extubation stridor. We believe that a combination of tests should be performed (as suggested by Patel *et al.* [10]) in addition to a fiberoptic laryngoscopy prior to extubation so as to exclude any new onset of anatomical defects similar to our case. This, in turn, can somewhat reduce the incidence of post extubation upper airway obstruction.

#### ACKNOWLEDGEMENTS

1. Source of funding: none.
2. Conflict of interest: none.

#### Piśmiennictwo:

1. Miller RL, Cole RP. Association between reduced cuff leak volume and postextubation stridor. *Chest*. 1996; 110(4): 1035–1040, indexed in Pubmed: [8874265](#).

2. Keiser GJ, Bozentka NE, Gold BD. Laryngeal granuloma: a complication of prolonged endotracheal intubation. *Anesth Prog*. 1991; 38(6): 232–234, indexed in Pubmed: [1842162](#).
3. Blanc VF, Tremblay NA. The complications of tracheal intubation: a new classification with a review of the literature. *Anesth Analg*. 1974; 53(2): 202–213, indexed in Pubmed: [4593090](#).
4. Adderley RJ, Mullins GC. When to extubate the croup patient: the „leak” test. *Can J Anaesth*. 1987; 34(3 ( Pt 1)): 304–306, doi: [10.1007/BF03015171](#), indexed in Pubmed: [3581402](#).
5. Zhou T, Zhang HP, Chen WW, et al. Cuff-leak test for predicting postextubation airway complications: a systematic review. *J Evid Based Med*. 2011; 4(4): 242–254, doi: [10.1111/j.1756-5391.2011.01160.x](#), indexed in Pubmed: [23672755](#).
6. Keeratichananont W, Limthong T, Keeratichananont S. Cuff leak volume as a clinical predictor for identifying post-extubation stridor. *J Med Assoc Thai*. 2012; 95(6): 752–755, indexed in Pubmed: [22774617](#).
7. Sandhu RS, Pasquale MD, Miller K, et al. Measurement of endotracheal tube cuff leak to predict postextubation stridor and need for reintubation. *J Am Coll Surg*. 2000; 190(6): 682–687, indexed in Pubmed: [10873003](#).
8. Shin SH, Heath K, Reed S, et al. The cuff leak test is not predictive of successful extubation. *Am Surg*. 2008; 74(12): 1182–1185, indexed in Pubmed: [19097533](#).
9. Ochoa ME, Marin Md, Frutos-Vivar F, et al. Cuff-leak test for the diagnosis of upper airway obstruction in adults: a systematic review and meta-analysis. *Intensive Care Med*. 2009; 35(7): 1171–1179, doi: [10.1007/s00134-009-1501-9](#), indexed in Pubmed: [19399474](#).
10. Patel AB, Ani C, Feeney C. Cuff leak test and laryngeal survey for predicting post-extubation stridor. *Indian J Anaesth*. 2015; 59(2): 96–102, doi: [10.4103/0019-5049.151371](#), indexed in Pubmed: [25788742](#).

#### Adres do korespondencji:

Ankur Khandelwal  
 Department of Neuroanaesthesiology and Critical Care,  
 All India Institute of Medical Sciences (AIIMS)  
 New Delhi, India  
 e-mail: [ankurchintus@gmail.com](mailto:ankurchintus@gmail.com)

Anestezjologia Intensywna Terapia  
 2017, tom 49, numer 1, 82–83  
 ISSN 0209–1712  
[www.ait.viamedica.pl](http://www.ait.viamedica.pl)

## Silicone stents save lives without surgery in postintubation subglottic stenosis

Levent Dalar<sup>1</sup>, Ayten Saracoglu<sup>2</sup>, Kemal T. Saracoglu<sup>3</sup>

<sup>1</sup>Department of Respiratory Diseases, Istanbul Bilim University Medical School, Turkey

<sup>2</sup>Department of Anesthesiology and Intensive Care, Istanbul Marmara University Medical School, Turkey

<sup>3</sup>Department of Anesthesiology and Intensive Care, Istanbul Bilim University Medical School, Turkey

To the Editor,

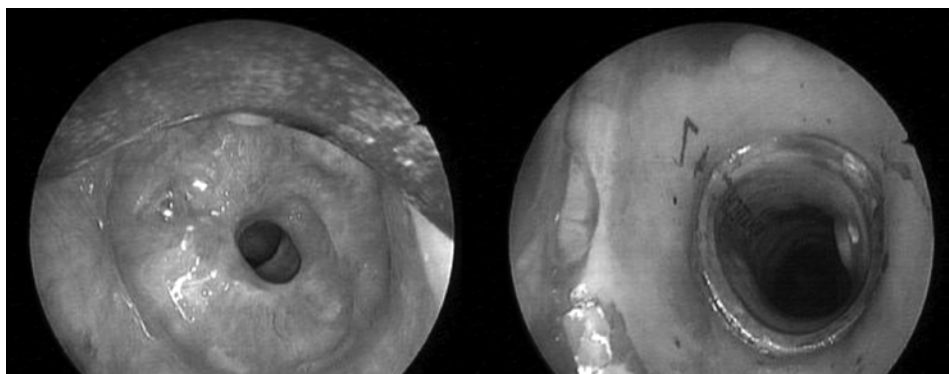
The estimated prevalence of postintubation subglottic tracheal stenosis has been stated as 4.9 cases per million per year [1]. In most cases the ischemic injury occurs at the level of the cuff, in the subglottic region [2]. Life-threatening complications may occur, including stridor, hypercapnia, hypoxia, reintubation and a delay in weaning of intensive care unit patients. Most cases typically present weeks to months after intubation [3].

There are several treatment options for benign tracheal stenosis. Early low-dose systemic corticosteroids have been shown to be effective in postintubation tracheal stenosis man-

agement [4]. Tracheoplasty may be performed with tracheal anastomosis. Patients may require a permanent or transient tracheostomy. Surgery usually includes complex tracheal stenosis, subglottic involvement or associated tracheomalacia. Even following laryngotracheal resection, restenosis may occur. Tracheal dilation and stenting is another alternative modality of treatment for patients who are not surgical candidates.

A 56-year-old male patient with a diagnosis of coronary artery disease, developed an acute myocardial infarction. The patient had chronic obstructive pulmonary disease and diabetes mellitus type 2. He was admitted to the intensive care unit. The patient was intubated due to acute hypoxemic respiratory failure. He required prolonged mechanical ventilation during 21 consecutive days. Following the 10<sup>th</sup> day of his extubation, progressive stridor and dyspnea occurred. A fiberoptic bronchoscopy was performed on the patient with a provisional diagnosis of subglottic stenosis (Fig. 1A). Following mechanical dilation and the use of an argon laser, the placement of a Vergnon silicone stent was performed using rigid bronchoscopy. Subsequently, the proper position of the stent was confirmed by a fiberoptic bronchoscope (Fig. 1B).

**Należy cytować wersję:** Dalar L, Saracoglu A, Saracoglu KT. Silicone stents save lives without surgery in postintubation subglottic stenosis. *Anaesthesiol Intensive Ther*. 2017, vol. 49, no 1, 78–79. doi: 10.5603/AIT.2017.0014.



**Figure 1.** Postintubation subglottic stenosis and confirmation of proper placement for the Vergnon silicone stent

In this report, the bronchoscopy revealed tracheal stenosis. Not only early diagnosis but also early stent placement was possible in this patient with subglottic tracheal stenosis. The early placement of tracheal silicone stents may prevent the need for major surgical interventions.

#### ACKNOWLEDGEMENTS

1. Source of funding: none.
2. Conflict of interest: none.

#### Piśmiennictwo:

1. Zestos MM, Hoppen CN, Belenky WM, et al. Subglottic stenosis after surgery for congenital heart disease: a spectrum of severity. *J Cardiothorac Vasc Anesth.* 2005; 19(3): 367–369, indexed in Pubmed: [16130067](https://pubmed.ncbi.nlm.nih.gov/16130067/).

2. Dalar L, Schuurmans MM, Eryuksel E, et al. Early tracheal stenosis causing extubation failure and prolonged ventilator dependency. *Anaesth Intensive Care.* 2013; 41(1): 108–112, indexed in Pubmed: [23362899](https://pubmed.ncbi.nlm.nih.gov/23362899/).
3. Millard A. Double respiratory sequelae of head injury: subglottic stenosis and bilateral pneumothoraces. *Br J Anaesth.* 2003; 90(1): 94–96, indexed in Pubmed: [12488388](https://pubmed.ncbi.nlm.nih.gov/12488388/).
4. Shadmehr MB, Abbasidezfouli A, Farzanegan R, et al. The Role of Systemic Steroids in Postintubation Tracheal Stenosis: A Randomized Clinical Trial. *Ann Thorac Surg.* 2017; 103(1): 246–253, doi: [10.1016/j.athoracsur.2016.05.063](https://doi.org/10.1016/j.athoracsur.2016.05.063), indexed in Pubmed: [27476818](https://pubmed.ncbi.nlm.nih.gov/27476818/).

#### Adres do korespondencji:

Ayten Saracoglu, MD, DESA  
 Florence Nightingale Hospital  
 Abide-i Hürriyet Cad. No: 164  
 Şişli Çağlayan, İstanbul, Turkey  
 e-mail: [anesthesiayten@gmail.com](mailto:anesthesiayten@gmail.com)

Anestezjologia Intensywna Terapia  
 2017, tom 49, numer 1, 83–85  
 ISSN 0209–1712  
[www.ait.viamedica.pl](http://www.ait.viamedica.pl)

## Anaphylaxis during cardiac surgery for hypertrophic cardiomyopathy: pathophysiological and therapeutic considerations

Nicholas G. Kounis, Grigorios Tsigkas, Ioanna Koniari, George Tzanis, George Soufras, George Hahalis

*Department of Cardiology, University of Patras Medical School, Rion, Patras, Achaia, Greece*

Sir,

In a very interesting report published in *Anaesthesiology Intensive Therapy* [1], a 40-year-old female patient suffering from hypertrophic obstructive cardiomyopathy and being on metoprolol therapy developed anaphylaxis with profound hypotension and cutaneous manifestations while being scheduled for an elective, surgical septal my-

ectomy. Chlorhexidine was used for skin disinfection prior to the insertion of an arterial line. The patient received phenylephrine, midazolam, fentanyl, propofol and rocuronium both before and during the anaesthesia induction. Subsequently, she was treated with epinephrine boluses, hydrocortisone, diphenhydramine and salbutamol via the ventilatory circuit. However, a transesophageal echocardiographic examination showed that the epinephrine boluses had caused obstruction of the left ventricular outflow tract and the patient went clinically into cardiogenic shock. With an urgent cardiopulmonary bypass, protamine directly into the aorta and cefazolin administration, she had an excellent surgical result and favourable clinical improvement. Although a skin prick test was negative for rocuronium, he was confirmed to have an allergy to chlorhexidine.

While this report is interesting, it raises important questions related to the cause of anaphylaxis in anaesthesia, the

**Należy cytować wersję:** Kounis NG, Tsigkas G, Koniari I, Tzanis G, Soufras G, Hahalis G. Anaphylaxis during cardiac surgery for hypertrophic cardiomyopathy: pathophysiological and therapeutic considerations. *Anaesthesiology Intensive Ther.* 2017, vol. 49, no 1, 79–80. doi: [10.5603/AIT.2017.0015](https://doi.org/10.5603/AIT.2017.0015).