

Research paper

Fetal M-mode echocardiography of atria in normal heart anatomy and no functional abnormalities



Maria Respondek-Liberska 

Department of Fetal Malformation's Diagnoses and Prevention, Medical University of Lodz, Poland
Department of Fetal Cardiology, Polish Mother's Memorial Hospital, Lodz, Poland

Abstract

Introduction: M-mode echocardiography at the atrial level is only possible during prenatal life. The aim of the study was to evaluate the M-mode parameters of RA/LA in fetal normal heart anatomy (NHA) and without functional anomalies (NHS).

Material and methods: M-mode echocardiography of RA/LA patterns were analysed in 32 fetuses, with mean gestational age 27.7 ± 3.7 weeks. It was a retrospective cross-sectional analysis. Using 2-D ECHO a four-chamber view was obtained, and M-mode was put perpendicular to atrial walls.

Results: Typical pattern of M-mode echo RA/LA was found in fetuses with NHA and NHS: RA wall contractions were more prominent than LA wall contractions in 66%, they presented with an equal amplitude of contractions in 25%, and with only RA contractions in 9%. The interatrial septum was in the middle of the space between both atrial walls. The septum primum (FO flap) was moving always within the space of the LA presenting a typical trace: during atrial wall contractions it was fast moving towards the RA wall, and during atrial diastole it showed slower biphasic trace in 79% or other trace in 21%.

Conclusions: M-mode echo of RA/LA in fetuses with NHA and NHS showed a typical pattern of atrial wall excursions, FO valve movement in atrial systole and atrial diastole, and position of atrial septum.

Key words: left atrium, fetal well-being, right atrium, septum primum, foramen ovale flap.

Corresponding author:

Prof. Maria Respondek-Liberska
Medical University of Lodz
Polish Mother's Memorial Hospital
Rzgowska 281/289
93-345, Lodz, Poland
e-mail: maria.respondek-liberska@uni.lodz.pl

Introduction

M-mode echocardiography at the ventricles level is an old method that has been used in adult and paediatric cardiology for many years. But M-mode echocardiography at the atrial level is only possible during prenatal life, and the literature on this subject is very limited. We aimed to evaluate patterns to define the M-mode parameters of RA/LA in fetal normal heart anatomy without functional anomalies.

Material and methods

From our unit database for fetal echocardiography from the year 2019, we selected M-mode RA/LA echocardiography images for further analyses. Fetal echocardiographic exams were performed on GE Voluson E8, GE Voluson 10, and Philips (with convex probes, 3D probes, and cardiac probes). All exams were stored digitally and later reviewed off-line using the Tricify4 Internet database. We selected for further evaluation only fetuses

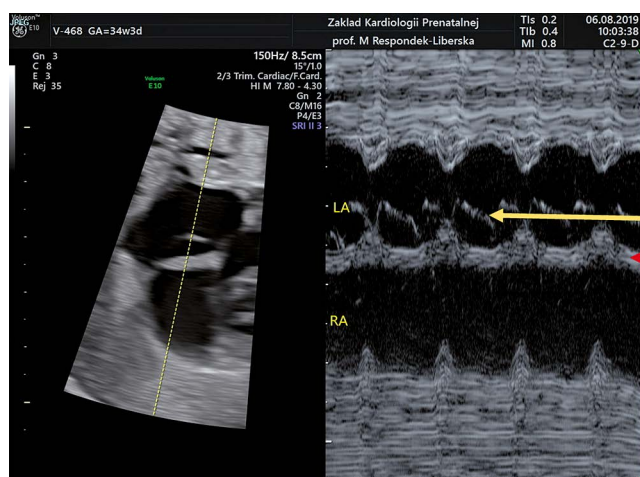


Figure 1. M-mode RA/LA echocardiography images. Yellow arrow – foramen ovale flap within the space of left atrium (LA), red arrow – atrial septum

with normal heart anatomy, no functional abnormalities, no extracardiac malformations, with normal biometry, and from singleton pregnancies, in case of a good quality exam: apex of the heart was on “the clock as on 9th or 3rd hours” and M-mode beam was perpendicular to the atrial septum or almost perpendicular with no more than 15° from the zero line (correction angle beam was not used; anatomical M-mode was not used). For more precise evaluation an option zoom was used (Figure 1). The delivery was at the 37th week of gestation or later, and newborns were discharged from hospital at the latest on day 3 or 4 in good clinical condition without any problems based on the hospital records (data from an Internet fetal echo program, Medical University of Lodz).

All cases had cross-sectional analyses. The M-mode tracings were analysed qualitatively. We analysed the right atrial (RA) wall excursion in comparison to left atrial (LA) wall excursion, the position of the interatrial septum, and tracing of the foramen ovale flap in the atrium, both in atrial diastole and atrial systole. We also paid attention to the trace of the Eustachian valve in the right atrium where possible.

From the population of 127 normal fetal echocardiograms performed by the same person (MRL) a group of the 32 fetuses (25%) was selected and presented in Table 1. Fetal routine echocardiography examination was performed according to the rules of the American Heart Association scientific statement from 2014 [1], and the examination was extended in the case of the good visibility of the fetal heart structure and an optimal fetal heart position.

Results

The mean gestational age was: 27.7 ± 3.7 weeks; min 19 and maximum 34.3.

In fetuses from the study group, RA wall amplitude excursion was greater than LA wall excursion in 66% ($n = 21$), equal excursions were present in 25% ($n = 8$), and only RA excursions were present in 9% ($n = 3$) (Figure 1). There was no single

case of “silent”, i.e. no excursion, of the RA wall. Wall amplitude excursion was from 2 to 4 mm.

In 6/32 fetuses (18%) younger than 29 weeks, the left atrial wall was “silent” with no excursion and after the 30th week of gestation all fetuses (100%) in the study group presented left atrial wall excursions.

The foramen ovale flap in all cases in this study group was freely moving, resided within the LA, and did not cross the boundary line of atrial septum, closing the foramen ovale in systole.

In all cases, at the onset of atrial contractions there was fast (prominent excursion) of the foramen ovale flap towards the RA. In 79% ($n = 25$), during atrial diastole the foramen ovale flap showed slower biphasic movement, and the sequence was repeated in the next beat.

In five cases there was a “triphasic”-like trace in atrial diastole, and in two cases almost a “monophasic” trace was seen. In only one case (at 27 weeks) did the foramen ovale flap show small “oscillation” with flow. In subsequent scans this abnormality did not persist, so it seems to have been only a temporary event.

The interatrial septum in 65% ($n = 21$) fetuses from the study group of normal fetal heart anatomy was in the middle of the space between the right and left atrial walls in a still position, meaning not moving, and in 35% ($n = 11$) there were atrial septal movements parallel to the RA wall contractions (Table 1, Figure 1).

The Eustachian valve in the right atrium was poorly seen in 27/32 of the cases. If visible, it was moving in concert, parallel to the foramen ovale flap (septum primum) (Table 1). It was not possible to make precise evaluation of the Eustachian valve motion in the majority of cases with the current ultrasound technology, so this part of the analyses was not continued.

Discussion

In normal physiology in the right atrium (RA) there is a crossroads for different blood streams: one arises from inferior vena cava and is directed to the left atrium via foramen ovale. Another blood stream is from the SVC and next one is from the coronary sinus. This stream from the inferior vena cava has been shown, in fetal sheep studies [2], to be divided into two streams: one from the inferior vena cava and one from the ductus venosus. The streams remain separate because of different flow velocities. These blood streams may change with fetal activity, including breathing movements and sleep movement.

Could fetal M-mode of the right atrial walls and left atrial walls and tracing of septal flap movement help to better understand the fetal blood circulation at the atrial level and confirm human fetal well-being?

M-mode echocardiography evaluation of the right and left ventricles is an established postnatal and prenatal technique used for some fetal echocardiography prior to the development of 2D ultrasound [3-5]. It is used in

Table 1. Quantitative characteristic of fetal M-mode of RA/LA in normal heart anatomy (NHA) and normal heart study (NHS)

Nr of case	Gestational age (in weeks)	RA & LA wall excursions	LA wall excursions	FO valve in left atrium?	FO valve motion in atrial systole	FO valve motion in atrial diastole	Interatrial septum: in the middle flat or small excursion with RA	Eustachian valve seen or not
1	19.1	RA > LA	+	Yes	BETRA	Biphasic	With RA	+
2	19.2	RA	0	Yes		Biphasic	Flat	-
3	23.1	RA = LA	+	Yes	BETRA	Triphasic	Flat	+/-
4	24.2	RA > LA	0	YES	BETRA	Monophasic	Flat	+
5	24.6	RA = LA	+	Yes	BETRA	Biphasic	Flat	+/-
6	25.2	RA = LA	+	Yes	BETRA	Biphasic	Flat	-
7	25.4	RA > LA	+	Yes	BETRA	Biphasic	Flat	-
8	26.1	RA > LA	0	Yes		Triphasic	Flat	-
9	26.2	RA > LA	+	Yes	BETRA	Biphasic	Flat	-
10	26.4	RA = LA	+	Yes	BETRA	Biphasic	With RA	+/-
11	26.4	RA > LA	0	Yes	BETRA	Biphasic	Flat	+/-
12	26.5	RA > LA	+	Yes	BETRA	Biphasic	With RA	-
13	27.2	RA > LA	+	Yes	BETRA	Triphasic	Flat	+
14	27.4	RA > LA	+	Yes	BETRA	Biphasic	With RA	+
15	27.5	RA > LA	+	Yes	BETRA	Biphasic	With RA	-
16	27.6	RA = LA	+	Yes	BETRA	Biphasic	Flat	
17	27.6	RA > LA		Yes	BETRA	Biphasic	Flat	-
18	28.2	RA = LA	+	Yes	BETRA	Biphasic	With RA	-
19	28.6	RA > LA	+	Yes	BETRA	Biphasic	FLAT	-
20	28.7	RA > LA	0	Yes	BETRA	Biphasic	FLAT	-
21	29.1	RA > LA	+	Yes	BETRA	Biphasic	Flat	-
22	29.2	RA > LA	0	Yes	BETRA	Biphasic	With RA	+
23	29.3	RA > LA	+	Yes	BETRA	Biphasic	With RA	-
24	30.1	RA > LA	+	Yes	BETRA	Biphasic	With RA	-
25	30.4	RA > LA	+	Yes	BETRA	Monophasic	With RA	-
26	31.1	RA > LA	+	Yes	BETRA	Triphasic	With RA	-
27	32.4	RA = LA	+	Yes	BETRA	Biphasic	Flat	-
28	33.1	RA = LA	+	Yes	BETRA	Biphasic	Flat	-
29	33.3	RA > LA	+	Yes	BETRA	Biphasic	With RA	-
30	34.2	RA = LA	+	Yes	BETRA	Biphasic	Flat	+/-
31	34.3	RA > LA	+	Yes	BETRA	Triphasic	Flat	-
32	34.3	RA = LA	+	Yes	BETRA	Biphasic	With RA	-
Summary	27.7 ±3.7 Mean + STD	RA > LA 66% RA = LA 25% RA only 9% LA only 0%	LA contractions 81%	100%	100%	Biphasic 79% Triphasic 15% Monophasic 6%	Interatrial septum flat 65% & with RA wall movement 35%	27/32 not for analysis

BETRA – “big” (fast) excursion of the foramen ovale flap towards the right atrium, RA – right atrium, LA – left atrium

fetal cardiology for qualitative and quantitative assessment of interventricular septal wall motion, posterior wall motion of the left ventricle, and their dimensions, to evaluate fetal heart arrhythmias or hypertrophic cardiomyopathy [6-12].

M-mode fetal echocardiography of RA/LA atria is unique for prenatal cardiology, and in the past it was used far less for scientific analyses. Based on this technique, one can define excursions of left and right atrium walls, as well as patterns of

Table 2. Main features from prenatal M-mode echocardiography of RA/LA in the case of normal heart anatomy and functional abnormality

Fetus well-being
Good contractility of RA and LA walls > 29 th week of gestation (in fetuses < 29 th week right atrial wall excursions may be dominated)
Interatrial septum in the middle
Foramen ovale flap – always in LA: in systole fast movement towards RA, in diastole slow movement, in 60% biphasic

motion of foramen ovale flap (septum primum) and Eustachian valve motion. The latter motion was initially defined in fetal sheep by Schmidt, Silverman, and Rudolph in 1996 [2].

The umbilical venous flow is directed toward the left atrium. Rich oxygenated blood stream appears to be directed by the Eustachian valve (EV), arising from the orifice of the inferior vena cava, which is a thin structure that is often difficult to see during ultrasound exam. The stream that originated from the narrowed ductus venosus had a higher velocity than that from the caudal inferior vena cava (mean velocity, 57 ± 13 vs. 16 ± 3 cm/s; $p < 0.0002$), as described by Schmidt, Silverman, and Rudolph [2]. The EV motion is parallel to that of the foramen ovale flap (septum primum). When the foramen ovale flap (septum primum) moves toward the atrial septum the Eustachian valve moves away from the atrial septum as well. In atrial systole the foramen flap moves back toward the atrial septum, theoretically preventing oxygen-rich blood from coming back and entering the pulmonary side of the circulation.

In healthy human fetuses, based on our observations, in the second half of gestational age, and especially after 29 weeks of gestation, both atria were involved in contractions; however, the RA wall excursion was more prominent compared with the left atrial wall in 66%, there were equal contractions in 25%, and there were no LA contractions in 9% among younger fetuses, i.e. below the 29th week of gestation. There was no single case in this study group of “silent” right atrial wall. This observation confirms the important role of the right atrium wall contractions in younger fetuses and the important role of the right and left atrium in older fetuses (i.e. > 30th week of gestation).

The proper balance between both atria is presented also by the position of the interatrial septum in the middle space between the walls of the two atria.

In normal fetal heart the foramen ovale flap is like a veil or a sail, which moves within the space of the left atrium and does not cross the line of the atrial septum. The movements of the foramen ovale flap (septum primum) in M-mode represent the blood flow stream from the RA to the LA. In atrial systole there was rapid movement of the foramen ovale flap towards the wall of the right atrium, and in atrial diastole there was slower and biphasic pattern flow of foramen ovale valve flap motion (in the majority of cases – 79%), probably representing two blood streams: one from DV and the other one from IVC. In the minority (21%) there was a “monophasic” pattern – probably the

blood stream from IVC and DV had similar velocities during fetal heart examination.

As the blood flow from SVC is proceeding towards tricuspid valve it is not reflected on the tracing of the foramen ovale flap movement.

A similar observation using M-mode of the atria (or M-mode of septum primum) was reported by Dellinger in 1993 [13]; however, he suggested that the biphasic motion of the foramen ovale flap is due to the atrial and ventricular contractions and claimed that biphasic motion was lost in atrial septal aneurysms.

All of our fetuses from the study group were born in good clinical condition, and neonates were discharged from the hospital by 3rd-4th day without any additional information in hospital records, which confirmed their good clinical condition during our investigation.

To sum up, based on M-mode echocardiography of RA and LA one may confirm good fetal haemodynamic condition: atrial wall excursions, the position of the interatrial septum in the middle space between the atrial walls, and the type of excursion of the foramen ovale flap both in atrial systole and in atrial diastole (Table 2).

The type of analysis of M-mode echocardiography or RA/LA presented above was not very easy to obtain. The study group ($n = 32$) was selected from 127 normal fetal echocardiograms, and the quality of the tracings was related to the position of the fetus. Angle correction or anatomical M-mode were not used; hence, M-mode echocardiography analyses of RA/LA is routinely difficult to obtain but in selected cases might be helpful to better understand the intracardiac blood flow at the level of atria of the fetus as patient.

This way we believe further application in future research is promising compared to the earlier published method by Sutton et al. in 1994 [14], who suggested calculation of the logarithm of combined ventricular flow, logarithm flow in the ductus arteriosus, and flow through the lungs, in order to obtain the relationship between the logarithm of flow through the foramen ovale and gestational age.

In this way, we believe a new method for fetal foramen ovale haemodynamic evaluation may be created, instead of using animal models, to study the importance of FO [15].

This was a qualitative assessment without sophisticated statistical analysis, as a preliminary report to draw attention to the future possibility of using the M-mode technique of RA/LA cross-sectional analysis. For future evaluation it would be necessary to analyse the fetus haemodynamically at the atria level in the context of pulmonary vein flow, direction of blood flow at the atrial level, and blood flow velocity at the atrial level.

Conclusions

M-mode echocardiography of the RA/LA in fetuses with normal heart anatomy and no functional abnormalities showed a typical pattern in evaluation, including the following: atrial wall excursions, foramen ovale valve movement in atrial systole and atrial diastole, and the position of the atrial septum.

Acknowledgments

I would like to express my special thanks to Prof. Norman H Silverman from the University of California, San Francisco CA, E.S.A., who devoted his time and efforts to discuss some of the issues with me.

Conflict of interest

The author declares no conflict of interest.

REFERENCES

1. Donofrio MT, Moon-Grady AJ, Hornberger LK, Copel JA, Sklansky MS, Abuhamad A, et al.; American Heart Association Adults With Congenital Heart Disease Joint Committee of the Council on Cardiovascular Disease in the Young and Council on Clinical Cardiology, Council on Cardiovascular Surgery and Anesthesia, and Council on Cardiovascular and Stroke Nursing. Diagnosis and treatment of fetal cardiac disease: a scientific statement from the American Heart Association. *Circulation* 2014; 129: 2183-2242.
2. Schmidt KG, Silverman NH, Rudolph AM. Assessment of flow events at the ductus venosus inferior vena cava junction and at the foramen ovale in fetal sheep by use of multimodal ultrasound. *Circulation* 1996; 93: 826-833.
3. Allan LD, Joseph MC, Boyd EG, Campbell S, Tynan M. M-mode echocardiography in the developing human fetus. *Br Heart J* 1982; 47: 573-583.
4. DeVore GR, Donnerstein RL, Kleinman CS, Platt LD, Hobbins JC. Fetal echocardiography. I. Normal anatomy as determined by real-time-directed M-mode ultrasound. *Am J Obstet Gynecol* 1982; 144: 249-260.
5. DeVore GR, Siassi B, Platt LD. Fetal echocardiography. III. The diagnosis of cardiac arrhythmias using real-time-directed M-mode ultrasound. *Am J Obstet Gynecol* 1983; 146: 792-799.
6. Deterich JA, Pruetz J, Sklansky MS. Color M-mode sonography for evaluation of fetal arrhythmias. *J Ultrasound Med* 2012; 31: 1681-1688.
7. Abinader EG. M-mode echocardiography for diagnosis of atrial flutter. *Am J Cardiol* 1985; 55: 621.
8. Baldi C, Capece G, Di Muro MR, Tajani E, De Cristofaro M, Ianniruberto A. Fetal atrial fibrillation: in utero detection with real-time directed M-mode echocardiography. *J Clin Ultrasound* 1990; 18: 185-187.
9. Wacker-Gussmann A, Strasburger JE, Cuneo BF, Wakai RT. Diagnosis and treatment of fetal arrhythmia. *Am J Perinatol* 2014; 31: 617-628.
10. Baschat AA, Gembruch U, Knöpfle G, Hansmann M. First-trimester fetal heart block: a marker for cardiac anomaly. *Ultrasound Obstet Gynecol* 1999; 14: 311-314.
11. Sepúlveda-Martínez A, García-Otero L, Soveral I, Guirado L, Valenzuela-Alcaraz B, Torres X, et al. Comparison of 2D versus M-mode echocardiography for assessing fetal myocardial wall thickness. *J Matern Fetal Neonatal Med* 2019; 32: 2319-2327.
12. Zielinsky P. Role of prenatal echocardiography in the study of hypertrophic cardiomyopathy in the fetus. *Echocardiography* 1991; 8: 661-668.
13. Dellinger EH. Atrial septal aneurysm. www.thefetus.net/ (1993-07-13-18).
14. Sutton MS, Groves A, MacNeill A, Sharland G, Allan L. Assessment of changes in blood flow through the lungs and foramen ovale in the normal human fetus with gestational age: a prospective Doppler echocardiographic study. *Br Heart J* 1994; 71: 232-237.
15. Lantto J, Erkinaro T, Haapsamo M, Huhta H, Voipio HM, Hohimer AR, et al. Foramen ovale blood flow and cardiac function after main pulmonary artery occlusion in fetal sheep. *Exp Physiol* 2019; 104: 189-198.

Division of work:

Maria Respondek-Liberska (ORCID: 0000-0003-0238-2172): research concept and design, collection and/or assembly of data, data analysis and interpretation, writing the article, critical revision of the article, final approval of article