

# Poly(ADP-ribose) polymerase-1 (PARP1) and p53 labelling index correlates with tumour grade in meningiomas

Tamás Csonka<sup>1</sup>, Balázs Murnyák<sup>1</sup>, Rita Szepesi<sup>2</sup>, Andrea Kurucz<sup>1</sup>, Álmos Klekner<sup>3</sup>, Tibor Hortobágyi<sup>1</sup>

<sup>1</sup>Division of Neuropathology, Institute of Pathology, <sup>2</sup>Department of Neurology, <sup>3</sup>Department of Neurosurgery, Faculty of Medicine, University of Debrecen, Debrecen, Hungary

*Folia Neuropathol* 2014; 52 (2): 111-120

DOI: 10.5114/fn.2014.43782

## Abstract

*Meningiomas are one of the most frequent intracranial tumours, with 13 histological types and three grades according to the 2007 WHO Classification of Tumours of the Central Nervous System. p53, as one of the most potent tumour suppressor proteins, plays a role in nearly 50% of human tumours. Poly(ADP-ribose) polymerase (PARP) is a DNA repair enzyme with high ATP demand. It plays a role in apoptosis by activating an apoptosis inducing factor, and in necrosis by consuming NAD<sup>+</sup> and ATP. Only PARP1 has been investigated in detail in tumours out of the 17 members of the PARP superfamily; however, its role has not been studied in meningiomas yet. The aim of this study was to determine the role of p53 and PARP1 in meningiomas of different grade and to establish whether there is any correlation between the p53 and PARP1 expression. Both PARP1 and p53 have been expressed in all examined meningiomas. PARP1 labelled grade II tumours with a higher intensity as compared to grade I and III neoplasms, respectively. An increased p53 expression was noted in grade III meningiomas. There was no statistical correlation between p53 and PARP1 expression. Our data indicate that both PARP1 and p53 activation is a feature in meningiomas of higher grade, PARP1 overexpression being an early, whereas p53 overexpression, a late event in tumour progression.*

**Key words:** meningioma, poly(ADP-ribose) polymerase (PARP), p53.

## Introduction

Meningiomas are frequent primary brain tumours representing approximately 30% of all primary intracranial tumours. The incidence is increasing with age and has a slight female predominance [32,59]. The aetiology is not entirely understood, but the increased risk after whole brain radiation therapy is well known [38]. There are several subtypes, like meningothelial, fibrous, transitional, psammomatous, angiomatous, microcystic, secretory, lympho-

plasmacyte-rich, sometimes with crystalline inclusions [5], metaplastic, choroid, clear cell, rhabdoid, papillary and other rare or miscellaneous types [34]. According to the ultrastructural findings, some of the intranuclear vacuoles are produced during autophagy [18]. The heterogeneous glycosylation pattern has also been demonstrated in different subtypes of meningiomas, and it indicates the usefulness of lectins in the evaluation of pluripotential differentiation

## Communicating author:

Tibor Hortobágyi, MD, PhD, FRCPath, Division of Neuropathology, Institute of Pathology, University of Debrecen, 98. Nagyerdei krt. Debrecen, H-4032, Hungary, fax: +3652255248, e-mail: hortobagy@med.unideb.hu

of meningioma cells [56]. The current prediction of clinical behaviour is based on the morphological findings, brain invasion, mitosis index and Mib1 immunostaining [1,47,48]. Meningiomas show positive immunoreactivity for epithelial membrane antigen, oestrogen and progesterone receptors [45]; however these immunohistochemical markers do not help with the determination of the grade. CD31 immunostaining is good for revealing the blood vessel number that is higher in atypical meningiomas than WHO grade I tumours [31], but this marker is not used in routine diagnostic work-up. Despite these findings, there is a need for more “malignant” markers for meningiomas that can be used in routine diagnostic work and a group of them could be the DNA repair genes like p53 or poly(ADP-ribose) polymerase (PARP) in the future.

PARP protein superfamily has 17 members. All of them have four domains: catalytic, auto-modification, caspase-cleaved and DNA-binding domain. Some of them have PARP activity, as PARP1 or PARP2 and some of them do not, as PARP3 or PARP6.

PARP1 is a 113 kDa protein, located in the nucleus. The gene of PARP1 is located on the long arm of chromosome 1 (1q42.12). The cDNA was isolated and sequenced first by Kurosaki *et al.* [26]. One of the main functions of PARP1 is its role in the repair of single-stranded DNA breaks (SSB). After detecting the SSB damage by chemical, radiation or metabolic induction, the enzyme is activated and binds to the DNA, undergoes a structural transformation before it produces poly(ADP-ribose) (PAR) chain by a nicotinamide adenine dinucleotide (NAD<sup>+</sup>), consuming the process. PAR is a signal for other repair genes during base excision repair (BER) [9,29,35]. Activated PARP1 can poly(ADP-ribosyl)ate (PARylate) nuclear enzymes thereby increasing the negative charge and preventing the interaction with other anionic molecules including the DNA. Among the DNA repair functions, activated PARP1 has a vital role in apoptosis by translocation of the apoptosis inducing factor (AIF) from the mitochondria to the nucleus [60,61]. However, if there is a high level of DNA damage, necrotic cell death is triggered by activating a large number of PARP1, consuming NAD<sup>+</sup> and the ensuing ATP depletion [3]. The role of PARP1 activation cascade has also been demonstrated in neuronal stem cell transplantation after brain injury in rats [27], as well as PARP1 is also activated in the ischemia-reperfusion injury [55], and the early activation of PARP1

after cold lesion that is – at least in part – related to neuronal NO synthetase (nNOS) induction [16]. The role of PARP1 has been revealed in the regulation of glycogen synthase kinase-3 (GSK3) that is responsible for the hyperphosphorylation of tau [54], and the amyloid peptide affected signal transduction to PARP1 in Alzheimer’s disease [2].

It has been demonstrated that PARP1 has a role in the BRCA1/BRCA2 mutated breast carcinomas because PARP1 inhibitors can trigger the effectiveness of the chemotherapeutic agents by inhibiting the SSB-repair, when the double-stranded DNA repair is also diminished by the BRCA mutation [11]. The role of PARP1 has been described in other tumours such as breast [51], ovarian [6], pancreatic carcinomas [24], gastric carcinomas [62], prostate carcinomas [53], melanomas [13,40] and glioblastomas [12,21] but has not been investigated in meningiomas yet.

p53 is one of the most significant tumour suppressor proteins, encoded by the *TP53* gene on the short arm of chromosome 17 (17p13.1) [17,33]. The physiological functions of p53 are cell cycle regulation and conservation of the stability of the genome by preventing mutations. The 393 amino acid long, 43.7 kDa weight protein has 7 domains, such as two activation domains (AD1 and AD2), a proline-rich domain, a DNA-binding core domain (DBD), a signalling domain, a homo-oligomerisation domain (OD) and a C-terminal downregulation domain. p53 can be activated by DNA damage, oxidative stress, osmotic shock, ribonucleotide depletion or oncogene expression. The activation is marked by an increase in the half-life of p53 and a change of its conformation [22]. Mdm2 is responsible for the low level of p53 in an unstressed cell, by binding to p53 and preventing its action, and it also transports p53 to the cytosol, and attaches ubiquitin to it covalently.

The anticancer activity of p53 works through several mechanisms: it activates DNA repair proteins, induces growth arrest at the G1/S regulation point through p21 [10] or initiates apoptosis if the DNA damage is irreversible. Mutagens can damage *TP53* causing unregulated cell proliferation; more than 50 percent of human tumours contain a deletion or mutation of the *TP53* gene [15]. p53 was voted the molecule of the year in 1993 by the *Science* magazine [25], due to its key roles.

The role of p53 has already been examined in the meningiomas: some of the examinations ended with negative or equivocal findings [43,48-50], but some

of them showed a significant correlation between the p53 status and the grade or recurrence of the tumour [4,7,8,19,20,28,37,41,44,46,57]. It is also described that p53 immunopositive cells are more frequent in the perinecrotic areas of post-embolised cases than in preserved parts of the tumour [39].

Several theses have been written about the interaction between the PARP1 and the p53. Wieler *et al.* showed that the inhibition of endogenous PARP1 functions suppresses the transactivation function of p53 in response to ionizing radiation; hence PARP1 is a key regulator of the p53 response to DNA damage [58]. Malanga *et al.* showed that ADP-ribose polymers play a role in regulating the DNA binding properties of p53 by preventing and reversing p53 binding to the palindromic p53 consensus sequence [36]. Lee *et al.* has recently discovered a novel role for PARylation of p53 in the gene-specific regulation of the transcriptional mode of p53 on the promoter of MTA1 [30]. Godoy *et al.* revealed overexpression of PARP1 and p53 in high-grade and advanced stage tumours in epithelial ovarian cancer, and it indicated that these 2 markers might serve as a marker of aggressive disease behaviour [14]. Sabisz *et al.* showed the crucial part of PARP1 activity in the maintenance of the G2 arrest induced by DNA damaging drugs; thus, inhibitors of PARP1 may be used as non-genotoxic agents to activate p53 in cancer cells with non-functional p53 pathways [52]. PARylation of transcription factors such as p53, NFkB, and Sp1 prevents their binding to DNA and formation of transcription complexes [42].

The aim of this study is to find any correlation between the PARP1 and p53 immunostaining and the WHO grade of the tumours, and between the PARP1 and p53 immunopositivity.

## Material and methods

The histological slides of 31 meningioma patients have been studied. Patients have been divided into three groups according to the WHO Classification of Tumours of the Central Nervous System [34]. After the surgical removal, sections were created and stained for haematoxylin-eosin (H&E) from formalin-fixed and paraffin-embedded (FFPE) blocks for a routine diagnostic procedure in the Institute of Pathology. All of the cases have been revised by a consultant neuropathologist (TH).

Immunohistochemistry (IHC) has been performed according to standardized methods as described in detail, in earlier publications [16,17]. In brief, 4 µm thick sections from FFPE blocks have been stained for PARP1 rabbit polyclonal antibody (ab6079) (Abcam Plc., Cambridge, England) and p53 DO-7 mouse monoclonal antibody (M7001) (DAKO, Denmark) according to the manufacturer's protocol. Using a 1 : 500 and 1 : 700 dilution for PARP1 and p53, respectively, with Novocastra Bond™ Polymer Refine Detection kit on Leica Bond Max™ fully automated IHC stainer, with negative controls (Fig. 1).

100 cells in 10 fields of vision on 40x magnification have been examined; the staining intensity has been evaluated as none (0), weak (1+), moderate (2+) and strong (3+) from all of the slides for both PARP1 and p53 (Fig. 2). We have created two parameters in all cases regarding to the staining intensity (Si) ratio of the 1+, 2+ and 3+ cells Si1-3, and ratio of the 2+ and 3+ cells Si2-3, similarly as HER2 immunohistochemistry evaluation in breast carcinomas (Table I).

The results have been analysed by SPSS 19.0 for Windows statistical software. After comparing with Kruskal-Wallis H test the Si1-3 and Si2-3, performing Mann-Whitney *U* test on all of the grade pairs for both PARP1 and p53. Next, we have created two groups – low grade (WHO grade I) and high grade (WHO grade II and WHO grade III) [23] and have compared them by Mann-Whitney *U* test. We also have performed Spearman's rank order correlation analysis to determine whether there is any correlation between the PARP1 and p53 immunopositivity.

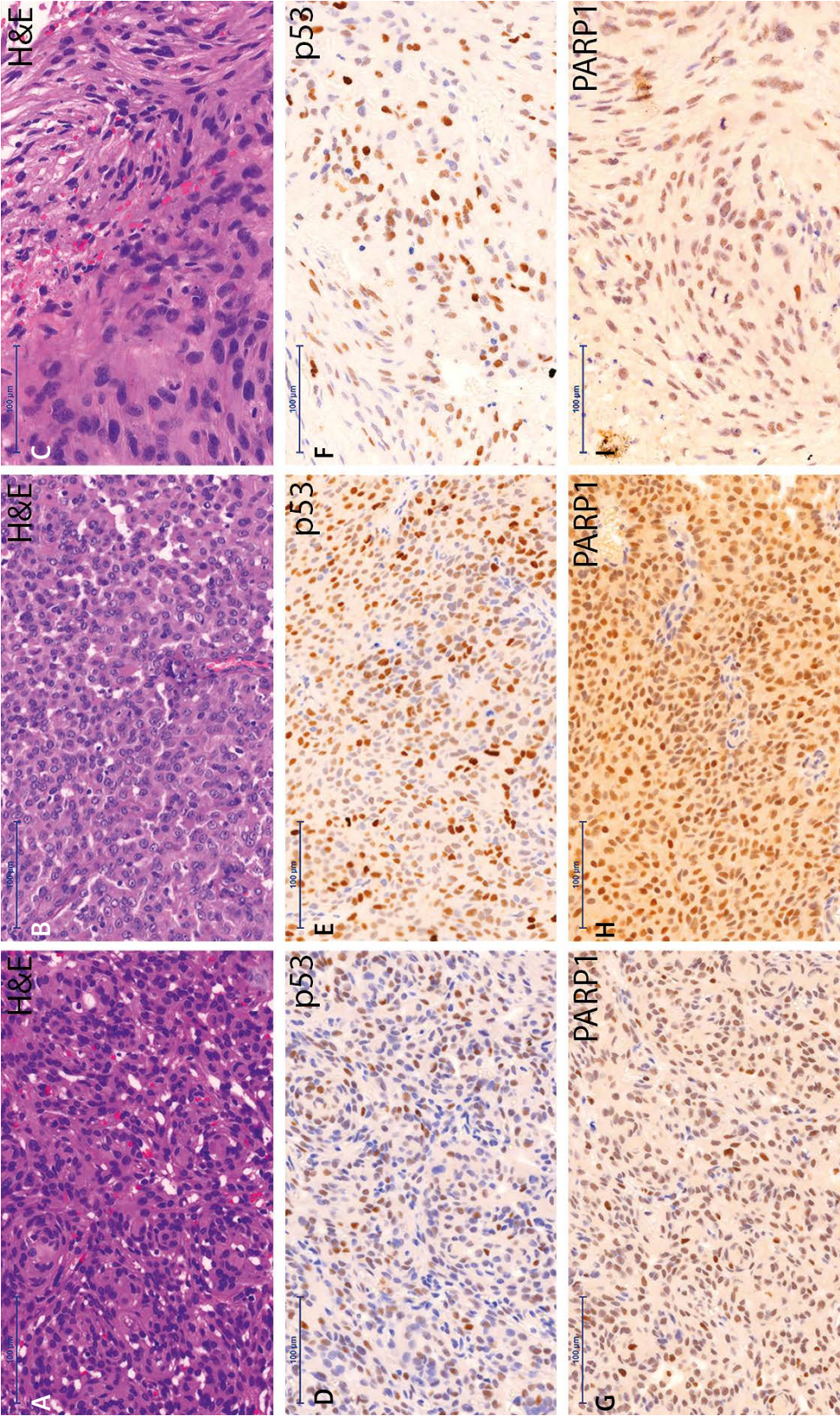
Ethical approval has been sought from the Institutional Research Ethics Committee.

## Results

Both PARP1 and p53 have been expressed in all of the 41 cases.

There was a significant correlation between tumour grade and presence of PARP1 expression (staining intensity (Si)1-3) ( $p = 0.001$ ) and presence of explicit positivity (Si2-3) for p53 ( $p = 0.012$ ), respectively, with Kruskal-Wallis H test. In contrast, there was no statistically significant association between grade and Si2-3 for PARP1, Si1-3 for p53,  $p = 0.523$  and  $p = 0.141$ , respectively.

As next, we have compared different grades and performed Mann-Whitney *U* test. The Si1-3 for PARP1 between grade I and grade II, as well as grade II and



**Fig. 1.** p53 and PARP1 immunostaining in meningiomas of different WHO grades. Haematoxylin-eosin (A, B, C) and immunohistochemical staining for p53 (D, E, F) and PARP1 (G, H, I) of grade I (A, D, G), grade II (B, E, H) and grade III (C, F, I) tumours. (PARP1 – poly(ADP-ribose) polymerase 1) (scale bar 100 µm).

grade III (Fig. 3A); and the Si2-3 for p53 between grade I and grade III (Fig. 3B) significantly correlated with the WHO grades ( $p = 0.001$  and  $p = 0.005$ ,  $p = 0.002$ , respectively). Grade II tumours showed the highest mean index of the PARP1 staining (Fig. 3A), while grade III tumours had the highest staining index for p53 (Fig. 3B).

The Mann-Whitney  $U$  test, performed on the low-grade and high-grade groups, showed a significant correlation between Si1-3 for PARP1 (Fig. 3C) and Si2-3 for p53 (Fig. 3D),  $p = 0.028$  and  $p = 0.018$ , respectively.

Among grade I tumours there were 11 meningothelial, 8 transitional, 1 secretory, 1 fibrous and 1 microcystic; among grade II tumours – 8 atypical and 3 clear cell; all the grade III tumours were anaplastic (i.e. not papillary and rhabdoid). There was no significant difference between the staining intensity of PARP and p53 between subtypes of any grades; however, the case numbers were rather low to make statistically valid comparisons.

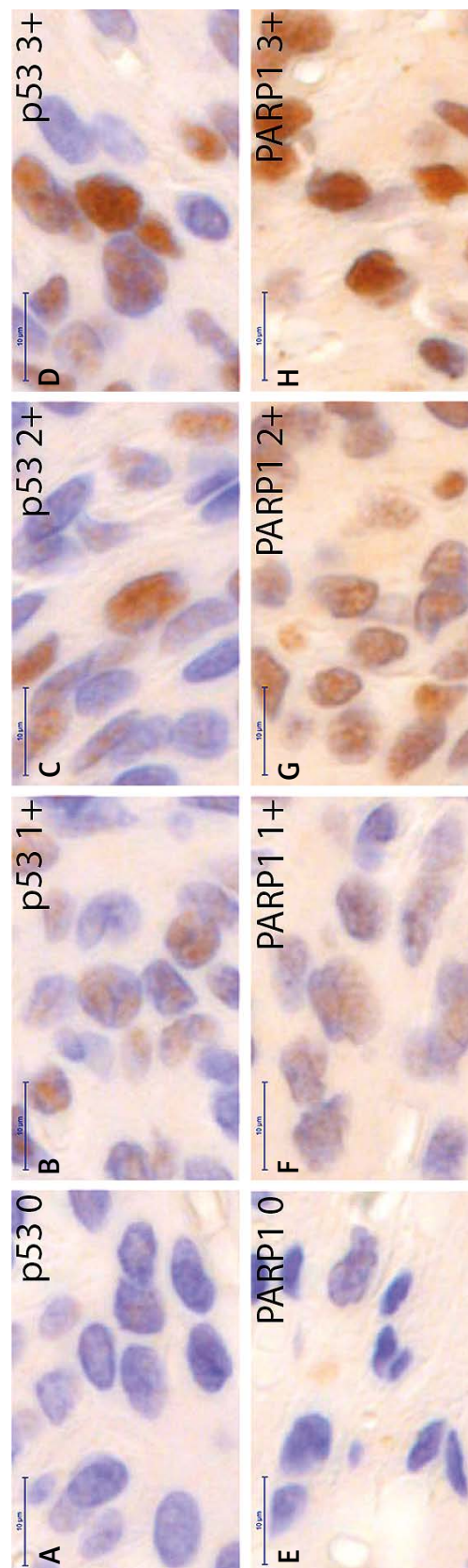
There was no significant correlation between PARP1 and p53 with Spearman's rank order correlation analysis (Fig. 4).

## Discussion

Meningiomas are one of the most frequent intracranial tumours with diverse morphological variants. The current WHO classification [34] distinguishes 13 histological types. Nine of them belong to grade I; 2 and 2 belong to grade II and grade III, respectively. There are morphological criteria that define atypical (WHO grade II) and anaplastic (WHO grade III) meningiomas; however, the distinction is often difficult. Until now there has been no highly trusted immunohistochemical marker that can separate the different WHO grades reliably.

PARP1 protein role has been demonstrated in the repair of the damaged DNA, however this protein also has an important role in the caspase independent apoptotic pathway and in necrotic cell death. p53 is one of the most important tumour suppressor proteins, it has a role in almost half of the human tumours. Several studies have been performed about the p53 marker, but those ended with equivocal results. PARP1 protein expression in meningiomas has not been examined yet.

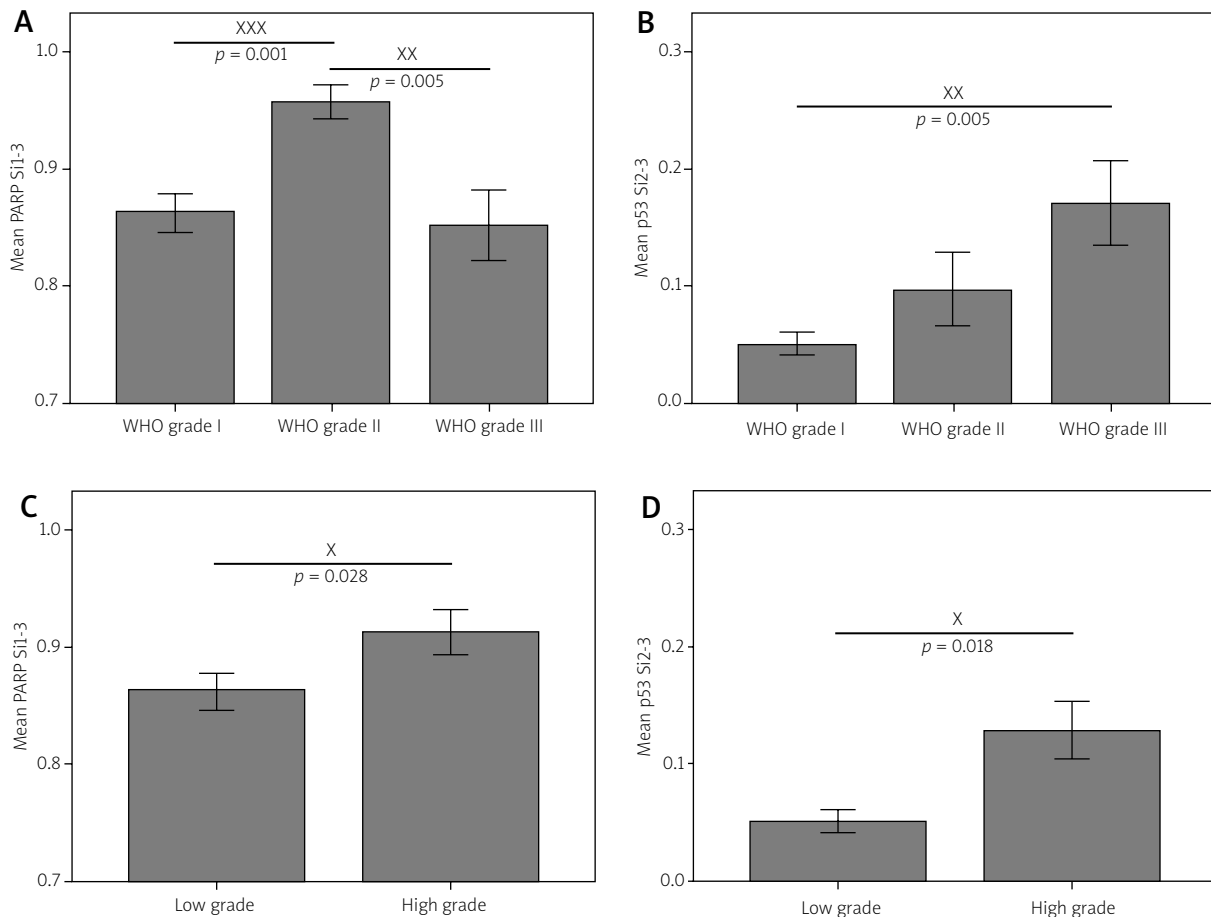
In this study, all of the 41 cases showed immunopositivity for both PARP1 and p53. The proportion



**Fig. 2.** Representative images of the different staining intensities. Immunostaining is performed for p53 (A, B, C, D) and PARP1 (E, F, G, H). There are negative (A, E), weak – 1+ (B, F), moderate – 2+ (C, G) and strong – 3+ (D, H) positive cells. (PARP1 – poly(ADP-ribose) polymerase 1) (scale bar 10 µm).

**Table I.** Data sheet on cell counts showing staining intensities and their respective proportion to all counted cells. Staining index (Si)1-3 is the ratio of the immunopositive (1+, 2+, 3+) cells; and the Si2-3 is the ratio of the intense positive (2+, 3+) cells. (PARP1 – poly(ADP-ribose) polymerase 1)

Patient No.	Slide No.	WHO Grade	Subtype	PARP1						p53					
				0	1+	2+	3+	Si1-3	Si2-3	0	1+	2+	3+	Si1-3	Si2-3
1	1	I	Meningothelial	5	85	9	1	0.95	0.1	49	34	14	3	0.51	0.17
2	2	I	Meningothelial	16	39	37	8	0.84	0.45	49	43	8	0	0.51	0.08
3	3	I	Meningothelial	22	74	4	0	0.78	0.04	70	27	3	0	0.3	0.03
4	4	I	Transitional	10	65	25	0	0.9	0.25	46	50	4	0	0.54	0.04
5	5	I	Meningothelial	26	50	13	11	0.74	0.24	57	39	4	0	0.43	0.04
6	6	I	Meningothelial	8	83	9	0	0.92	0.09	76	24	0	0	0.24	0
7	7	I	Transitional	32	66	2	0	0.68	0.02	75	24	1	0	0.25	0.01
8	8	I	Meningothelial	15	83	2	0	0.85	0.02	52	34	14	0	0.48	0.14
9	9	I	Secretory	22	75	3	0	0.78	0.03	75	17	7	1	0.25	0.08
10	10	I	Meningothelial	23	37	38	2	0.77	0.4	71	23	6	0	0.29	0.06
11	11	I	Fibrous	21	30	24	25	0.79	0.49	47	50	3	0	0.53	0.03
12	12	I	Transitional	15	66	19	0	0.85	0.19	53	38	9	0	0.47	0.09
13	13	I	Meningothelial	7	93	0	0	0.93	0	86	12	2	0	0.14	0.02
14	14	I	Meningothelial	11	68	20	1	0.89	0.21	76	23	1	0	0.24	0.01
15	15	I	Microcystic	5	36	59	0	0.95	0.59	83	17	0	0	0.17	0
16	16	I	Transitional	10	85	4	1	0.9	0.05	52	43	5	0	0.48	0.05
17	17	I	Transitional	6	89	5	0	0.94	0.05	73	21	6	0	0.27	0.06
18	18	I	Transitional	16	33	48	3	0.84	0.51	79	18	3	0	0.21	0.03
19	19	II	Atypical	10	77	11	2	0.9	0.13	60	30	10	0	0.4	0.1
20	20	II	Atypical	8	64	26	2	0.92	0.28	76	24	0	0	0.24	0
21	21	II	Atypical	1	67	32	0	0.99	0.32	85	13	2	0	0.15	0.02
22	22	II	Clear cell	2	80	18	0	0.98	0.18	68	29	3	0	0.32	0.03
23	23	II	Atypical	14	71	10	5	0.86	0.15	78	18	4	0	0.22	0.04
23	24	I	Transitional	9	72	16	3	0.91	0.19	69	31	0	0	0.31	0
24	25	II	Atypical	6	71	21	2	0.94	0.23	80	18	2	0	0.2	0.02
25	26	II	Atypical	1	84	15	0	0.99	0.15	72	23	5	0	0.28	0.05
25	27	II	Clear cell	1	44	53	2	0.99	0.55	44	39	15	2	0.56	0.17
25	28	II	Clear cell	0	27	49	24	1	0.73	38	32	27	3	0.62	0.3
25	29	I	Meningothelial	10	81	9	0	0.9	0.09	67	29	4	0	0.33	0.04
25	30	I	Meningothelial	4	77	16	3	0.96	0.19	71	21	6	2	0.29	0.08
25	31	I	Transitional	9	82	9	0	0.91	0.09	67	27	6	0	0.33	0.06
26	32	II	Atypical	0	33	63	4	1	0.67	35	39	26	0	0.65	0.26
27	35	III	Anaplastic	10	81	9	0	0.9	0.09	59	29	10	2	0.41	0.12
27	34	III	Anaplastic	8	42	40	10	0.92	0.5	30	47	22	1	0.7	0.23
27	33	II	Atypical	4	83	10	3	0.96	0.13	71	21	7	1	0.29	0.08
28	36	III	Anaplastic	10	74	15	1	0.9	0.16	42	28	17	13	0.58	0.3
28	37	III	Anaplastic	20	66	14	0	0.8	0.14	49	20	17	14	0.51	0.31
28	38	III	Anaplastic	4	47	48	1	0.96	0.49	79	19	2	0	0.21	0.02
29	39	III	Anaplastic	14	71	14	1	0.86	0.15	68	22	7	3	0.32	0.1
30	40	III	Anaplastic	25	73	2	0	0.75	0.02	54	26	13	7	0.46	0.2
31	41	III	Anaplastic	28	62	10	0	0.72	0.1	76	15	9	0	0.24	0.09



**Fig. 3.** p53 and PARP staining intensity varies according to the tumour grade. Mean values of the staining index (Si)1-3 for PARP1 (**A, C**) and Si2-3 for p53 (**B, D**) regarding to the WHO grades (**A, B**), and low grade – WHO grade I and high grade – WHO grade II and WHO grade III (**C, D**). Error bars  $\pm$  standard error of mean (SEM).  $p$  values are calculated by Mann-Whitney  $U$  test. (PARP1 – poly(ADP-ribose) polymerase 1; staining index (Si)1-3 is the ratio of the immunopositive (1+, 2+, 3+) cells; and the Si2-3 is the ratio of the intense positive (2+, 3+) cells).

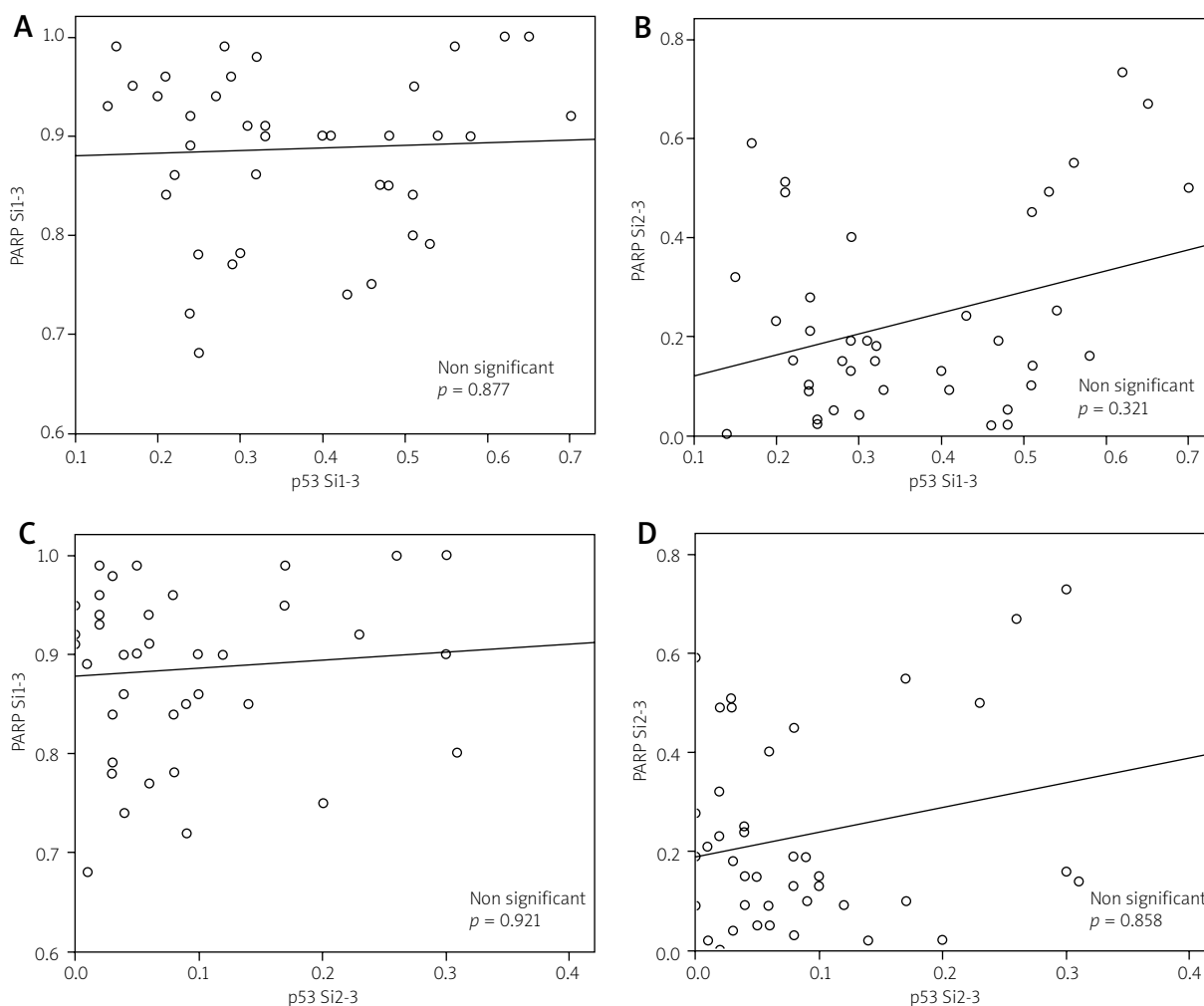
of positive cells (Si1-3) was higher in grade II tumours for PARP1, as compared to grade I and grade III meningiomas, respectively. Increased immunopositivity (Si2-3) was noted in grade III tumours for p53. Comparing the immunopositive cells in the low-grade meningiomas (grade I) and in the high-grade meningiomas (grade II and grade III) we found more immunopositive cells (Si1-3) for PARP1 and a higher staining intensity (Si2-3) for p53 in the high-grade tumours.

Performing a Spearman's rank order correlation and linear regression, there was no statistical correlation between either the presence of positivity or the intense immunoreactions for p53 and PARP1,

thus the expression of these two proteins does not appear to be related to each other. We suggest that PARP1 activation increases in grade II tumours to cope with the DNA damage, whereas in grade III tumours PARP1 activity is decreased as a consequence of apoptotic-necrotic cell death and preceding overactivation and consecutive consumption of the protein and substrates.

Our data confirm that p53 protein plays a role in meningiomas, and indicate that the p53 activation might be a late event in the progression of meningeothelial neoplasms.

Although further studies are necessary to elucidate the role of PARP1 and p53 in meningiomas,



**Fig. 4.** Correlation between p53 and PARP1 staining intensity. There is a dot plot and linear correlation of the results of staining indices. The *p* values are evaluated by Spearman’s rank order correlation test. There are no significant correlations between the staining indices. (PARP1 – Poly(ADP-ribose) polymerase 1, staining index (Si)1-3 is the ratio of the immunopositive (1+, 2+, 3+) cells; and the Si2-3 is the ratio of the intense positive (2+, 3+) cells).

our data indicate that PARP1 and p53 immunohistochemistry represents useful and simple methods aiding the accurate diagnosis and grading of meningiomas.

### Acknowledgements

The authors are thankful to Mrs Livia Beke for technical assistance.

This study was supported by the Hungarian Brain Research Program – Grants No. KTIA\_13\_NAP-A-11/7 and V-3 (to T.H. and A.K.).

### Disclosure

Authors report no conflict of interest.

### References

1. Abramovich CM, Prayson RA. Histopathologic features and MIB-1 labeling indices in recurrent and nonrecurrent meningiomas. *Arch Pathol Lab Med* 1999; 123: 793-800.
2. Adamczyk A, Jesko H, Strosznajder RP. Alzheimer’s disease related peptides affected cholinergic receptor mediated poly(ADP-ribose) polymerase activity in the hippocampus. *Folia Neuropathol* 2005; 43: 139-142.



3. Affar el B, Shah RG, Dallaire AK, Castonguay V, Shah GM. Role of poly(ADP-ribose) polymerase in rapid intracellular acidification induced by alkylating DNA damage. *Proc Natl Acad Sci U S A* 2002; 99: 245-250.
4. Amatya VJ, Takeshima Y, Sugiyama K, Kurisu K, Nishisaka T, Fukuhara T, Inai K. Immunohistochemical study of Ki-67 (MIB-1), p53 protein, p21WAF1, and p27KIP1 expression in benign, atypical, and anaplastic meningiomas. *Hum Pathol* 2001; 32: 970-975.
5. Bodi I, Hortobagyi T, Buk S. A 72-year-old woman with right frontal extra-axial mass. *Brain Pathol* 2008; 18: 279-282.
6. Brustmann H. Poly(adenosine diphosphate-ribose) polymerase expression in serous ovarian carcinoma: correlation with p53, MIB-1, and outcome. *Int J Gynecol Pathol* 2007; 26: 147-153.
7. Cho H, Ha SY, Park SH, Park K, Chae YS. Role of p53 gene mutation in tumor aggressiveness of intracranial meningiomas. *J Korean Med Sci* 1999; 14: 199-205.
8. Chozick BS, Benzil DL, Stopa EG, Pezzullo JC, Knuckey NW, Epstein MH, Finkelstein SD, Finch PW. Immunohistochemical evaluation of erbB-2 and p53 protein expression in benign and atypical human meningiomas. *J Neurooncol* 1996; 27: 117-126.
9. De Vos M, Schreiber V, Dantzer F. The diverse roles and clinical relevance of PARPs in DNA damage repair: Current state of the art. *Biochem Pharmacol* 2012; 84: 137-146.
10. el-Deiry WS, Tokino T, Velculescu VE, Levy DB, Parsons R, Trent JM, Lin D, Mercer WE, Kinzler KW, Vogelstein B. WAF1, a potential mediator of p53 tumor suppression. *Cell* 1993; 75: 817-825.
11. Farmer H, McCabe N, Lord CJ, Tutt AN, Johnson DA, Richardson TB, Santarosa M, Dillon KJ, Hickson I, Knights C, Martin NM, Jackson SP, Smith GC, Ashworth A. Targeting the DNA repair defect in BRCA mutant cells as a therapeutic strategy. *Nature* 2005; 434: 917-921.
12. Galia A, Calogero AE, Condorelli R, Frassetta F, La Corte A, Ridolfo F, Bosco P, Castiglione R, Salemi M. PARP-1 protein expression in glioblastoma multiforme. *Eur J Histochem* 2012; 56: e9.
13. Gehl Z, Bai P, Bodnár E, Emri G, Remenyik É, Németh J, Gergely P, Virág L, Szabó É. Poly(ADP-ribose) in the skin and in melanomas. *Histol Histopathol* 2012; 27: 651-659.
14. Godoy H, Mhawech-Fauceglia P, Beck A, Miller A, Lele S, Odunsi K. Expression of poly (adenosine diphosphate-ribose) polymerase and p53 in epithelial ovarian cancer and their role in prognosis and disease outcome. *Int J Gynecol Pathol* 2011; 30: 139-144.
15. Hollstein M, Sidransky D, Vogelstein B, Harris CC. p53 mutations in human cancers. *Science* 1991; 253: 49-53.
16. Hortobagyi T, Görlach C, Benyó Z, Lacza Z, Hortobágyi S, Wahl M, Harkany T. Inhibition of neuronal nitric oxide synthase-mediated activation of poly(ADP-ribose) polymerase in traumatic brain injury: neuroprotection by 3-aminobenzamide. *Neuroscience* 2003; 121: 983-990.
17. Hortobagyi T, Troakes C, Nishimura AL, Vance C, van Swieten JC, Seelaar H, King A, Al-Sarraj S, Rogelj B, Shaw CE. Optineurin inclusions occur in a minority of TDP-43 positive ALS and FTLD-TDP cases and are rarely observed in other neurodegenerative disorders. *Acta Neuropathol* 2011; 121: 519-527.
18. Jaskolski D, Papier T, Liberski PP, Sikorska B. Ultrastructure of meningiomas: autophagy is involved in the pathogenesis of "intranuclear vacuoles". *Folia Neuropathol* 2012; 50: 187-193.
19. Kamei Y, Watanabe M, Nakayama T, Kanamaru K, Waga S, Shiraishi T. Prognostic significance of p53 and p21WAF1/CIP1 immunoreactivity and tumor micronecrosis for recurrence of meningiomas. *J Neurooncol* 2000; 46: 205-213.
20. Karamitopoulou E, Perentes E, Tolnay M, Probst A. Prognostic significance of MIB-1, p53, and bcl-2 immunoreactivity in meningiomas. *Hum Pathol* 1998; 29: 140-145.
21. Kase M, Vardja M, Lipping A, Asser T, Jaal J. Impact of PARP-1 and DNA-PK expression on survival in patients with glioblastoma multiforme. *Radiother Oncol* 2011; 101: 127-131.
22. Kastan MB, Kuerbitz SJ. Control of G1 arrest after DNA damage. *Environ Health Perspect* 1993; 101 Suppl 5: 55-58.
23. Kato Y, Nishihara H, Mohri H, Kanno H, Kobayashi H, Kimura T, Tanino M, Terasaka S, Tanaka S. Clinicopathological evaluation of cyclooxygenase-2 expression in meningioma: immunohistochemical analysis of 76 cases of low and high-grade meningioma. *Brain Tumor Pathol* 2014; 31: 23-30.
24. Klauschen F, von Winterfeld M, Stenzinger A, Sinn BV, Budczies J, Kamphues C, Bahra M, Wittschieber D, Weichert W, Strieler J, Riess H, Dietel M, Denkert C. High nuclear poly-(ADP-ribose)-polymerase expression is prognostic of improved survival in pancreatic cancer. *Histopathology* 2012; 61: 409-416.
25. Koshland DE Jr. Molecule of the year. *Science* 1993; 262: 1953.
26. Kurosaki T, Ushiro H, Mitsuuchi Y, Suzuki S, Matsuda M, Matsuda Y, Katunuma N, Kangawa K, Matsuo H, Hirose T, Inayama S, Shizuta Y. Primary structure of human poly(ADP-ribose) synthetase as deduced from cDNA sequence. *J Biol Chem* 1987; 262: 15990-15997.
27. Lacza Z, Horváth EM, Komjáti K, Hortobágyi T, Szabó C, Busija DW. PARP inhibition improves the effectiveness of neural stem cell transplantation in experimental brain trauma. *Int J Mol Med* 2003; 12: 153-159.
28. Lanzafame S, Torrisi A, Barbagallo G, Emmanuele C, Alberio N, Albanese V. Correlation between histological grade, MIB-1, p53, and recurrence in 69 completely resected primary intracranial meningiomas with a 6 year mean follow-up. *Pathol Res Pract* 2000; 196: 483-488.
29. Le Page F, Schreiber V, Dherin C, De Murcia G, Boiteux S. Poly(ADP-ribose) polymerase-1 (PARP-1) is required in murine cell lines for base excision repair of oxidative DNA damage in the absence of DNA polymerase beta. *J Biol Chem* 2003; 278: 18471-18477.
30. Lee MH, Na H, Kim EJ, Lee HW, Lee MO. Poly(ADP-ribosylation) of p53 induces gene-specific transcriptional repression of MTA1. *Oncogene* 2012; 31: 5099-5107.
31. Lewy-Trenda I, Omulecka A, Janczukowicz J, Papier W. The morphological analysis of vasculature and angiogenic potential in meningiomas: immunoexpression of CD31 and VEGF antibodies. *Folia Neuropathol* 2003; 41: 149-153.
32. Longstreth WT Jr, Dennis LK, McGuire VM, Drangsholt MT, Koepsell TD. Epidemiology of intracranial meningioma. *Cancer* 1993; 72: 639-648.
33. Louis DN, Ohgaki H, Wiestler OD, Cavenee WK (eds.). WHO Classification of Tumours of the Central Nervous System. IARC, Lyon 2007.
34. Louis DN, Ohgaki H, Wiestler OD, Cavenee WK, Burger PC, Jouvet A, Scheithauer BW, Kleihues P. The 2007 WHO classifi-

- cation of tumours of the central nervous system. *Acta Neuropathol* 2007; 114: 97-109.
35. Makogon NV, Aleksieieva IM. Poly(ADP-ribose) polymerase (PARP): physiological and pathological roles. *Fiziol Zh* 2012; 58: 95-112.
  36. Malanga M, Pleschke JM, Kleczkowska HE, Althaus FR. Poly(ADP-ribose) binds to specific domains of p53 and alters its DNA binding functions. *J Biol Chem* 1998; 273: 11839-11843.
  37. Matsuno A, Nagashima T, Matsuura R, Tanaka H, Hirakawa M, Murakami M, Tamura A, Kirino T. Correlation between MIB-1 staining index and the immunoreactivity of p53 protein in recurrent and non-recurrent meningiomas. *Am J Clin Pathol* 1996; 106: 776-781.
  38. Matyja E, Kroh H, Bojarski P. Intracranial meningiomas following irradiation therapy for brain tumors. *Folia Neuropathol* 1994; 32: 253-254.
  39. Matyja E, Taraszewska A, Marszalek P. Necrosis and apoptosis of tumor cells in embolized meningiomas: histopathology and p53, BCL-2, CD-68 immunohistochemistry. *Folia Neuropathol* 1999; 37: 93-98.
  40. Molloy-Simard V, St-Laurent JF, Vigneault F, Gaudreault M, Dargis N, Guérin MC, Leclerc S, Morcos M, Black D, Molgat Y, Bergeron D, de Launoit Y, Boudreau F, Desnoyers S, Guérin S. Altered expression of the poly(ADP-ribosyl)ation enzymes in uveal melanoma and regulation of PARG gene expression by the transcription factor ERM. *Invest Ophthalmol Vis Sci* 2012; 53: 6219-6231.
  41. Nagashima G, Aoyagi M, Yamamoto M, Yamamoto S, Wakimoto H, Ohno K, Yamamoto K, Hirakawa K. P53 overexpression and proliferative potential in malignant meningiomas. *Acta Neurochir (Wien)* 1999; 141: 53-61.
  42. Oei SL, Keil C, Ziegler M. Poly(ADP-ribosylation) and genomic stability. *Biochem Cell Biol* 2005; 83: 263-269.
  43. Ohgaki H, Eibl RH, Schwab M, Reichel MB, Mariani L, Gehring M, Petersen I, Höll T, Wiestler OD, Kleihues P. Mutations of the p53 tumor suppressor gene in neoplasms of the human nervous system. *Mol Carcinog* 1993; 8: 74-80.
  44. Ohkoudo M, Sawa H, Hara M, Saruta K, Aiso T, Ohki R, Yamamoto H, Maemura E, Shiina Y, Fujii M, Saito I. Expression of p53, MDM2 protein and Ki-67 antigen in recurrent meningiomas. *J Neurooncol* 1998; 38: 41-49.
  45. Omulecka A, Papierz W, Nawrocka-Kunecka A, Lewy-Trenda I. Immunohistochemical expression of progesterone and estrogen receptors in meningiomas. *Folia Neuropathol* 2006; 44: 111-115.
  46. Ozen O, Demirhan B, Altinors N. Correlation between histological grade and MIB-1 and p53 immunoreactivity in meningiomas. *Clin Neuropathol* 2005; 24: 219-224.
  47. Perry A, Scheithauer BW, Stafford SL, Lohse CM, Wollan PC. "Malignancy" in meningiomas: a clinicopathologic study of 116 patients, with grading implications. *Cancer* 1999; 85: 2046-2056.
  48. Perry A, Stafford SL, Scheithauer BW, Suman VJ, Lohse CM. The prognostic significance of MIB-1, p53, and DNA flow cytometry in completely resected primary meningiomas. *Cancer* 1998; 82: 2262-2269.
  49. Prayson RA. Malignant meningioma: a clinicopathologic study of 23 patients including MIB1 and p53 immunohistochemistry. *Am J Clin Pathol* 1996; 105: 719-726.
  50. Pykett MJ, Landers J, George DL. Expression patterns of the p53 tumor suppressor gene and the mdm2 proto-oncogene in human meningiomas. *J Neurooncol* 1997; 32: 39-44.
  51. Rojo F, García-Parra J, Zazo S, Tusquets I, Ferrer-Lozano J, Menendez S, Eroles P, Chamizo C, Servitja S, Ramírez-Merino N, Lobo F, Bellosillo B, Corominas JM, Yelamos J, Serrano S, Lluch A, Rovira A, Albanell J. Nuclear PARP-1 protein overexpression is associated with poor overall survival in early breast cancer. *Ann Oncol* 2012; 23: 1156-1164.
  52. Sabisz M, Wesierska-Gadek J, Skladanowski A. Increased cytotoxicity of an unusual DNA topoisomerase II inhibitor compound C-1305 toward HeLa cells with downregulated PARP-1 activity results from re-activation of the p53 pathway and modulation of mitotic checkpoints. *Biochem Pharmacol* 2010; 79: 1387-1397.
  53. Schiewer MJ, Goodwin JF, Han S, Brenner JC, Augello MA, Dean JL, Liu F, Planck JL, Ravindranathan P, Chinnaiyan AM, McCue P, Gomella LG, Raj GV, Dicker AP, Brody JR, Pascal JM, Centenera MM, Butler LM, Tilley WD, Feng FY, Knudsen KE. Dual roles of PARP-1 promote cancer growth and progression. *Cancer Discov* 2012; 2: 1134-1149.
  54. Songin M, Ješko H, Czapski G, Adamczyk A, Strosznajder RP. GSK-3beta and oxidative stress in aged brain. Role of poly(ADP-ribose) polymerase-1. *Folia Neuropathol* 2007; 45: 220-229.
  55. Strosznajder R, Gadamski R, Walski M. Inhibition of poly(ADP-ribose) polymerase activity protects hippocampal cells against morphological and ultrastructural alteration evoked by ischemia-reperfusion injury. *Folia Neuropathol* 2005; 43: 156-165.
  56. Taraszewska A, Matyja E. Lectin binding pattern in meningiomas of various histological subtypes. *Folia Neuropathol* 2007; 45: 9-18.
  57. Terzi A, Saglam EA, Barak A, Soylemezoglu F. The significance of immunohistochemical expression of Ki-67, p53, p21, and p16 in meningiomas tissue arrays. *Pathol Res Pract* 2008; 204: 305-314.
  58. Wieler S, Gagné JP, Vaziri H, Poirier GG, Benchimol S. Poly(ADP-ribose) polymerase-1 is a positive regulator of the p53-mediated G1 arrest response following ionizing radiation. *J Biol Chem* 2003; 278: 18914-18921.
  59. Wiemels J, Wensch M, Claus EB. Epidemiology and etiology of meningioma. *J Neurooncol* 2010; 99: 307-314.
  60. Yu SW, Andrabi SA, Wang H, Kim NS, Poirier GG, Dawson TM, Dawson VL. Apoptosis-inducing factor mediates poly(ADP-ribose) (PAR) polymer-induced cell death. *Proc Natl Acad Sci USA* 2006; 103: 18314-18319.
  61. Yu SW, Wang H, Poitras MF, Coombs C, Bowers WJ, Federoff HJ, Poirier GG, Dawson TM, Dawson VL. Mediation of poly(ADP-ribose) polymerase-1-dependent cell death by apoptosis-inducing factor. *Science* 2002; 297: 259-263.
  62. Zhang Q, Li Y, Li X, Zhou W, Shi B, Chen H, Yuan W. PARP-1 Val762Ala polymorphism, CagA+ H. pylori infection and risk for gastric cancer in Han Chinese population. *Mol Biol Rep* 2009; 36: 1461-1467.