

# Myocardial infarction in a patient with moderate haemophilia A

Zawał mięśnia sercowego u pacjenta z umiarkowaną hemofilią A

Ewa Czubak, Aleksandra Serwicka, Andrzej Dziekoński, Grzegorz Fitas

Department of Cardiology, Hospital in Starachowice, Poland

Post Kardiol Interw 2011; 7, 1 (23): 101-104  
DOI: 10.5114/pwki.2011.21198

## Abstract

We report a case of patient with a moderate haemophilia A and myocardial infarction. The patient underwent a successful coronary angioplasty preceded by factor VIII administration, nevertheless the double antiplatelet therapy was complicated by gastrointestinal bleeding, which occurred after the discharge. Additionally, the article discusses the treatment strategies of acute coronary syndrome in patients with haemophilia.

**Key words:** haemophilia A, myocardial infarction, percutaneous coronary intervention

## Streszczenie

Prezentujemy przypadek 61-letniego mężczyzny z umiarkowaną hemofilią A i zawałem mięśnia sercowego. U pacjenta wykonano skuteczny zabieg angioplastyki wieńcowej z implantacją stentu poprzedzony substytucją czynnika VIII. Zastosowana podwójna terapia przeciwplateletowa powikłana była krwawieniem z przewodu pokarmowego. W dalszej części pracy dokonujemy przeglądu strategii postępowania w ostrym zespole wieńcowym u pacjentów z hemofilią A.

**Słowa kluczowe:** hemofilia A, zawał mięśnia sercowego, angioplastyka wieńcowa

## Introduction

Haemophilia A is a hereditary coagulation disorder with recessive X-linked mode of transmission. It is caused by decreased activity of factor VIII in plasma. Before the development of specific therapies most patients with haemophilia died during childhood or in early adulthood due to bleeding complications [1]. After the introduction of treatment with factor VIII substitutes the number of deaths caused by bleeding related to haemophilia dropped and the mean survival time of the patients increased [2]. Aging of the population of patients with haemophilia caused an increase in the frequency of age-related diseases including coronary disease [3]. Below, we describe a case of a patient with moderate haemophilia A and anterior wall myocardial infarction.

## Case report

A 61-year-old male, a smoker, without a history of cardiovascular diseases, was admitted to the Cardiology

Department of the Regional Hospital in the second hour of typical anginal chest pain. Medical history of the patient included haemophilia A, hepatitis C and prior gastric resection due to duodenal ulcer. The patient was diagnosed with a moderate form of haemophilia (5% of factor VIII activity and no antibodies against factor VIII). During childhood the patient suffered from frequent spontaneous intra-arterial haemorrhages which in consequence led to arthropathy. Haemorrhages decreased spontaneously after 30 years of age. The patient received only one infusion of factor VIII concentrate due to tooth extraction 1.5 years before the present hospitalization. On admission he was in moderate general condition and had stenocardia. On physical examination he had pale skin and contractures of the cubital, knee and hip joints. Blood pressure was 125/90 mmHg, heart rhythm 75 bpm. There were no signs or symptoms of heart failure. ECG showed 2 mm high ST-segment elevation in leads V<sub>2</sub>-V<sub>4</sub>. Echocardiography performed on the day of admission demonstrated apical hypokinesis with

---

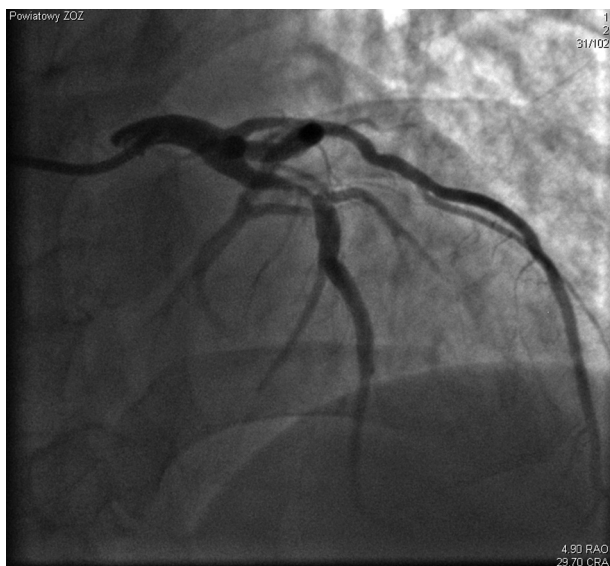
### Corresponding author/*Adres do korespondencji:*

Aleksandra Serwicka MD, Department of Cardiology, Hospital in Starachowice, ul. Radomska 70, 27-200 Starachowice, tel.: +48 41 273 96 10, fax: +48 41 273 90 67, e-mail: aserwicka@poczta.onet.pl

Praca wpłynęła 24.11.2010, przyjęta do druku 20.02.2011.

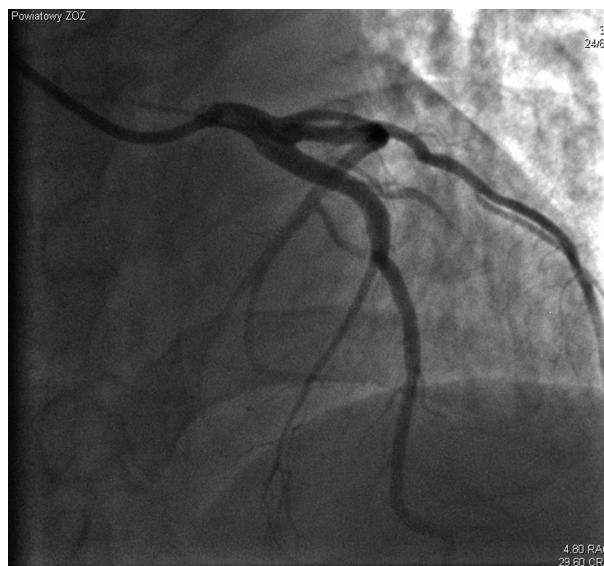
ejection fraction of 50%. Laboratory examinations on admission showed microcytic anaemia (Hgb 8.6 g/dl, Hct 31.1%, RBC  $4.81 \times 10^6/\mu\text{l}$ , MCV 64.7 fl), prolonged APTT of 60.7 sec, hypercholesterolaemia (total cholesterol 209 mg/dl, LDL 147.8 mg/dl, triglycerides 80 mg/dl). Due to anaemia the patient underwent surgical consultation, but no signs of active gastrointestinal bleeding were found. The patient refused coronary angiography and therefore conservative treatment was started. He received 300 mg of aspirin followed by a maintenance dose of 75 mg/d and 600 mg of clopidogrel followed by a maintenance dose of 75 mg/d, metoprolol  $2 \times 25$  mg/d, atorvastatin 40 mg/d and an intravenous infusion of nitroglycerine. Because of anaemia and persistent chest pain the patient received 2 units of red blood cells. Resting chest pain resolved after introduction of treatment. ECG performed during the following days of hospitalization demonstrated evolution of anterior wall myocardial infarction. Laboratory tests showed typical rise of biochemical markers of myocardial necrosis (CK-MB max. 40 U/l, troponin T max. 0.47  $\mu\text{g/l}$ ). On the 4<sup>th</sup> and 5<sup>th</sup> day of hospitalization the patient suffered from recurrent resting chest pains. After obtaining informed written consent the patient was prepared for invasive treatment. The patient was consulted in the Institute of Haematology and Transfusiology in Warsaw to determine the requirement for factor VIII to obtain its 80-100% activity in plasma. It was defined as 50 U/kg of body mass and therefore 3500 U of factor VIII was infused before coronary angiography performed using a transradial

approach. Angiography showed 90% stenosis of the proximal left anterior descending artery (LAD) segment including the ostium of a diagonal branch with TIMI 1 flow (fig. 1) and recessive right coronary artery with long stenosis of up to 90% in proximal and mid artery segments. Successful percutaneous coronary intervention (PCI) with bare metal stent implantation to the LAD was performed (fig. 2). The patient received 5000 IU of unfractionated heparin. During the remaining hospitalization the patient was given further doses of factor VIII as suggested by the haematologist: 40 U/kg of body mass 12 hours after PCI and on days 2-4, followed by 30 U/kg of body mass on days 5-7. Due to persistent anaemia the patient underwent gastroscopy which did not disclose any site of bleeding. The patient refused colonoscopy. There were no recurrences of chest pain or any bleeding complications until the end of hospitalization. The patient was discharged home on aspirin 75 mg/d, clopidogrel 75 mg/d, metoprolol prolonged-release 50 mg/d, ramipril 2.5 mg/d, atorvastatin 40 mg/d and pantoprazole  $2 \times 20$  mg. On telephone contact 2 months after discharge the patient reported 2 episodes of massive gastrointestinal bleeding (on days 39 and 61 after myocardial infarction). During the first hospitalization he was diagnosed with erosive gastritis, but subsequent hospitalization did not disclose any site of bleeding. After cardiological consultation aspirin was discontinued. At present the patient is on chronic therapy with clopidogrel and factor VIII and is scheduled to undergo further gastrointestinal examinations.



**Fig. 1.** Coronary angiogram before PCI – 90% stenosis in proximal segment of LAD

**Ryc. 1.** Koronarografia u pacjenta przed zabiegiem PCI – 90-procentowe zwężenie w proksymalnym segmencie gałęzi międzykomorowej przedniej obejmujące ostium gałęzi diagonalnej



**Fig. 2.** Coronary angiogram after stent implantation  
**Ryc. 2.** Obraz angiograficzny po zabiegu skutecznej angioplastyki

## Discussion

The frequency of cardiovascular incidents and mortality related to coronary artery disease is lower in patients with haemophilia in comparison to the general population [2, 3]. It was demonstrated that reduction of mortality is not related to lower prevalence of typical cardiovascular risk factors [4]. Lower mortality caused by coronary artery disease in patients with haemophilia is probably caused by lower activity of factor VIII [5]. Furthermore, it seems that infusion of factor VIII substitutes may cancel the protective effect of haemophilia on onset of coronary disease. Most cases of acute coronary syndromes (ACS) described in the literature occurred after substitution of factor VIII [6-8]. Low activity of factor VIII probably protects against thrombus formation in coronary arteries, but it does not protect against the development of atherosclerotic plaques [9].

At present there are no uniform guidelines on the treatment of patients with ACS and haemophilia. Management is based on the general guidelines of the European Society of Cardiology (ESC) on ACS and on a few cases of treatment of such patients described in the literature [10]. The preferred mode of treatment in ACS is to perform PCI [10], which in patients with haemophilia is related to higher risk of bleeding complications. To reduce the risk of local bleeding it is recommended to use transradial access [11], although there have been cases of uncomplicated PCI procedures performed using a transfemoral approach [12, 13]. PCI in patients with haemophilia should be performed under factor VIII concentrate protection. There are no uniform guidelines for percutaneous procedures and therefore it is accepted that the activity of factor VIII during the procedure should be similar to that recommended for surgical procedures, i.e. 80-100% [11, 14, 15]. Increase of bleeding risk is also related to the obligatory administration of antithrombotic drugs during PCI. In that case we used unfractionated heparin. Bivalirudin, a direct thrombin inhibitor, is an alternative drug, especially in patients with increased risk of bleeding complications [10, 15, 16]. It does not require APTT monitoring and causes fewer bleeding complications [17]. There are no described bleeding complications during PCI in patients with haemophilia performed on heparin or bivalirudin in the literature. A major concern in patients with myocardial infarction and haemophilia is related to the need for dual antiplatelet therapy (aspirin and clopidogrel). Among similar cases (treated with PCI) described in the literature, there were patients who did not receive antiplatelet drugs [18], some who received aspirin or clopidogrel [7, 8], but most of them received typical dual antiplatelet therapy [6, 12, 13, 15, 16]. Some patients on dual antiplatelet therapy experienced non-life-threatening bleeding complications (bleeding from the gums, ecchymoses, purpura, joint haemorrhages), which required discontinuation of one of the drugs [6, 12, 16]. The

described patient suffered from massive gastrointestinal bleeding which required discontinuation of aspirin, but not clopidogrel. This case illustrates major difficulties in management of patients with ACS and haemophilia A caused by the delicate balance between antithrombotic and antiplatelet treatment and prevention of bleeding complications in the course of congenital coagulation disorders.

## References

1. Mauser-Bunschoten EP, Fransen Van De Putte DE, Schutgens RE. Co-morbidity in the ageing haemophilia: the down side of increased life expectancy. *Haemophilia* 2009; 15: 853-863.
2. Darby SC, Kan SW, Spooner RJ, et al. Mortality rates, life expectancy, and causes of death in people with hemophilia A or B in the United Kingdom who were not infected with HIV. *Blood* 2007; 110: 815-825.
3. Kulkarni R, Soucie JM, Evatt BL. Prevalence and risk factors for heart disease among males with hemophilia. *Am J Hematol* 2005; 79: 36-42.
4. Rosendaal FR, Briët E, Stibbe J, et al. Haemophilia protects against ischaemic heart disease: a study of risk factors. *Br J Haematol* 1990; 75: 525-530.
5. Sramek A, Kriek M, Rosendaal FR. Decreased mortality of ischaemic heart disease among carriers of haemophilia. *Lancet* 2003; 362: 351-354.
6. Günaldi M, Helvacı A, Yildirim ND, et al. Acute myocardial infarction in a patient with hemophilia A and factor V Leiden mutation. *Cardiol J* 2009; 16: 458-461.
7. Kerkhoffs JL, Atsma DE, Oemrawsingh PV, et al. Acute myocardial infarction during substitution with recombinant factor VIII concentrate in a patient with mild haemophilia A. *J Thromb Haemost* 2004; 92: 425-426.
8. Girolami A, Ruzzon E, Fabris F, et al. Myocardial infarction and other arterial occlusions in hemophilia a patients. A cardiological evaluation of all 42 cases reported in the literature. *Acta Haematol* 2006; 116: 120-125.
9. Foley CJ, Nichols L, Jeong K, et al. Coronary atherosclerosis and cardiovascular mortality in hemophilia. *J Thromb Haemost* 2010; 8: 208-211.
10. The Task Force on the management of ST-segment elevation acute myocardial infarction of the European Society of Cardiology. *Eur Heart J* 2008; 29: 2909-2945.
11. Dziewierz A, Dudek D. Jak postępować u chorego z ostrym zespołem wieńcowym, gdy współistnieją zaburzenia hematologiczne – punkt widzenia kardiologa interwencyjnego. *Post Kardiol Interw* 2008; 4: 164-172.
12. Smolka G, Kulach A, Dabek J, et al. Percutaneous coronary intervention with stent implantation in haemophilic A patient with unstable angina. *Haemophilia* 2007; 13: 428-431.
13. Wójcik D, Rekosz J, Woźniak J, Leszczyński L. Zawał serca u chorego z hemofilią typu A. *Kardiol Pol* 2003; 59: 417-420.
14. Guidelines for the management of hemophilia. ©World Federation of Hemophilia, 2005, Montréal, Canada at [www.wfh.org](http://www.wfh.org)
15. Arora UK, Dhir M, Cintron G, et al. Successful multi-vessel percutaneous coronary intervention with bivalirudin in a patient with severe hemophilia A: a case report and review of literature. *J Invasive Cardiol* 2004; 16: 330-332.

16. Quintero D, Biria M, Meyers DG. Percutaneous coronary intervention in a patient with acute ST-elevation myocardial infarction and hemophilia A. *J Invasive Cardiol* 2008; 20: 240-241.
17. Stone GW, Witzenbichler B, Guagliumi G, et al. for the HORIZONS-AMI Trial Investigators. Bivalirudin during Primary PCI in Acute Myocardial Infarction. *N Engl J Med* 2008; 358: 2218-2230.
18. Ergelen M, Osmonov D, Gunaydin ZY, et al. Acute inferior myocardial infarction in a patient with severe haemophilia A disease. *Ann Hematol* 2009; 88: 711-712.