

ST-elevation myocardial infarction with local infusion of abciximab using thrombectomy catheter in a patient with very late stent thrombosis

Zawał serca z uniesieniem odcinka ST spowodowany późną zakrzepicą w stencie metalowym, leczony dowieńcowym podaniem abciksimabu oraz aspiracyjną trombektomią

Zbigniew Siudak¹, Jacek Godlewski², Leszek Badacz¹

¹Department of Interventional Cardiology, Intercard, Pinczow, Poland

²Department of Interventional Cardiology, John Paul II Hospital, Krakow, Poland

Postep Kardiol Inter 2012; 8, 4 (30): 338–341

DOI: 10.5114/pwki.2012.31916

Abstract

A case of a 56-year-old male with a diagnosis of ST-segment elevation myocardial infarction caused by in-stent thrombosis in a previously implanted bare metal stent after discontinuation of aspirin is presented. On admission there were ST segment elevations in leads II, III, aVF with Q wave in III and aVF in the electrocardiogram. Three years before the admission patient had suffered from inferior wall myocardial infarction and was treated successfully with primary percutaneous coronary intervention (PPCI) of the right coronary artery with bare metal stent (BMS) implantation. Twelve months after the index PPCI patient stopped receiving all medications including ASA. He felt he was in good health condition and did not need to take medications any longer. For the next 2 years he had never visited doctor for follow-up visit. In current angiography occlusion of the right coronary artery with thrombus was identified. Patient was treated with aspiration thrombectomy which revealed large thrombus burden and with intralesion administration of bolus of abciximab via thrombectomy catheter. Afterwards PCI with drug eluting stent implantation was performed. Patient was discharged home after 5 days. At discharge his antiplatelet therapy consisted of acetylsalicylic acid (75 mg once daily) for life, and clopidogrel (75 mg once daily, for at least 12 months).

Key words: abciximab, myocardial infarction, thrombectomy, stent thrombosis

Streszczenie

Przedstawiono przypadek 56-letniego pacjenta z zawałem serca z uniesieniem odcinka ST spowodowanego późną zakrzepicą w stencie metalowym po odstawieniu leczenia przeciwpłytkowego kwasem acetylosalicylowym. Przy przyjęciu do pracowni hemodynamiki w zapisie elektrokardiograficznym obserwowano uniesienia odcinka ST o charakterze falii Pardeego w odprowadzeniach II, III, aVF oraz patologiczne załamki Q w III i aVF. Trzy lata wcześniej pacjent miał wykonaną przezskórną interwencję wieńcową w zakresie prawej tętnicy wieńcowej połączoną z implantacją stentu metalowego z powodu świeżego zawału serca. Zabieg wykonano optymalnie, przebiegł bez powikłań. Dwanaście miesięcy po przezskórnej interwencji wieńcowej chory przestał zażywać leki, w tym kwas acetylosalicylowy, ponieważ czuł się dobrze. Przez następne 2 lata nie zażywał żadnych leków i nie był u kontroli u lekarza. W obecnym badaniu koronarograficznym stwierdzono zamknięcie prawej tętnicy wieńcowej z obecnością dużej skrzepliny. Zastosowano trombektomię aspiracyjną systemem 6 F. W koszyczku uwidoczniło się dużą ilość odessanego materiału zakrzepowego i zatorowego. Następnie podano dowieńcowo bolus abciksimabu i uzyskano znaczącą redukcję skrzepliny. Ostatecznie wykonano przezskórną interwencję wieńcową z implantacją stentu pokrytego lekiem. Pacjenta wypisano do domu po 5 dniach z zaleceniem zażywania kwasu acetylosalicylowego w dawce 75 mg do końca życia oraz klopidogrelu w dawce 75 mg przez minimum 12 miesięcy. Planowa angioplastyka wieńcowa w zakresie krytycznie zwężonej gałęzi okalającej została zaplanowana 3–4 tygodnie później.

Słowa kluczowe: abciksimab, zawał serca, trombektomia, zakrzepica

Corresponding author/*Adres do korespondencji:*

Zbigniew Siudak MD, PhD, Department of Interventional Cardiology, Intercard, 22 Armii Krajowej St, 28-400 Pinczow, Poland, tel.: +48 41 370 10 94, e-mail: zbigniew.siudak@gmail.com

Praca wpłynęła: 14.08.2012, **przyjęta do druku:** 31.08.2012.

Introduction

Stent thrombosis although more rare with new antiplatelet drugs (prasugrel, ticagrelor) but also improved stent platforms is still a life-threatening issue in patients after percutaneous coronary interventions (PCI) both with drug-eluting and bare metal stents. In daily practice, however, it is not only confined to the first months or the first year after the procedure but may unexpectedly occur at a later time. Unfortunately, it is usually associated with patient non-compliance to prescribed dual antiplatelet therapy.

We report a case of acute myocardial infarction caused by late in-stent thrombosis successfully treated with a combination of intralesional administration of abciximab and thrombus aspiration with a thrombectomy device in a patient who discontinued acetylsalicylic acid 1 year after the initial PCI procedure with bare metal stent (BMS) implantation.

Case report

A 56-year-old male patient was transferred directly from his home by ambulance to our department with a working diagnosis of ST-segment elevation myocardial infarction (STEMI). He complained of a burning retrosternal chest pain lasting approximately 11 h. There were ST segment elevations in leads II, III and aVF with Q wave in III and aVF in the electrocardiogram on admission (Fig. 1). The patient was haemodynamically stable with minor crepitation over lungs (Killip class II), with arterial blood pressure of 130/85 mm Hg and regular pulse rate of 65 beats per minute. His risk factors included arterial hypertension, hypercholesterolaemia and smoking habit. Three years before admission the patient had suffered from inferior wall myocardial infarction and was treated successfully with primary percutaneous coronary intervention (PPCI) of the right coronary artery with BMS implantation. The final outcome of that PPCI was optimal with TIMI 3 flow. The patient was

prescribed dual antiplatelet therapy with acetylsalicylic acid (ASA) (75 mg once daily) for life and clopidogrel (75 mg once daily) for 12 months. Twelve months after the index PPCI the patient stopped receiving all medications including ASA. He felt he was in a good health condition and did not need to take medications any longer. For the next 2 years he had never visited the doctor for a follow-up visit.

During the transfer by ambulance the patient received 300 mg of aspirin and 300 mg of clopidogrel. On admission to our cath lab 300 mg of clopidogrel were added on top of previous medications. Immediate coronary angiography using a right femoral access site and standard 6 F diagnostic catheters was performed, revealing an acute occlusion of the proximal right coronary artery (infarct-related artery) with large thrombus burden probably caused by in-stent thrombosis (Fig. 2 A). The remaining vessels were normal with the exception of an 85% diameter stenosis in the circumflex artery. Percutaneous coronary intervention of the infarct-related artery was started using a Launcher (Medtronic Vascular, USA) 6 French Judkins right 4.0 guiding catheter. A bolus of unfractionated heparin was administered (9000 IU). Appropriate anticoagulation was confirmed by activated clotting time measurement (> 250 s). The occlusion was crossed with a 0.014-inch Whisper ES (Abbott Vascular, USA) guidewire. Then three consecutive passages with Export aspiration catheter (Medtronic Vascular, USA) were performed. Large thrombus debris was visualized and retrieved from the coronary artery (Fig. 3). Partial flow was restored in the artery with a visible remaining thrombus proximally to the previously implanted stent with signs of restenosis and residual thrombus (Fig. 2 B). At that point a standard bolus of abciximab (ReoPro by Eli Lilly and Company) was administered through the thrombectomy catheter slowly to the lesion. A significant reduction of thrombus burden was observed (Fig. 2 C). The continuous *i.v.* infusion of abciximab was continued for 24 h. At that stage predilatation with a Maverick (Boston Scientific, USA) balloon catheter 2.5 mm × 20 mm

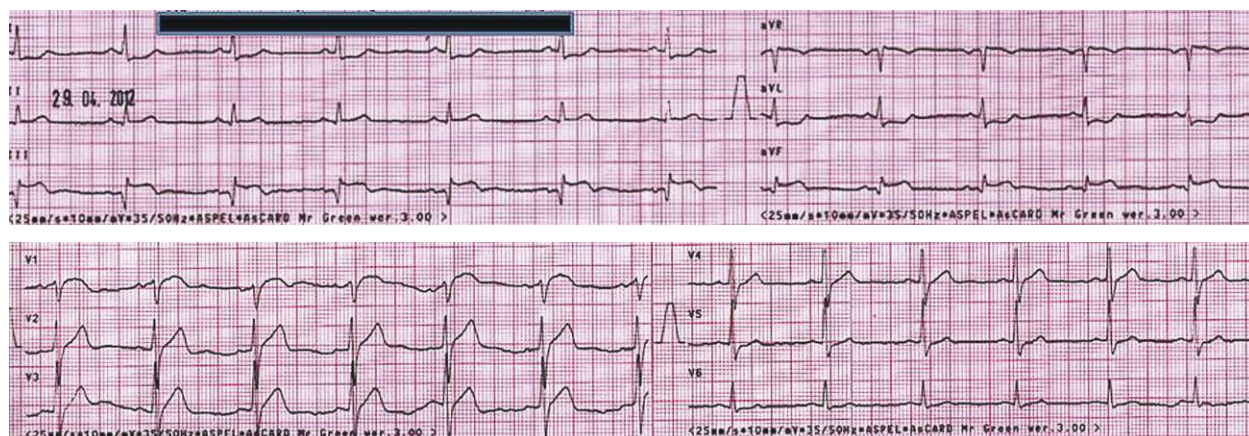


Fig. 1. ECG on admission to cath lab

Ryc. 1. EKG przy przyjęciu do pracowni hemodynamiki

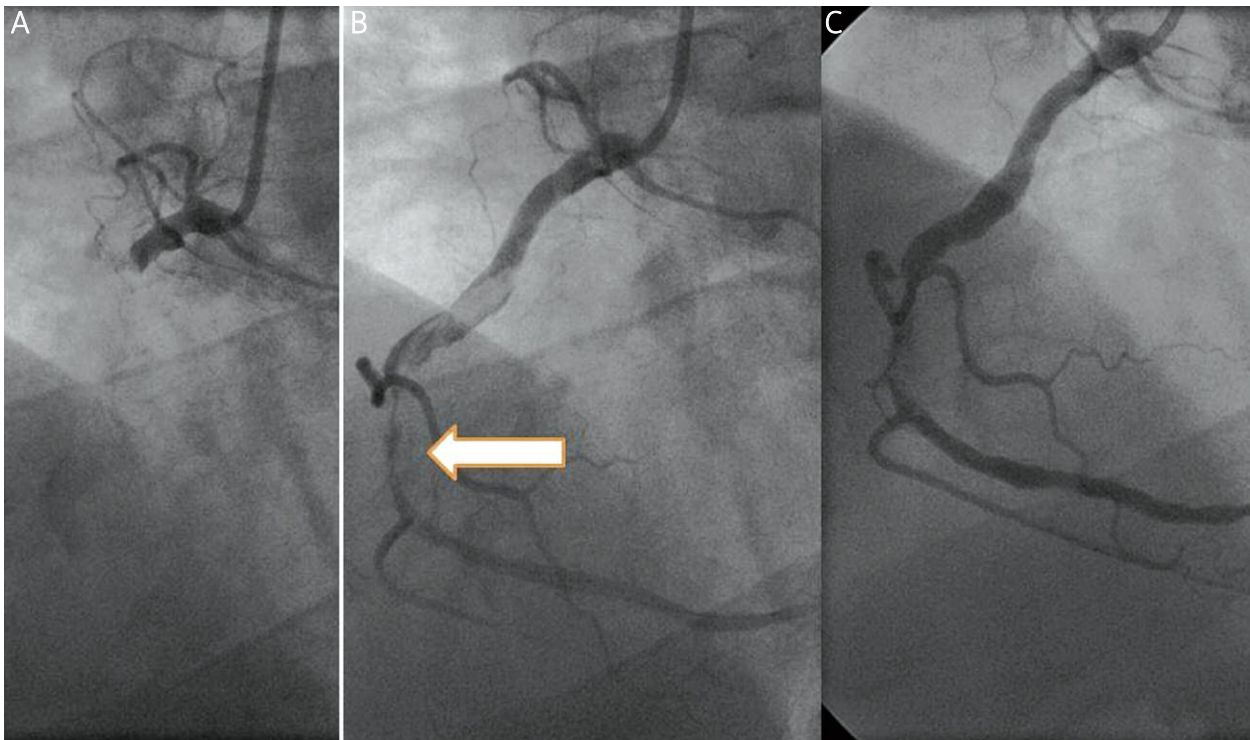


Fig. 2. **A** – Initial angiography of right coronary artery. **B** – Angiography after thrombectomy (previously implanted stent is marked by arrow). **C** – Angiography after abciximab bolus infusion

Fig. 2. **A** – Wyjściowa angiografia prawej tętnicy wieńcowej. **B** – Angiografia po trombektomii (strzałką zaznaczono poprzednio implantowany stent). **C** – angiografia po podaniu bolusa abciksimabu

at 18 atm was performed with transient slow-flow. Due to persistent stenosis a BMS, Prokinetic (Biotronik, Germany) 4.0 mm × 15 mm, at 18 atm was implanted at the site of the previous stent. The operator decided to implant

a BMS due to large vessel diameter and expected poor patient compliance to the prescribed antiplatelet therapy (Fig. 4). After PCI the patient was symptom-free and peak levels of cardiac markers after PCI were: CK 2359 IU/l,

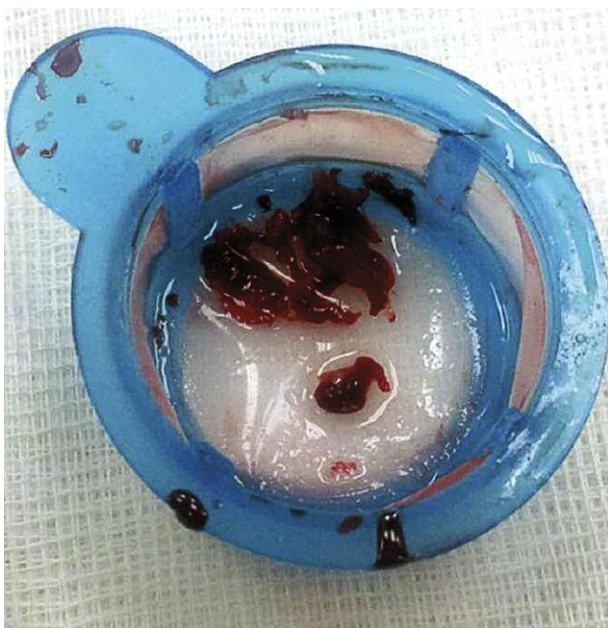


Fig. 3. Thrombus debris
Fig. 3. Materiał zakrzepowy

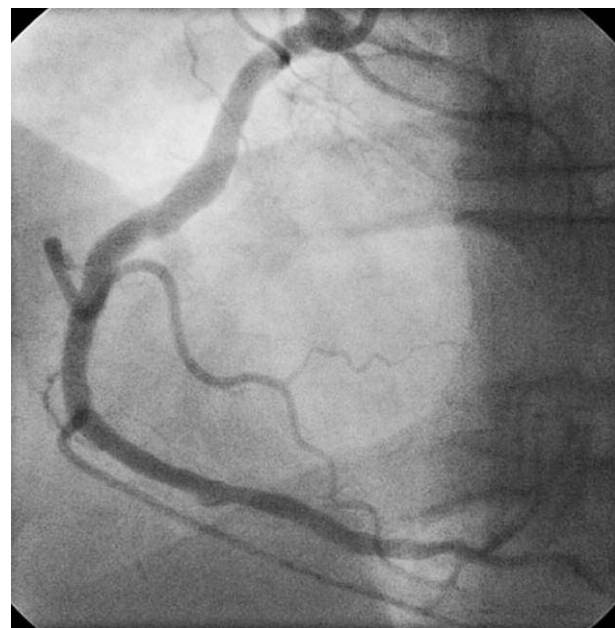


Fig. 4. Final angiography of right coronary artery
Ryc. 4. Ostateczny wynik zabiegu w prawej tętnicy wieńcowej

CK-MB 248 IU/l and troponin T hs 3446 ng/ml (cut-off value 14 ng/ml). In the control echocardiogram the left ventricular ejection fraction was 50% with akinesia of the inferior wall. The patient was discharged home after 5 days. At discharge his antiplatelet therapy consisted of ASA (75 mg once daily) for life, and clopidogrel (75 mg once daily, for at least 12 months). Percutaneous coronary intervention of the circumflex artery was scheduled 3 weeks after discharge.

Discussion

In the real world scenario poor compliance to prescribed antiplatelet therapy in patients after acute coronary syndromes is quite common [1]. Although stent thrombosis is more rare with new antiplatelet drugs (prasugrel, ticagrelor) and improved stent platforms, it is still a life-threatening issue in patients after PCI both with drug-eluting and bare metal stent implantation [2]. The predicted probability of stent thrombosis is not solely confined to drug eluting stent (DES) because there are still reports of very late stent thrombosis in BMS as well [3]. In the majority of cases the discontinuation of dual antiplatelet therapy is blamed; however, it seems that cessation of ASA routinely used as secondary prevention years after STEMI might be deleterious as well. On the other hand, such late thrombosis might be attributed to procedural flaws such as stent underexpansion or poor neointimal healing. In our patient it seems that both progression of the atherosclerosis (no statin use) and thrombosis (no antiplatelet medications) at the site of the previously implanted stent caused the acute coronary syndrome (ACS).

The once debatable issue of DES use in STEMI patients is now gone as the safety profile of new generation DES and their performance in terms of efficacy is well proven [4, 5]. The current European NSTEMI and updated ACC/AHA STEMI guidelines recommend DES use on an individual basis taking into account baseline characteristics and bleeding risks; however, BMS use for suitable patients is still an option [6]. In Poland the penetration of DES among ACS patients is ca. 35%, which is fairly low in comparison to other European countries.

The novel approach in our case is the use of intralésional abciximab combined with already guideline-recommended thrombus aspiration [6]. In some cases glycoprotein GP IIb/IIIa inhibitors such as abciximab are used as an intravenous bolus followed by infusion during primary PCI for STEMI as an adjunctive and efficient therapy [7]. There are still no convincing results proving the clinical benefit of intracoronary over intravenous use of abciximab in STEMI patients and the results of studies such as AIDA STEMI are negative [8]. A new concept of intralésional administration of abciximab directly to the thrombus by a dedicated new balloon catheter (Clearway, Atrium, USA) was tested in the INFUSE AMI trial [9]. Local administration of abciximab was associated with significant reduc-

tion of the infarct size assessed by cardiac magnetic resonance at 30 days after the first, anterior wall STEMI in comparison to no abciximab, but the most pronounced benefit was observed when local infusion of abciximab was combined with prior thrombectomy. It seems that such administration in vulnerable patients with a large thrombus burden might facilitate thrombectomy itself.

In conclusion, both intralésional abciximab administration and thrombus aspiration may be considered for patients with an occluded artery with a high thrombus burden, i.e. caused by stent thrombosis, but the efficacy of such an algorithm still needs to be evidenced in large clinical trials.

References

1. De Servi S, Roncella A, Reimers B. Causes and clinical implications of premature discontinuation of dual antiplatelet therapy. *Curr Opin Cardiol* 2011; 26 Suppl 1: S15-21.
2. Buchanan GL, Basavarajaiah S, Chieffo A. Stent thrombosis: incidence, predictors and new technologies. *Thrombosis* 2012; 2012: 956962. Epub 2012 Mar 11.
3. Yamaji K, Inoue K, Nakahashi T, et al. Bare metal stent thrombosis and in-stent neoatherosclerosis. *Circ Cardiovasc Interv* 2012; 5: 47-54.
4. Kalesan B, Pilgrim T, Heinemann K, et al. Comparison of drug-eluting stents with bare metal stents in patients with ST-segment elevation myocardial infarction. *Eur Heart J* 2012; 33: 977-87.
5. De Luca G, Dirksen MT, Spaulding C, et al; Drug-Eluting Stent in Primary Angioplasty (DESERT) Cooperation. Drug-eluting vs bare-metal stents in primary angioplasty: a pooled patient-level meta-analysis of randomized trials. *Arch Intern Med* 2012; 172: 611-21.
6. Wijns W, Kolh P, Danchin N, et al. Guidelines on myocardial revascularization. *Eur Heart J* 2010; 31: 2501-55.
7. Montalescot G, Antoniucci D, Kastrati A, et al. Abciximab in primary coronary stenting of ST-elevation myocardial infarction: a European meta-analysis on individual patients' data with long-term follow-up. *Eur Heart J* 2007; 28: 443-9.
8. Thiele H, Wöhrle J, Hambrecht R, et al. Intracoronary versus intravenous bolus abciximab during primary percutaneous coronary intervention in patients with acute ST-elevation myocardial infarction: a randomised trial. *Lancet* 2012; 379: 923-31.
9. Stone GW, Maehara A, Witzenbichler B, et al; INFUSE-AMI Investigators. Intracoronary abciximab and aspiration thrombectomy in patients with large anterior myocardial infarction: the INFUSE-AMI randomized trial. *JAMA* 2012; 307: 1817-26.