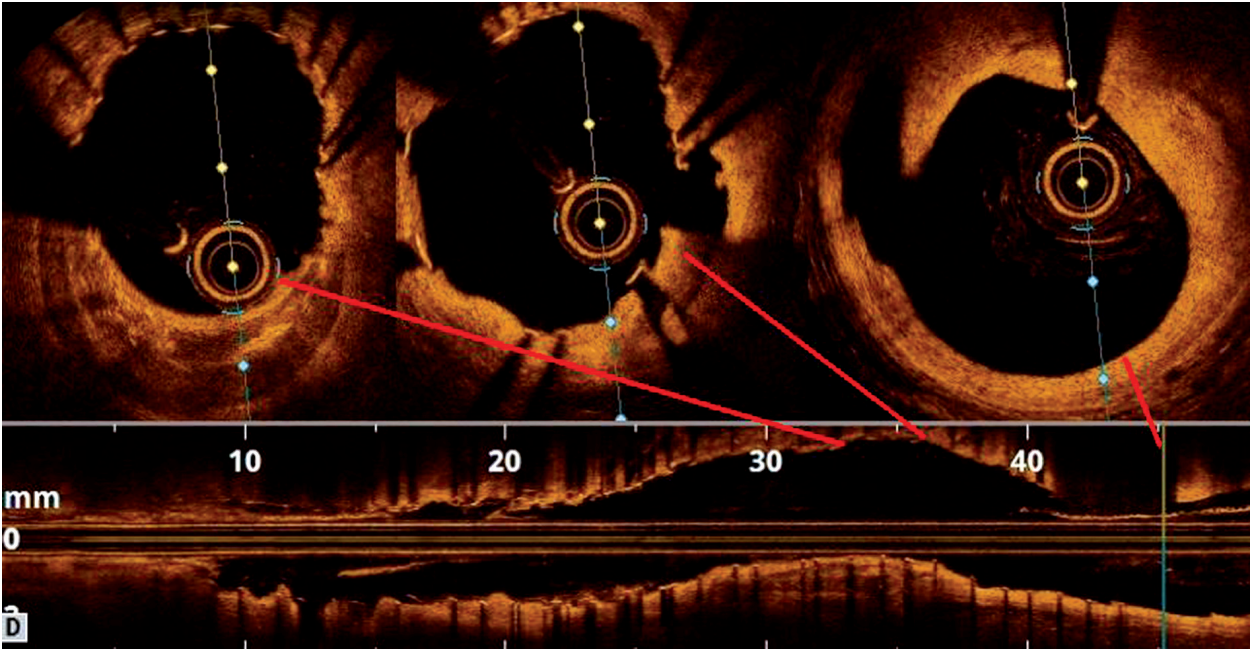
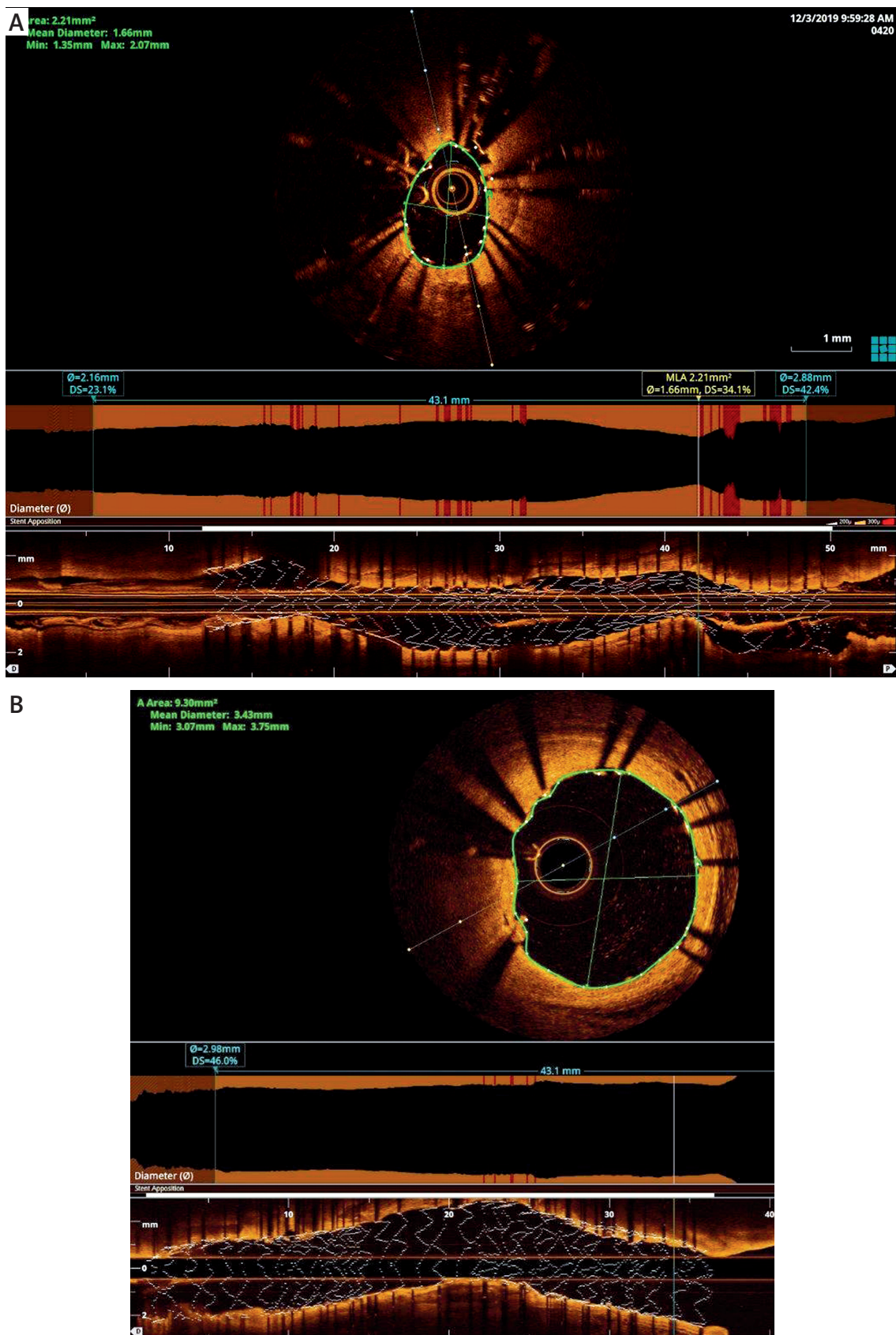


Supplementary



Supplementary Figure S1. Dissection of proximal LAD in OCT after intravascular lithotripsy pulses and NC balloon inflation



Supplementary Figure S2. Minimal lumen area and diameter of proximal segment of the stent before (A) and after intervention (B)