

Elastography as a new diagnostic tool to detect breast cancer – evaluation of research and clinical applications

Elastografia jako nowe narzędzie wykrywania raka piersi – ocena badań i zastosowań klinicznych

Paweł Rzymyński, Tomasz Opala

Department of Mother's and Child's Health, University of Medical Science Poznan, Gynaecological and Obstetric University Hospital, Poznan, Poland;

head of Department: prof. dr hab. n. med. Tomasz Opala

Przeгляд Menopauzalny 2011; 5: 357–362

Summary

Mammography and ultrasonography are currently the most sensitive methods for detecting breast cancer, but elastography is a new diagnostic tool. Stiffness of invasive carcinomas were found to be 5-25 times larger than that of normal adipose tissue. There are basically two types of elastography examination used in initial clinical research: conventional elastography with compression and shear wave elastography. Analysis of 20 studies in the years 1997-2010 with 1484 malignant and 2822 benign breast lesions is presented in this paper. The overall sensitivity was 67-100% with specificity of 62-99% for elastography. This raises the hope of introducing this method in the BI-RADS classification and modifying diagnostics in category 3-4.

Key words: elastography, breast cancer, ultrasound, sonoelastography, cancer detection.

Streszczenie

Mammografia i ultrasonografia są obecnie najbardziej czułymi metodami wykrywania raka piersi, jednak elastografia coraz częściej wymieniana jest jako nowe narzędzie diagnostyczne. Wykryto, że sztywność tkanki raka inwazyjnego jest 5–25 razy większa niż prawidłowej tkanki tłuszczowej. Istnieją dwa rodzaje badania elastograficznego stosowane we wstępnych badaniach klinicznych: elastografia klasyczna (z kompresją) i elastografia z wykorzystaniem fal poprzecznych. W artykule tym przedstawiono analizę 20 badań z lat 1997–2010 obejmujących 1484 zmiany złośliwe sutka i 2822 łagodne. Całkowita czułość elastografii wynosiła 67–100%, podczas gdy specyficzność 62–99%. Wyniki są obiecujące i stwarzają możliwość wykorzystania tej metody w ocenie BI-RADS oraz modyfikacji diagnostyki w stopniach 3–4.

Słowa kluczowe: elastografia, rak piersi, ultrasonografia, sonoelastografia, wykrywanie raka.

Introduction

Breast cancer remains a great cause of concern worldwide. Non-invasive diagnostic tools remain a major clinical problem. Mammography and ultrasonography are currently the most sensitive methods for detecting breast cancer. But in some nationalities women have relatively small and dense breasts, which is one of the factors leading to false negative results in mammography. Both methods are complementary, not substitutes, but there is great desire not to miss any malignant lesion in the early stage of the disease. This produces an

aggressive rate of breast biopsies of 10-30% for cancer and 70-90% because of benign conditions. The unnecessary high rate of biopsies results in higher costs and stress in women. In several conditions such as in microcalcifications mammography shows limited specificity in routine screening [1-3].

Elastography rationale

Elastic properties of human tissues raised the interest for medical applications. Elastography is an ima-

Address for correspondence:

Paweł Rzymyński, Department of Mother's and Child's Health, University of Medical Science Poznań, Gynaecologic and Obstetric University Hospital, Polna St. 33, 60-535 Poznan, Poland, Email: parzymysk@gpsk.am.poznan.pl

ging technique developed over the last 20 years and offers new imaging possibilities of soft tissues. Among them, the breast is an ideal organ of interest, which is

easily accessible, and there is still a need to improve the diagnostics and survival in one of the most frequent cancers worldwide. Unlike palpation, which is qualitative, elastography is capable of detecting smaller, deeper and providing quantitative information on their stiffness as characterized by elastic moduli [1, 4]. The elastic properties of tissues can be described by Young's modulus, which is defined as:

$$E = \sigma / \varepsilon$$

where σ is the applied stress and ε is the resultant deformation of the tissue (strain). Results from ex vivo research were very promising. The authors indicated that the range of variations of Young's moduli in breast tissues was about two orders of magnitude, extending from a fraction of kPa for normal tissues. In cancers with microcalcifications it rose to over 20 kPa. Dependent on pre-compression (5-20%), Young's moduli of invasive carcinomas were found to be 5-25 times larger than that of normal adipose tissue. Breast tissues are characterized by nonlinear elastic behaviour, which is common in soft tissues [4, 5].

In studies by Samani et al., normal fat and glandular tissue represented Young's moduli of 3.25 kPa and 3.24 kPa respectively [4]. In other studies, similar results have been reported [6, 7]. Fibroadenomas were stiffer (6.41 kPa), and malignant lesions much more (DCIS – ductal carcinoma in situ; 16.38 kPa, IDC – invasive ductal carcinoma; 10.4-42.52 kPa, ILC – invasive lobular carcinoma; 15.62 kPa) [4]. Current methods allow a freehand technique in vivo to be used in commercially available breast sonography equipment. There are basically two types of elastography examination used in initial clinical research: conventional elastography and shear wave elastography. Conventional elastography requires compression of tissues. Then the echo before and after compression is analysed, providing a colour coded map of elasticity superimposed on a B-mode scan. In recent years a real-time system has been developed, but it still did not eliminate one of the possible errors – compression, which is operator-dependent. With freehand compression the influence of probe movement has certain disadvantages. It is commonly known that the elasticity map obtained in this method is highly dependent on the organ's compressibility limits under stress and the force used [1, 2, 8-14]. For clinical evaluation a special elastography morphological scoring system has been developed to examine breast lesions. Depending on the elastography equipment system, some differences in details occur, but generally they resemble that described by Itoh et al. [13]. The scoring system modified according to newly developed shear wave elastography equipment is presented in Fig. 1. The highest elasticity (lowest Young modulus) are represented in blue, stiffer tissues (higher Young modulus) are shifted towards red.

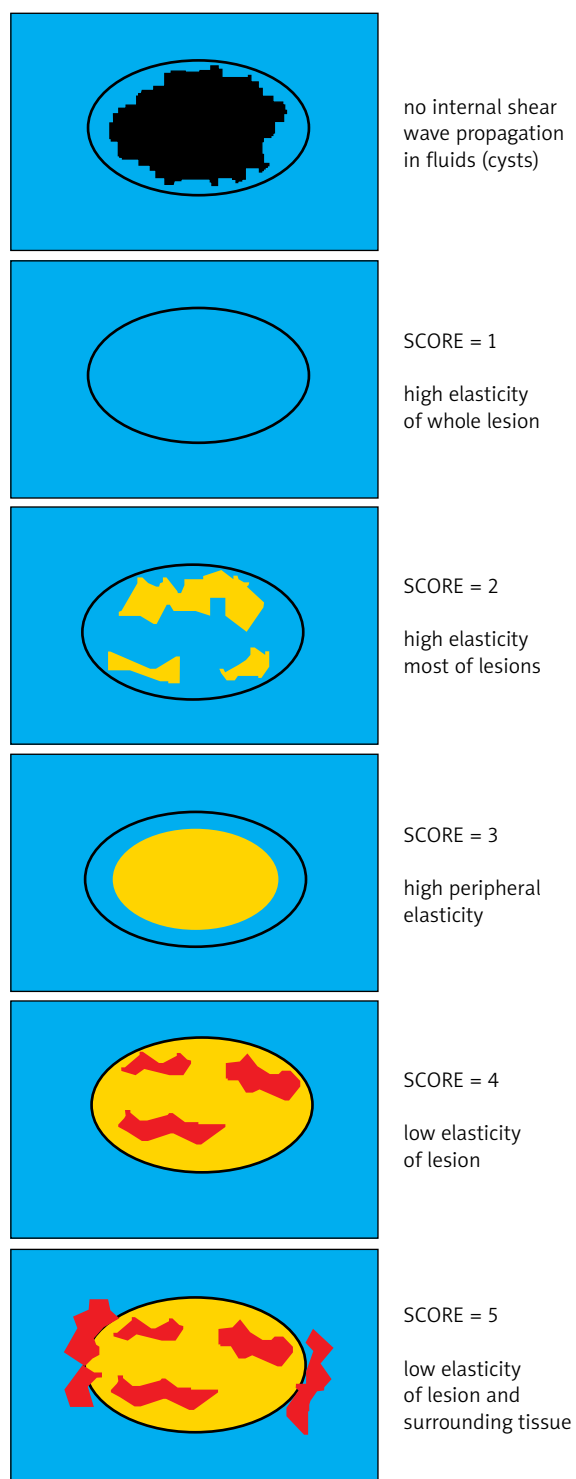


Fig. 1. Elastography scoring system of Itoh et al. [13] modified by author. Additionally in shear wave elastography equipment it is easy to differentiate fluid spaces, where no propagation (gap) is observed [14]. In other elastography systems colours could be inverse: blue – hard tissue, green/red – soft tissue

Colours could vary dependent on machine software, but also cross-change (colour inversion) between different systems is possible in several ultrasound devices. Measurements of relative elasticity were also developed to improve lesion identification.

After years of research with conventional elastography, a new concept has been developed. Research focused on quantitative relations between elasticity of tissues and lesions. The lesion to fat strain ratio and lesion to glandular tissue ratio were introduced [3]. But last year a fully quantitative, commercially available method appeared: supersonic shear wave elastography, that combines two concepts. Instead of using external mechanical compression, the ultrasound probe itself remotely produces mechanical vibration by using acoustic radiation force created by focused ultrasonic beams. The propagation of the shear wave is captured by the ultrasound device simultaneously; thus both the B-mode scan and the elastography colour coded map are available in the same and real time. The displacement induced at the focus generates the shear wave that conveys information connected to local viscoelastic properties. The shear wave speed v is linked to shear modulus μ by the formula:

$$\mu = \rho v^2$$

where ρ is the local tissue density. Young's modulus is described as $E = 3\mu$. Comparing this newer method with conventional elastography, the advantages of quantitative analysis and higher reproducibility seem to be clear [14, 15]. Values over 50 kPa in breast lesions are highly suspicious for malignancy, but further research in more patients is needed [15]. There are still many questions about careful evaluation of peritumoural stiffness seen in elastography. If it represents surrounding DCIS, desmoplastic reaction or infiltration remains an open question. No precise evaluations have been performed in elastography studies [15].

Clinical studies

Among the first clinical evaluations were those by Garra et al. The researched group was not numerous and no sensitivity or specificity of elastography was presented. But from the obtained data these parameters could be calculated and are shown in Table I [9]. An interesting study was performed by Cho et al. in microcalcifications seen on screening mammography. All lesions were not palpable and were verified by vacuum-assisted biopsy or subsequent excision. Among malignant lesions 25 were DCIS and 10 IDC with DCIS; thus the results are interesting regarding early stages of breast cancer. The data shown in the table consist of whole material, but when lesions over 1 cm were separately analysed, the sensitivity of elastography increased to 100% with

specificity of 69% [2]. In their other study with breast tumours, elastography as a single method did not differ from B-mode ultrasound, with the discriminating power AROC (area under receiver operating characteristic curve) = 0.901 and AROC = 0.916 respectively [11]. Also Scaperrotta et al. analysed relatively small lesions up to 2 cm, but the percentage of in situ cancers was small (2.7%). Interestingly, lesions evaluated in BI-RADS (Breast Imaging Reporting and Data System) with a score of 3 lacked good sensitivity (20%) in elastography with still good sensitivity (88%). But the detecting and differentiating power in lesions up to 1 cm were good [10]. Regini also observed better sensitivity and specificity in elastograms of lesions up to 2 cm than bigger tumours [16]. In a study by Satake et al. [17] this phenomenon was not so spectacular, but slightly better accuracy was also noted. In another study the group of patients with pre-invasive malignancies was small (13.5%) [18]. Fleury et al. made a study similar to that mentioned above, but the material was selected from a larger one in post hoc analysis. It is limited to fibroadenomas with some information about cancers, but other benign breast diseases were excluded from the analyses [19].

In a study performed by Thomas et al., a first look at the results obtained is impressive. But only 8% of lesions were in situ and the mean diameter was 2.3 cm [12]. In another study, breast tumours were mostly palpable (70.7%), but no precise data on their diameter are presented. The authors stated that there were no significant differences between palpable and non-palpable tumours. The above cited research should be cautiously evaluated, especially because of the high percentage of bigger lesions. This obviously influences the results by increasing the detecting power. In particular, newer studies do not emphasize early detection power with good results in invasive and greater lesions [20-25].

In many papers, B-mode ultrasound and elastography were analysed separately. Only in a few of them are data from application of these two methods clearly presented [1]. But in some papers existing data enable one to calculate the power of combined methods [13]. When elastography was added to conventional examination, the sensitivity/specificity usually increased to 90-97%. Elastography was especially useful in false negative cases evaluated with a cut-off on the BI-RADS scale of 3-4 [1, 13]. Results from studies published recently with first quantitative analysis of elastography scans are promising [3, 15, 25]. But really high detecting and discriminating power was achieved in studies by Atkhanasiou et al. [14]. The potential application of shear wave elastography relies on its capacity to reject cystic lesions (no wave propagation, Young modulus 0 kPa) regardless of their sometimes complicated B-mode appearance. Taking a new variable comprising BI-RADS categorization and Young modulus of breast lesion, the discriminating power increased to 0.985 with sensitivity and speci-

Tab. I. Analysis of published papers concerning breast lesions elastography in women

Paper/ BIRADS score/Cases	Mammography (M)	B-mode ultrasound (U)	Elastography (E)	Combined methods
Thomas (2006) [8] BIRADS 2-5 <i>Malignant = 132</i> <i>Benign = 168</i>	Sens = 87% Spec = 85%	Sens = 95% Spec = 83%	Sens = 82% Spec = 87%	No data
Garra (1997) [9]* BIRADS? <i>Malignant = 12</i> <i>Benign = 40</i>	Not possible to calculate	Not possible to calculate	Sens = 67% Spec = 97%	Not possible to calculate
Zhi (2007) [1] BIRADS? <i>Malignant = 87</i> <i>Benign = 209</i>	Sens = 72% Spec = 87%	Sens = 71% Spec = 73%	Sens = 70% Spec = 96%	E+U sens = 90% E+U spec = 96%
Cho (2009) [2] BIRADS 4-5 <i>Malignant = 35</i> <i>Benign = 42</i>	No data	No data	Sens = 97% Spec = 62%	No data
Scaperrotta (2008) [10] BIRADS 3-5 <i>Malignant = 110</i> <i>Benign = 183</i>	–	Sens = 95% Spec = 87%	Sens = 80% Spec = 81%	Not possible to calculate
Cho (2008) [11] BIRADS 3-5 <i>Malignant = 17</i> <i>Benign = 83</i>	–	Sens = 82% Spec = 89%	Sens = 82% Spec = 84%	No data
Thomas (2006) [12] BIRADS 3-5 <i>Malignant = 49</i> <i>Benign = 59</i>	–	Sens = 92% Spec = 78%	Sens = 78% Spec = 88%	U and E agreement $\kappa = 0.67$
Itoh (2006) [13] BIRADS 2-5 <i>Malignant = 59</i> <i>Benign = 76</i>	–	Sens = 71% Spec = 91%	Sens = 87% Spec = 90%	E+U sens = 92% E+U spec = 97% (calculated from data)
Tan (2008) [20] BIRADS 2-5 <i>Malignant = 119</i> <i>Benign = 431</i>	–	Sens = 87% Spec = 99%	Sens = 78% Spec = 99%	Not possible to calculate
Sohn (2009) [18] BIRADS? <i>Malignant = 59</i> <i>Benign = 222</i>	–	Sens = 98% Spec = 44%	No data	E+U sens = 89% E+U spec = 50%
Fleury (2009) [19] BIRADS 3-5 <i>Malignant = 44</i> <i>Benign = 115</i>	–	No data	Sens = 87% Spec = 97%	No data
Kumm (2010) [3] BIRADS? <i>Malignant = 87</i> <i>Benign = 223</i>	–	–	Sens = 76% Spec = 81%	E + elasticity ratio ^(a) Sens = 79% Spec = 76%
Evans (2010) [15] BIRADS 2-5 <i>Malignant = 30</i> <i>Benign = 23</i>	–	Sens = 87% Spec = 83%	Sens = 97% Spec = 78%	E – heterogeneity ^(b) Sens = 83% Spec = 96%
Atkhanasiou (2010) [14] <i>Malignant = 20 BIRADS 3-5</i> <i>Benign = 28</i>	–	Sens = 96% Spec = 63% AROC = 0,917	–	E+U ^(c) Sens = 95% Spec = 96% AROC = 0.985
Raza (2010) [16] BIRADS? <i>Malignant = 61</i> <i>Benign = 127</i>	– –	– –	Sens = 93% Spec = 86%	–
Leong (2010) [21] BIRADS 2-5 <i>Malignant = 26</i> <i>Benign = 84</i>	–	Sens = 89% Spec = 43%	Sens = 100% Spec = 74%	E+U Sens = 89% Spec = 79%
Regini (2010) [22] BIRADS 2-5 <i>Malignant = 35</i> <i>Benign = 66</i>	No data	–	Sens = 89% Spec = 93%	–
Wojcinski (2010) [24] BIRADS 3-5 <i>Malignant = 360</i> <i>Benign = 419</i>	Sens = 87% Spec = 83%	Sens = 95% Spec = 76%	Sens = 81% Spec = 90%	–

Tab. I. Analysis of published papers concerning breast lesions elastography in women – continue

Barr (2010) [25] BIRADS 2-5 Malignant = 54 Benign = 197	–	–	Sens = 100% Spec = 95%	–
Satake (2009) [17] BIRADS 4-5 Malignant = 88 Benign = 27	Sens = 69% Spec = 70% ^(d)	–	Sens = 82% Spec = 70%	–

Sens – sensitivity; Spec – specificity; * – sensitivity and specificity not presented in the paper, calculated from presented data; (a) Strain lesion to fat ratio; (b) Elasticity heterogeneity measurement based on SD of elasticity map; (c) Elastography as additional scale shifting ultrasound BI-RADS classification from –1 to +1; (d) Diffusion-weighted magnetic resonance imaging.

city 95% and 96% respectively. Elastography was a BI-RADS modifying factor ranging from –1 to +1. But these are initial studies in not numerous groups, with invasive cancers. No DCIS were included in this study [14].

Integrating elastography examination into routine diagnostics

The presented results from all studies suggest that elastography is a useful diagnostic tool. Results from many studies classify elastography between methods of good sensitivity and specificity. Direct comparison of these studies is not possible because of different methodology, but 1484 malignant and 2822 benign breast lesions analysed in these papers are growing evidence of the usefulness of elastography in clinical practice. Studies vary regarding populations, malignancy rate, tumour size, and BI-RADS classification taken to the trial. It is also not possible to draw definitive conclusions comparing or combining elastography with sonography or mammography. Every study used a different combination of imaging techniques. But elastography seemed to reduce false-positive results from B-mode sonography, which potentially could spare unnecessary biopsies in future. Elastography appeared to give radiologists more confidence in diagnosing benign lesions. Its overall sensitivity was 67-100% with specificity of 62-99%. But still many questions have to be answered, e.g. the differences between quadrants elasticity, elasticity heterogeneity, and hormonal influence [23]. Elasticity heterogeneity has shown up in the newest research presented [4, 15, 23].

Presented papers, especially those published in 2010, indicate that inclusion of elastographic features in the BI-RADS classification system can increase diagnostic accuracy. It is suggested that lesions classified as BI-RADS 0, 1, 2 or 5 should be evaluated solely in conventional ultrasound or mammography. However, for BI-RADS 3 and 4 lesions in ultrasound and eventually mammography the data provide evidence of improved diagnostic performance adding elastography to the scheme. Lesions classified as BI-RADS 3 are usually in fact benign (over 90%) and require observation. Adding elastography makes this assumption more convincing

(near 100%). But if a suspicious elastogram is obtained, the risk for malignancy increases with the probability of 45%. Biopsies should in these cases be performed and we can expect 1 carcinoma per 3 benign lesions [24]. In direct comparison between elastography and MRI Satake et al. also did not find a value of elasticity measurement in BI-RADS score 5 [17].

In summary, elastography has sufficient evidence of clinical application and can be integrated into the BI-RADS classification. The proposed procedures must remain a topic of future discussion and research.

References

- Zhi H, Ou B, Luo BM, et al. Comparison of ultrasound elastography, mammography and sonography in the diagnosis of solid breast lesions. *J Ultrasound Med* 2007; 26: 807-15.
- Cho N, Moon WK, Park JS. Real-time US elastography in the differentiation of suspicious microcalcification on mammography. *Eur Radiol* 2009; 19: 1621-8.
- Kumm TR, Szabunio MM. Elastography for the characterization of breast lesions: initial clinical experience. *Cancer Control* 2010; 17: 156-61.
- Sammani A, Zubovits J, Plewes D. Elastic moduli of normal and pathological human breast tissues: an inversion-technique-based investigation of 169 samples. *Phys Med Biol* 2007; 52: 1565-76.
- Krouskop TA, Wheeler TM, Kallel F, et al. Elastic moduli of breast and prostate tissues under compression. *Ultrason Imaging* 1998; 20: 260-74.
- Sinkus R, Tanter M, Xydeas T, et al. Viscoelastic shear properties of in vivo breast lesions measured by MR elastography. *Magn Res Imag* 2005; 23: 159-65.
- Rzyski P, Skórzewska A, Opala T. Changes in ultrasound shear wave elastography properties of normal breast during menstrual cycle. *Clin Exp Obstet Gynecol* 2011; 38: 137-42.
- Thomas A, Kummel S, Fritzsche F, et al. Real-time sonoelastography performed in addition to B-mode ultrasound and mammography: improved differentiation of breast lesions? *Acad Radiol* 2006; 13: 1496-504.
- Garra BS, Cespedes EI, Ophir J, et al. Elastography of breast lesions: initial clinical results. *Radiology* 1997; 202: 79-86.
- Scaperrotta G, Ferranti C, Costa C, et al. Role of sonoelastography in non-palpable breast lesions. *Eur Radiol* 2008; 18: 2381-9.
- Cho N, Moon WK, Park JS, et al. Nonpalpable breast masses: evaluation by US elastography. *Korean J Radiol* 2008; 9: 111-8.
- Thomas A, Fischer T, Frey H, et al. Real-time elastography – an advanced method of ultrasound: first results in 108 patients with breast lesions. *Ultrasound Obstet Gynecol* 2006; 28: 335-40.
- Itoh A, Ueno E, Tohno E, et al. Breast Disease: Clinical application of US elastography for diagnosis. *Radiology* 2006; 239: 341-50.
- Atkhanasiou A, Tardivon A, Tanter M, et al. Breast lesions: quantitative elastography with supersonic shear imaging – preliminary results. *Radiology* 2010; 256: 297-303.
- Evans A, Wheelahan P, Thomson K, et al. Quantitative shear wave ultrasound elastography: initial experience in solid breast masses. *Breast Cancer Res* 2010; 104: 1-11.

16. Raza S, Odulate A, Ong EM, et al. Using real-time tissue elastography for breast lesion evaluation: our initial experience. *J Ultrasound Med* 2010; 29: 551-63.
17. Satake H, Nishio A, Ikeda M, et al. Predictive value for malignancy of suspicious breast masses of BI-RADS categories 4 and 5 using ultrasound elastography and MR diffusion-weighted imaging. *AJR* 2009; 196: 202-9.
18. Sohn YM, Kim MJ, Kim EK, et al. Sonographic elastography combined with conventional sonography – how much is it helpful for diagnostic performance? *J Ultrasound Med* 2009; 28: 413-20.
19. Fleury EFC, Rinaldi JF, Piato S, et al. Appearance of breast masses on sonoelastography with special focus on the diagnosis of fibroadenomas. *Eur Radiol* 2009; 19: 1337-46.
20. Tan SM, The HS, Kent Mancer JF, Poh WT. Improving B mode ultrasound evaluation of breast lesions with real-time ultrasound elastography – a clinical approach. *Breast* 2008; 17: 252-7.
21. Leong LC, Sim LS, Lee YS, et al. A prospective study to compare the diagnostic performance of breast elastography versus conventional breast ultrasound. *Clin Radiol* 2010; 11: 887-94.
22. Regini E, Bagnera S, Tota D, et al. Role of sonoelastography in characterizing breast nodules. Preliminary experience with 120 lesions. *Radiol Med* 2010; 115: 551-62.
23. Rzymiski P, Skórzewska A, Skibińska-Zielińska M, Opala T. Factors influencing breast elasticity measured by the ultrasound Shear Wave elastography – preliminary results. *Arch Med Sci* 2011; 1: 127-33.
24. Wojcinski S, Farrokh A, Weber S, et al. Multicenter study of ultrasound real-time tissue elastography in 779 cases for the assessment of breast lesions: improved diagnostic performance by combining the BI-RADS-US classification system with sonoelastography. *Ultraschall Med* 2010; 31: 484-91.
25. Barr RG. Real-time ultrasound elasticity of the breast: initial clinical results. *Ultrasound Q* 2010; 26: 61-6.