

## Simultaneous myocardial revascularization and aortic valve decalcification in patients operated on for coronary artery disease



Jednoczasowa rewaskularyzacja mięśnia sercowego i dekalcyfikacja zastawki aortalnej u pacjentów operowanych z powodu choroby wieńcowej

Stanisław Ostrowski<sup>1</sup>, Anna Marcinkiewicz<sup>2</sup>, Anna Kośmider<sup>3</sup>, Witold Pawłowski<sup>1</sup>, Radosław Zwoliński<sup>1</sup>, Ryszard Jaszewski<sup>1</sup>

<sup>1</sup>Cardiac Surgery Clinic, Chair of Cardiology and Cardiac Surgery, Medical University of Lodz, Poland

<sup>2</sup>Medical student of the 6<sup>th</sup> year, Medical University of Lodz, Poland

<sup>3</sup>Military Teaching Hospital – Veterans Central Hospital, Medical University of Lodz, Poland

Kardiochirurgia i Torakochirurgia Polska 2012; 2: 252–256

### Abstract

**Introduction:** Aortic stenosis is the most common acquired cardiac defect. Its prevalence increases with age and among patients above 65 years it occurs in 2-7%. Surgical prosthetic or bioprosthetic valve implantation remains the treatment of choice. Complexity of the surgery is one of the principal operative risk factors.

**Aim of the study:** The aim of this study was to present the results of surgical treatment of patients operated on for coronary artery disease and aortic stenosis, in whom the native valve was preserved, thanks to its debridement.

**Material and methods:** Three patients, aged 69-74, were admitted to the Cardiac Surgery Clinic in Lodz in order to conduct surgical myocardial revascularization. Preoperative echocardiography confirmed co-existence of moderate aortic stenosis (transvalvular maximal gradient 51-59 mm Hg) in each case and good ejection fraction (EF) ranging from 49 to 74%. During surgery, there were firstly aorto-coronary anastomoses implanted. Intraoperative assessment allowed preservation of the aortic valve and decalcification was performed in two cases with additional commissurotomy in one case. The postoperative echocardiography revealed a good effect of the operation (maximal gradient 25-40 mm Hg), which was confirmed to be maintained in the follow-up. In one patient the 5-year follow-up disclosed quite an advanced organic defect without clinical aggravation, which has remained unchanged for the last two years.

**Conclusions:** In asymptomatic or fairly symptomatic patients with moderate aortic stenosis eligible for implantation of aor-

### Streszczenie

**Wstęp:** Zwężenie zastawki aortalnej jest najczęstszą nabytą wadą serca. Jej częstość wzrasta z wiekiem i powyżej 65. roku życia wynosi 2-7%. Implantacja sztucznej zastawki lub bioprotezy pozostaje podstawową metodą leczenia. Złożoność zabiegu jest jednym z głównym czynników ryzyka operacyjnego.

**Cel pracy:** Celem pracy było przedstawienie wyników chirurgicznego leczenia pacjentów z chorobą niedokrwinną serca i stenozą aortalną, u których zachowano zastawkę natywną, przeprowadzając dekalcyfikację.

**Materiał i metody:** Trzech pacjentów w wieku 69–74 lat zostało przyjętych do Kliniki Kardiochirurgii w Łodzi w celu operacyjnej rewaskularyzacji mięśnia sercowego. Przedoperacyjna echokardiografia potwierdziła współistnienie umiarkowanej stenozы aortalnej (maksymalny gradient przez zastawkowy 51–59 mm Hg) i dobrą frakcję wyrzutową w granicach 49–74% u wszystkich pacjentów. W czasie operacji w pierwszej kolejności wykonano zespolenia wieńcowo-aortalne. Po śródoperacyjnej ocenie postanowiono zachować natywną zastawkę aortalną i wykonano dekalcyfikację, a w jednym przypadku dodatkowo komisurotomię. Pooperacyjna echokardiografia wykazała dobry efekt zabiegu (gradient maksymalny 25–40 mm Hg), który utrzymał się w okresie obserwacji. W przypadku jednej pacjentki 5-letni *follow-up* ujawnił istotną wadę organiczną zastawki bez cech progresji od dwóch lat i klinicznego pogorszenia stanu chorej.

**Wnioski:** U bezobjawowych lub skąpoobjawowych pacjentów z umiarkowaną stenozą aortalną, kwalifikowanych do wszczęcia zespolenia wieńcowo-aortalnych, dekalcyfikacja może

**Address for correspondence:** Stanisław Ostrowski, MD, PhD, 1Cardiac Surgery Clinic, Chair of Cardiology and Cardiac Surgery, Medical University of Lodz, Poland, tel./fax: +48 42 633 15 58, Email: stanislaw.ostrowski@umed.lodz.pl

to-coronary anastomoses, decalcification may be more favorable management. Numerous operative risk factors such as co-morbidities and advanced age should suggest this choice of treatment.

**Key words:** aortic stenosis, decalcification, ischemic heart disease.

## Introduction

Aortic stenosis is the most common acquired cardiac defect, comprising 43% (calcific aortic stenosis) of valvular heart diseases [1, 2]. Among people above 65 years of age it is estimated to reach 2-7% [3]. At the age of 50-60 years it most often develops on the basis of atheromatous and calcifying alterations. Its prevalence increases with age – 2% in the population over 65 years and 2.9% in the population over 75 years of age [1]. Bicuspid aortic valve promotes its occurrence and then the defect develops at a younger age (the 4th-5th decade of life). Other predisposing factors include high low-density lipoprotein (LDL) level, hyperlipoproteinemia, arterial hypertension, diabetes mellitus, cigarette smoking and male gender. It inevitably leads to a significant defect of the aortic valve, requiring implantation of an artificial valve or bioprosthesis [4]. The operative risk is 1-9% [1]. It increases in the case of performing simultaneously coronary artery bypass grafting, implantation of an artificial mitral valve or aortic aneurysm management. Advanced age, comorbidities, female gender, urgent surgery, pulmonary hypertension and impaired left ventricular function are factors of increased perioperative mortality [4].

The aim of this study was to present the results of surgical treatment of patients operated on for coronary artery disease and aortic stenosis, in whom the native valve was preserved, thanks to its mechanical debridement.

## Material and methods

### First patient

A 74-year-old patient with type 2 diabetes (Metformax and insulin Novo Mix 30), arterial hypertension, chronic obstructive pulmonary disease (COPD) and unstable coronary artery disease was admitted to the Cardiac Surgery Clinic in January 2009 with a diagnosis of co-existing combined mitro-aortic defect. Coronarography revealed 75% stenosis in the middle segment of the circumflex branch (Cx) and 95% stenosis in the 2nd and 3rd segment of the right coronary artery (RCA). The patient was in NYHA functional class III. As part of the standard presurgical preparation, carotid artery ultrasound (negative) and transthoracic echocardiography reassessment (TTE) were performed. In the TTE hypokinesis of the peribasal and middle segment of the infero-posterior wall with decreased EF of 61% was found. The aortic valve was organically modified with atheromatous plaques on the annulus and calcifications of the leaflets (tricuspid, slight regurgitation). The measured maximal transvalvular gradient was 51 mm Hg and the mean valve area index was 0.9 cm<sup>2</sup>/m<sup>2</sup>. There were co-existing mitral

być korzystniejszym postępowaniem. Liczne czynniki ryzyka, jak choroby współtowarzyszące i zaawansowany wiek, sugerują takie postępowanie.

**Słowa kluczowe:** stenoza aortalna, dekalcyfikacja, choroba niedokrwienna serca.

valve alterations (fibrosis with calcifications on the leaflets and in the area of the posterior commissure), causing moderate mitral regurgitation. The left atrium was enlarged, 5.8 x 4.5 cm. Hypertrophy of the left ventricle with impaired relaxation was also found.

The procedure was performed with a median sternotomy. After performing horizontal incision of the aorta, 500 ml of a cold crystalloid cardioplegic solution was administered into the left coronary ostium. After obtaining cardioprotection, a venous graft was implanted to the RCA and an additional 100 ml of cardioplegic solution was administered directly into the anastomosis. Again 200 ml of the cardioplegic solution was administered into the left coronary ostium and a venous graft was implanted to the first marginal branch (Mg I). After the intraoperative assessment it was decided to perform decalcification of the aortic valve leaflets and annulus. After the mechanical debridement, the leaflets coaptation was evaluated as proper. The aorta was closed with a standard two-layer suture. The aortic cross-clamping time was 46 min. The proximal aorto-coronary anastomoses were performed during the tangential clamp. The extracorporeal circulation (ECC) time was 85 min. Intraoperatively, ephedrine and adrenaline infusion was applied. On the operative day in the intensive care unit (ICU) the pressure was further stabilized with adrenaline infusion (on the 1st postoperative day adrenaline was ceased, RR 130/50 mm Hg). The patient was extubated in the evening on the operative day. The further ICU stay was complicated by an episode of atrial fibrillation, which resolved after infusion of magnesium sulfate and Cordarone. Features of persistent inflammation in the bronchial tree were also present. The total stay in the ICU lasted 5 days, and hospitalization time was 21 days.

Postoperative echocardiography showed a good effect of the surgery and reduction of the maximal gradient to 30-32 mm Hg.

In a 2-year ambulatory follow-up the patient is in a good clinical condition and the conservative treatment is being continued. Based on the control TTE there was a good decalcification effect and satisfactory function of the preserved native valve. The maximal transvalvular gradient is currently 29 mm Hg and the ejection fraction is 58-60%.

### Second patient

A 74-year-old patient with ischemic heart disease, hypertension, mixed dyslipidemia, myocarditis in the past history (10 years earlier) and mixed defect of the aortic valve was admitted to the Cardiac Surgery Clinic in Lodz in 2006 in order to perform surgical myocardial revascularization.

10 days earlier the patient had an acute coronary syndrome (ACS). The coronarography performed at that time disclosed 95% stenosis of the left main stem (LMS), 95% proximal stenosis of the second marginal branch (Mg II), with an aneurysmal widening, followed by 75% stenosis of the vessel. The right coronary artery (RCA) was proximally closed and filling from the collateral circulation. In the echocardiography there were visualized calcifications of the aortic leaflet edges, presenting as a mixed aortic defect in the form of moderate stenosis with slight regurgitation. The maximal transvalvular gradient was 59 mm Hg and the area was 0.65 cm<sup>2</sup>/m<sup>2</sup>. Left ventricular systolic function was good with EF 74%. After consultation the patient was qualified for cardiac surgery. On admission to the Cardiac Surgery Clinic the patient was in NYHA functional class II/III, with a long-lasting history of pain in the chest and significant deterioration in exertion tolerance and pain intensity for 10 days. Originally, simultaneous implantation of the aortic bioprosthetic valve and coronary artery bypass grafting (CABG) was planned.

The chest was opened through a median sternotomy. The internal mammary artery was harvested. After aortic cross-clamp, horizontal incision of its wall was done and cold crystalloid cardioplegia administered directly into the coronary artery ostia (the total amount during the procedure was 850 ml). An arterial anastomosis to the left anterior descending branch (LAD) and venous anastomoses to the RCA and Mg I were implanted. After the intraoperative assessment of the aortic valve it was decided to preserve the native valve. Due to the good condition of the valve leaflets, just the calcifications were removed from the leaflets and annulus (as extensively as possible). The aorta was closed with a double-layer suture. After tangential aortic clamp anastomoses with aorta were performed. The ECC time and aortic cross-clamping time were respectively 81 min and 43 min. The postoperative period was uncomplicated. The patient was discharged from the ICU on the 3rd day. The total hospitalization time was 15 days.

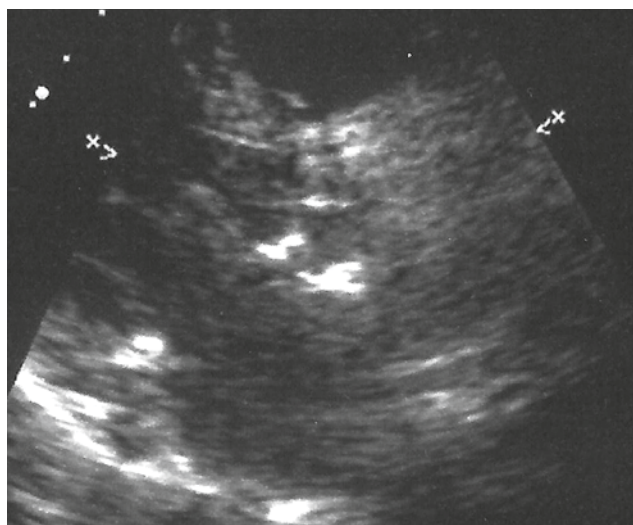


Fig. 1. Postoperative echocardiogram – good decalcification effect (left parasternal short axis view at the aortic valve level)

Postoperative echocardiography showed a good early effect of the surgery. The aortic transvalvular gradient was 40-44 mm Hg. It displayed a good EF (60%). No segmental disturbances of heart contractility were observed.

In the 5-year follow-up a good long-term effect of the surgical myocardial revascularization was reported. During this period the patient also had a myocardial infarction without ST elevation (NSTEMI in 2009) and a stent implanted into the circumflex branch (Cx). In the subsequently performed echocardiographies there was observed a small gradual gradient increase, which was not accompanied by progression of symptoms. However, in the last two years an increase in the gradient was no longer observed and it remained within the range of 65-70 mm Hg. In the last echocardiography there was found quite an advanced organic defect of the aortic valve with a maximal gradient of 70 mm Hg.

The patient was considered for transcatheter aortic valve implantation (TAVI). However, due to good biological condition, lack of symptomatic stenosis and EuroSCORE of 4.42%, it has turned out that the patient does not meet the inclusion criteria for the TAVI procedure.

### Third patient

A 69-year-old patient with hypertension and unstable angina (ACS during the same hospitalization) was admitted to the Cardiosurgical Clinic in order to undergo surgical myocardial revascularization and aortic valve repair with decalcification.

Preoperative TTE revealed quite large calcifications of the leaflets, fusion of right and left coronary leaflets, and smaller calcifications of the aortic annulus. The maximal transvalvular gradient was 56 mm Hg and the valve area was 0.85 cm<sup>2</sup>/m<sup>2</sup>. Slight segmental disturbances of the contractility within the anterior cardiac wall and peribasilar segments of the postero-inferior wall with a good EF of 49% were observed.

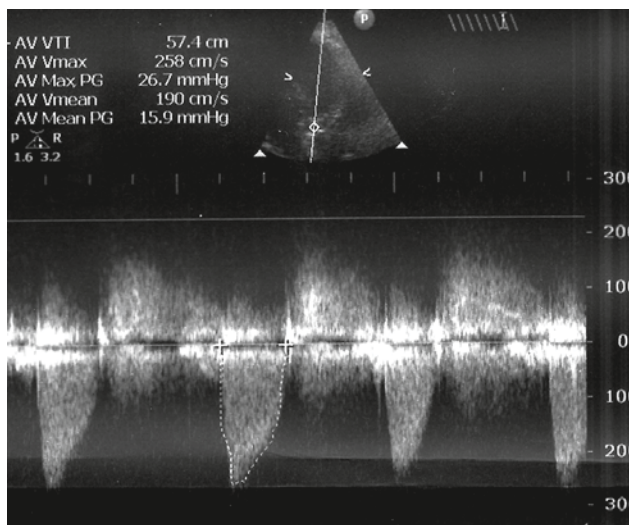


Fig. 2. Transthoracic echocardiogram, continuous wave Doppler – gradient through the decalcified aortic valve, below 30 mm Hg

During the procedure arterial anastomosis (LITA to LAD) and two venous anastomoses with Cx and RCA were performed. The total amount of administered cardioplegic solution was 1100 ml. In the next step the aortic valve repair was carried out. Calcifications were removed and the fused right and left coronary leaflets were reconnected. Intraoperative TEE examination revealed grade I/II aortic insufficiency with a maximal gradient of 40 mm Hg. The total perfusion time was 82 min, and aortic cross-clamping time was 49 min. After the surgery, initially high blood pressure and sinus tachycardia were observed. Ebrantil, Betaloc and adrenaline in small doses were introduced, resulting in pressure and heart rhythm stabilization. The patient was extubated in the evening. On the 2nd postoperative day he was discharged from the ICU. TTE performed in the postoperative period revealed good revascularization and repair effect, showing slight aortic regurgitation with a maximal gradient of 25 mm Hg. Slightly worse global contractility with the EF of 51% was recorded. The hospitalization time was 17 days.

## Discussion

Implantation of an artificial aortic valve is associated with operative risk, primarily development of infective endocarditis, thrombus formation or more often pannus, and in 2.5-4% death [5]. In elderly patients with multiple comorbidities the risk of complications is high, so preservation of the native valve would be reasonable, especially in the situation where additional procedures are essential, for example simultaneous coronaro-aortic anastomoses.

Touati GD et al. [6] reported a good effect of aortic valve decalcification in patients with moderate aortic stenosis, who were operated on due to ischemic heart disease. As the criteria for decalcification the authors particularly listed degenerative aortic defect in the presence of tricuspid valve with an area of 0.55-0.9 cm<sup>2</sup>/m<sup>2</sup>.

Among our patients, in each case the aortic valve was tricuspid. The intraoperative presentation suggested typical stenosis of atheromatous and calcifying etiology. Good condition of the valve leaflets, the advanced age of the patients, and concomitant coronary heart disease as the main indications for the surgery were the principal reasons for which it was decided to limit the treatment to revascularization and valve debridement. It significantly reduced the time of aortic cross-clamping and myocardial ischemia time.

On the other hand, other authors put emphasis on the fact that the decalcification causes exposure of the fibrous tissue and rapid reaccumulation of calcium deposits. In this area endothelialization is impaired [7]. The examples of our patients show that in some cases favorable results after decalcification can be obtained. In the first patient the gradient remains approximately 30 mm Hg. Despite the initial gradual gradient increase, the second patient continues to be asymptomatic. In the case of co-existence of advanced coronary heart disease it is difficult to determine the degree of aortic stenosis clinical manifestation. It seems that in the case of our patients clinical symptoms

were dependent on the coronary heart disease. The ambulatory observation revealed relief of stenocardial symptoms and improved exertion tolerance.

Concerning the decalcification of the native valve, methods of physical and chemical decalcification should be mentioned. Results of the study by Kose N et al. [8] demonstrated in vitro efficacy of citric acid as the agent chelating calcium, which can significantly reduce the amount of calcium deposits without damaging the tissue valve. Decalcification by ultrasonic energy has not been widely recommended due to the inability to precisely control its extent and the possibility of damaging the surrounding heart structures and secondary stimulation of the healing process in tissues and in consequence restenosis. On the other hand, Stéphane Aubert et al. [9] suggested that the use of a dissector equipped with a microsonotrode allows one to conduct decalcification precisely and avoid these adverse effects.

Almost 1/3 of patients over 75 years of age due to poor clinical status and numerous concomitant diseases are excluded from surgical implantation of an artificial aortic valve (mainly bioprosthesis) [5, 10]. Those are the patients qualified for transcatheter aortic valve implantation (TAVI). In the era of TAVI development it should be expected that patients after decalcification in the future may become patients who will benefit from this method of treatment. Tunnel symptomatic aortic stenosis (with surface area 0.8-1.0 cm<sup>2</sup> and aortic annulus diameter 18-27 mm) in elderly patients with many comorbidities (EuroSCORE > 20%) is the primary indication for the TAVI procedure. Bicuspid valve or ejection fraction below 20%, significant coronary atherosclerosis, myocardial infarction within less than a month, subvalvular hypertrophy or large asymmetric calcifications are the principal disqualifying criteria [1, 10, 11].

## Conclusions

1. As the above demonstrates, in asymptomatic or mildly symptomatic patients with moderate aortic stenosis eligible for implantation of aorto-coronary anastomoses, decalcification may be more favorable management.
2. The final decision should be individualized for each patient and made after intraoperative assessment. Based on the authors' experience, it seems that in a patient with the need of simultaneous CABG and aortic valve surgery, numerous comorbidities and advanced age may suggest the choice of a less burdensome procedure.
3. Although this method is not appropriate for the definitive treatment of aortic stenosis, it can be valuable for appropriately selected patients.

## References

1. Elżbieta K. Włodarska, Witold Rużyłło. Przeszkorna implantacja zastawki aortalnej. *Post Kardiol Interw* 2008; 4: 111-115.
2. Grupa Robocza Europejskiego Towarzystwa Kardiologicznego (ESC) ds. postępowania w zastawkowych wadach serca. Wytyczne dotyczące postępowania w zastawkowych wadach serca. *Kardiol Pol* 2007; 65: 5.

3. American College of Cardiology/American Heart Association Task Force on Practice Guidelines; Society of Cardiovascular Anesthesiologists; Society for Cardiovascular Angiography and Interventions; Society of Thoracic Surgeons, Bonow RO, Carabello BA, Kanu C, de Leon AC Jr, Faxon DP, Freed MD, Gaasch WH, Lytle BW, Nishimura RA, O’Gara PT, O’Rourke RA, Otto CM, Shah PM, Shanewise JS, Smith SC Jr, Jacobs AK, Adams CD, Anderson JL, Antman EM, Faxon DP, Fuster V, Halperin JL, Hiratzka LF, Hunt SA, Lytle BW, Nishimura R, Page RL, Riegel B. ACC/AHA 2006 guidelines for the management of patients with valvular heart disease: a report of the American College of Cardiology/American Heart Association Task Force on Practice Guidelines (writing committee to revise the 1998 Guidelines for the Management of Patients With Valvular Heart Disease): developed in collaboration with the Society of Cardiovascular Anesthesiologists: endorsed by the Society for Cardiovascular Angiography and Interventions and the Society of Thoracic Surgeons. *Circulation* 2006; 114: e84-231.
4. Marcin Fijałkowski. Ocena zmian w przebudowie serca po wymianie zastawki aortalnej u pacjentów z izolowaną stenozą aortalną za pomocą badania echokardiograficznego oraz ultradźwiękowej charakterystyki tkanek z uwzględnieniem polimorfizmu genów układu renina-angiotensyna-aldosteron. Praca na stopień doktora nauk medycznych. Promotor prof. dr hab. Jan Rogowski. Klinika Kardiologii Akademii Medycznej w Gdańsku, Gdańsk 2007.
5. Chrysohoou C, Tsiachris D, Stefanadis C. Aortic stenosis in the elderly: challenges in diagnosis and therapy. *Maturitas* 2011; 70: 349-353.
6. Touati GD, Carmi D, Trojette F, Bidaud M, Popesco D, Ben Amar A, Poulain H. Management of patients with asymptomatic moderate aortic stenosis undergoing coronary artery bypass grafting. *J Heart Valve Dis* 2002; 11: 210-216.
7. Dahm M, Dohmen G, Groh E, Krummenauer F, Hafner G, Mayer E, Hake U, Oelert H. Decalcification of the aortic valve does not prevent early recalcification. *J Heart Valve Dis* 2000; 9: 21-26.
8. Köse N, Aytacıoğlu BN, Yılmaz N, Döndaş HA, Tamer L, Coşkun B, Vezir O, Sucu N, Dikmengil M. Citric acid as a decalcifying agent for the excised calcified human heart valves. *Anadolu Kardiyol Derg* 2008; 8: 94-98.
9. Aubert S, Voiglio E, Chalabreysse L, Farhat F, Jegaden O. A new ultrasonic process for a renewal of aortic valve decalcification. *Cardiovascular Ultrasound* 2006; 4: 2.
10. Spaccarotella C, Mongiardo A, Indolfi C. Pathophysiology of aortic stenosis and approach to treatment with percutaneous valve implantation. *Circ J* 2010; 75: 11-19.
11. Zembala M, Wilczek K, Przybylski R, Chodór P, Nadziakiewicz P, Krasoń M, Sadowski J, Dudek D, Kapelak B, Forysz D, Witkowski A, Demkow M, Chmielak Z, Kuśmierski K, Juraszyński Z, Bochenek A, Cisowski M, Trusz-Gluza M, Buszman P, Woś S, Kalarus Z, Poloński L, Gąsior M, Opolski G, Rużyło W. FORUM EKSPERTÓW. Raport POL-TAVI FIRST z zastosowania przezcewnikowej implantacji zastawki aortalnej typu Edwards-Sapien u pierwszych w Polsce 19 chorych z grupy bardzo dużego ryzyka, z ciężką stenozą aortalną i chorobami obciążającymi rokowanie. *Kardiochir Torako-chir Pol* 2009; 6: 219-223.