

Right atrial thrombus associated with subclavian catheter developed due to total parenteral nutrition application



Hanife Karakaya Kabukcu¹, Nursel Sahin¹, Ibrahim Basarici², Ozan Erbasan³

¹Department of Anesthesiology and Reanimation, Akdeniz University Medical Faculty, Antalya, Turkey

²Department of Cardiology, Akdeniz University Medical Faculty, Antalya, Turkey

³Department of Heart Surgery, Akdeniz University Medical Faculty, Antalya, Turkey

Kardiologia i Torakochirurgia Polska 2016; 13 (1): 64-67

Abstract

Central venous catheterization as a frequent routine clinical procedure may have significant complications. Mechanical complications may occur during catheter placement, whereas thromboembolic and infectious complications can be seen during follow-up. Total parenteral nutrition (TPN) associated central venous catheterizations may result in early mechanical complications and thrombotic and infectious complications in the long term.

This paper describes a patient diagnosed as mitochondrial neurogastrointestinal encephalomyopathy requiring long-term central venous catheterization for TPN implementation, who had an infected thrombus on the catheter tip resected by cardiac surgery.

Key words: total parenteral nutrition, thrombus, catheter, mitochondrial neurogastrointestinal encephalomyopathy.

Introduction

Central venous catheters (CVC) are widely used in clinical practice for total parenteral nutrition along with other functions, such as central venous pressure monitoring, fluid and blood transfusion, medication and hemodialysis. Infectious, mechanic and thrombotic complications can be seen related to the catheter. Central venous catheter thrombosis is one of the most serious, life-threatening, and costly complications [1].

Mitochondrial neurogastrointestinal encephalopathy (MNGIE) is a rare autosomal recessive multisystem genetic disease related to the mutation of the thymidine phosphorylase gene. Clinical status is characterized by severe gastrointestinal dysmotility and includes cachexia, ptosis, external ophthalmoplegia, peripheral neuropathy and leu-

Streszczenie

Włknięcie centralne jako częsty, rutynowy zabieg kliniczny może się wiązać z istotnymi powikłaniami. Podczas wkładania cewnika może dojść do powikłań mechanicznych, a w okresie obserwacyjnym mogą wystąpić powikłania zakrzepowo-zatorowe lub infekcyjne. Włknięcie centralne zakładane w celu zapewnienia całkowitego żywienia pozajelitowego może się wiązać z wczesnymi powikłaniami mechanicznymi oraz odległymi powikłaniami zakrzepowymi i infekcyjnymi.

W pracy przedstawiono przypadek pacjenta z mitochondrialną encefalomiopatią dotyczącą układu nerwowego, żołądka i jelit wymagającą włknięcia centralnego, aby zapewnić całkowite żywienie pozajelitowe. Pacjent przeszedł operację chirurgiczną w celu usunięcia zainfekowanej skrzepliny znajdującej się na końcu cewnika.

Słowa kluczowe: całkowite żywienie pozajelitowe, zakrzep, cewnik, mitochondrialna encefalomiopatia układu nerwowego żołądka i jelit.

koencefalopathy. Mitochondrial neurogastrointestinal encephalopathy should be kept in mind for all patients presenting with both digestive and nervous system involvement, even though it lacks a classic phenotype [2, 3].

In this case report, we present a patient with a diagnosis of CVC related thrombus who required open-heart surgery. The patient was diagnosed with rarely seen MNGIE and could not tolerate oral nutrition because of the operation. Therefore, total parenteral nutrition (TPN) was required.

Case report

A twenty-one-year-old male patient (40 kg and 190 cm) was diagnosed with MNGIE in 2009 after being evaluated in the neurology clinic with energy loss, foot-drop, difficulty swallowing, and weight loss. In 2011, TPN was initiated

Address for correspondence: Dr. Hanife Karakaya Kabukcu, Department of Anesthesiology and Reanimation, Akdeniz University Medical Faculty, Dumlupınar Campus 07070 Antalya, Turkey, phone: +90242 2496235, +905337319555, fax: +90242 2278836, e-mail: hanifekabukcu@akdeniz.edu.tr

through central venous catheterization (CVC) because he had undergone duodenojejunostomy operation due to superior mesenteric artery (SMA) syndrome which is a rare condition, results in compression of the third portion of the duodenum by a narrow-angled SMA against the aorta and could not tolerate enteral nutrition postoperatively. Central venous catheterization was changed 4 times due to thrombosis or infection, and the last catheterization was implemented on 19 November 2012. The catheter was inserted in our hospital radiology intervention room under sterile conditions by an interventional radiology team. The catheter was not heparin coated, 14.5 French diameter and 28 cm long, extending from the left pectoral area to the right atrium. The composition of the parenteral solution was lipid 20%, aminoacides 10% and glucose 40%, 1800 kcal/day and 1500 cc/day were used.

However, the patient was admitted to our hospital again one month later with fever and palpitation complaints. Upon physical examination, his body temperature was 38.5°, blood pressure was 120/77 mmHg, pulse was 157 beats/min, and sedimentation and CRP values were elevated. Because of the growth of methicillin resistant *Staphylococcus aureus* (MRSA) in the patient's blood cultures obtained from the catheter lumen and simultaneously from a peripheral vein, his fever was linked to catheter-related infection, and it was decided to remove the catheter. In the echocardiography performed before the removal of the catheter, the view of the catheter inside the right atrium (RA) and 35 x 15 mm sized echogenicity at its end which is protruded to the right ventricle during diastole and evaluated as a mobile thrombus was visualized. After 6 days of heparin and antibiotic treatment, no difference was detected in the size of the thrombus in echocardiography. Our patient's prothrombin time (12.9 second), international normalized ratio INR (1.1) and platelet count (380.000/mm³) were evaluated preoperatively, all these values were within normal limits.

The patient was subsequently taken to open heart surgery and was monitored by ECG, SpO₂ and invasive arterial catheterization. Systemic arterial pressure was recorded as 120/80 mmHg, heart rate at 130/min, and SpO₂ at 97%. Upon induction of anesthesia, intubation was performed with 0.1 mg/kg midazolam, 3 mg/kg thiopental, 4 µg/kg fentanyl and 1 mg/kg rocuronium. Central venous catheterization was implemented to the right femoral vein following intubation. Extracorporeal circulation was started in the patient by implementation of cannula to the ascending aorta and vena cava inferior. The thrombus, seen at the catheter ending inside the right atrium, was removed by cutting (Fig. 1, 2 and 3). The patient's hemodynamic and neurologic signs were stable during the operation. Extracorporeal circulation was 40 minutes, the whole operation was 150 minutes. At the beginning of the operation our patient's hemoglobin value was 10.9 g/dl. During the operation this value decreased to 7.1 g/dl, therefore blood transfusion was performed and 1 U (red blood cell) RBC and 2 U fresh frozen plasma (FFP) were given during pumping. The patient was

moved to the intensive care unit, extubated 5 hours after the operation, and transported to the Cardiovascular Surgery Department on the 3rd day. A catheter culture that was sent during the operation was sterile, and the pathology report was consistent with infected thrombus. The patient refused the insertion of a permanent catheter again and was discharged with the recommendation of the gastroenter-

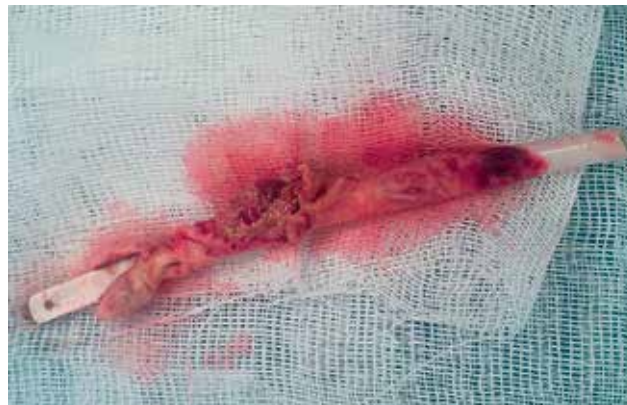

Fig. 1. Fibrous sheath wrapping the distal part of the central venous catheter

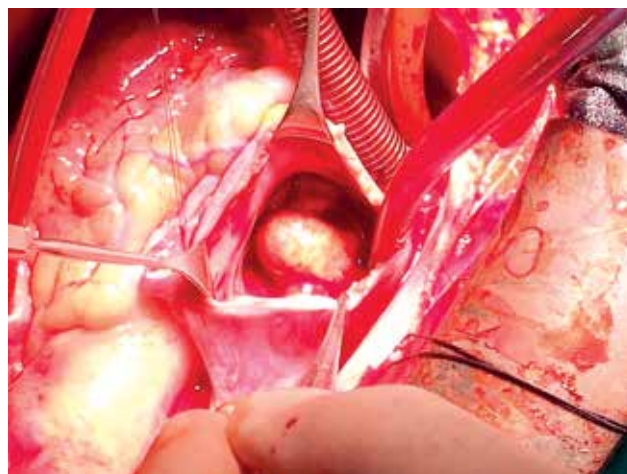


Fig. 2. Thrombotic mass attached the distal tip of catheter in the right atrium

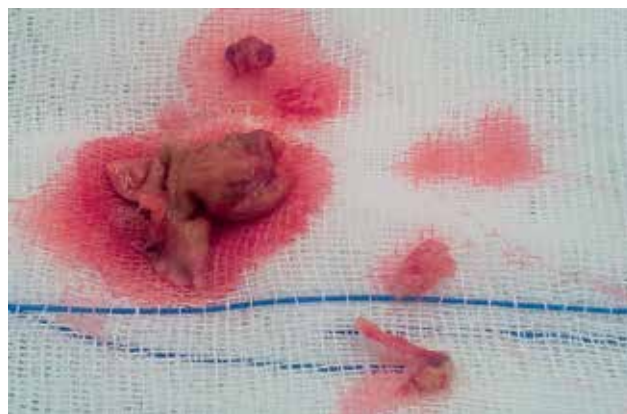

Fig. 3. Mass was removed from distal catheter ending

ology clinic for enteral nutrition and supportive peripheral nutrition upon regression of sedimentation and CRP values.

Discussion

Catheter thrombosis is one of the most significant complications related to central venous catheterization. Venous thrombosis may deteriorate the venous return and may lead to pulmonary thromboembolism [4]. One of the most common late complications following central venous catheterization is the development of infection in blood circulation; bacteremia and fungemia are seen in about 5% of patients [5, 6]. In our patient, both thrombus and infection developed together, and the infected thrombus was treated only by removal, surgically.

Catheter-related infections can be classified in 3 groups: 1) colonization of the catheter; 2) blood circulation infections related with catheter and 3) infections of the catheter insertion site. Generally, in the presence of a clinical finding of catheter-related infections, removal of the catheter, taking a culture from its end, and antibiotic treatment is recommended. Catheter removal has the potential to cause pulmonary embolism when the thrombus is present at the end of the catheter [7]. In our case, if catheter removal had been performed, there would have been a risk of pulmonary septic embolism. In order to prevent this risk, the infected thrombus was removed by open heart surgery, visualizing it from the right atrium without allowing it to decompose or embolize.

Catheter-related thrombosis is one of the chief complications of central venous catheterization and total parenteral nutrition. Its clinical importance is not fully understood. In the development of catheter-related thrombosis, underlying disease, the tendency of the patient for thrombosis, the characteristics of fluids in the catheter, and the place and time of the vessel the catheter is inserted into all play a role. Thrombosis develops less often when the catheter is inserted into the subclavian vein. It is known that lipid emulsions, used for parenteral nutrition, predispose a patient to catheter-related thrombosis. Overly acidic or alkaline pH values of the fluids increase the tendency for thrombosis [8-10]. We suggest that the use of lipid emulsions for parenteral nutrition played a role in the development of thrombosis in our patient.

Catheter-related thrombosis leads to partial or total occlusion, and in total occlusion, supplying liquid or taking blood from the catheter would not be possible. The thrombus that leads up to venous occlusion may cause pain, swelling and apparent collateral veins. There were no mechanical obstruction symptoms detected in our patient. In literature, most catheter thrombosis cases are reported as asymptomatic [7, 11-13]. The thrombus in our case was characterized by advancing from the catheter tip into the right atrium; however, it was not blocking blood flow in the tricuspid valve. Obstruction symptoms did not develop, since it did not block the blood flow from the superior vena cava. For this reason, we think that the thrombus remained asymptomatic until it was infected. In an autopsy study, fibrous sheath wrapping the tip of long-term central venous catheters were report-

ed [14]. This fibrin sheath is not reported to affect catheter functions but may produce partial obstruction. These fibrin sheaths are not reported to create clinical signs [15].

It could be suggested in our case that the fibrin sheath that developed at the tip of the catheter grew gradually, reached a thrombotic structure, and prepared the way for infection. Some type of bacteria leads to the formation of an infection in a thrombotic environment. Microbiologic studies demonstrate that some *Staphylococcus* species adhere easily to the proteins in a thrombus such as fibrinogen and fibronectin, and the thrombus facilitates the infection with these bacteria [16]. The growth of *Staphylococcus aureus* bacteria in our case supports this observation. There is not anything published heretofore linking the diagnosis of MNGIE in a patient leading to tendency for thrombosis. On the other hand, when considering the underlying primary disease, intestinal problems, cachexia and long-term CVC application because of TPN need, it is commonly seen in people with MNGIE syndrome. The fact that should be kept in mind of clinicians who follow these patients is that it can predispose a patient to catheter-related thrombus, even infective endocarditis. However, pre-diagnosis of these types of catheter thrombosis is not easy. Venography and ultrasonography are used for catheter-related diagnosis. Although ultrasonography is a convenient method for jugular veins, its usage is limited for subclavian veins because of the effects of the clavicle, sternum and lungs on ultrasonography waves. Because venography is an invasive method, it is rarely used [17, 18]. In our case, the thrombus extended through the right atrium on the tip of the catheter and was visualized with echocardiography. We think that echocardiography is the primary method to use for the evaluation of catheter-related thrombi in the subclavian vein.

Consequently, our case was diagnosed as MNGIE. The infected thrombus developed due to long-term central venous catheterization for continuous TPN and was successfully treated, without complication, by cardiac surgery. Based on this case, we think that before removing an infected catheter, the probability of the presence of fibrin and infected thrombus (that has not led to obstruction) at the tip of the catheter should be evaluated, and in the presence of a large infected thrombus, the mass should be removed surgically.

Disclosure

Authors report no conflict of interest.

References

1. Ge X, Cavallazzi R, Li C, Pan SM, Wang YW, Wang FL. Central venous access sites for the prevention of venous thrombosis, stenosis and infection. *Cochrane Database Syst Rev* 2012; 3: CD004084. doi: 10.1002/14651858.CD004084.pub3.
2. Hirano M, Lagier-Tourenne C, Valentino ML, Martí R, Nishigaki Y. Thymidine phosphorylase mutations cause instability of mitochondrial DNA. *Gene* 2005; 354: 152-156.
3. Mihaylova V, Guergueltcheva V, Cherninkova S, Penev L, Georgieva G, Stoyanova K, Todorova A, Tournev I. Possible toxicity of tuberculostatic agents in a patient with a novel tymp mutation leading to mitochondrial neurogas-trointestinal encephalomyopathy. *J Neurogenet* 2013; 27: 19-22.

4. Venturini E, Becuzzi L, Magni L. Catheter-induced thrombosis of the superior vena cava. *Case Rep Vasc Med* 2012; 2012: 469619.
5. Darouiche RO, Raad II, Heard SO, Thornby JI, Wenker OC, Gabrielli A, Berg J, Khardori N, Hanna H, Hachem R, Harris RL, Mayhall G. A comparison of two antimicrobial-impregnated central venous catheters. Catheter Study Group. *N Engl J Med* 1999; 340: 1-8.
6. O'Grady NP, Alexander M, Dellinger EP, Gerberding JL, Heard SO, Maki DG, Masur H, McCormick RD, Mermel LA, Pearson ML, Raad II, Randolph A, Weinstein RA. Guidelines for the prevention of intravascular catheter-related infections. *Infect Control Hosp Epidemiol* 2002; 23: 759-769.
7. McGee DC, Gould MK. Preventing complications of central venous catheterization. *N Engl J Med* 2003; 348: 1123-1133.
8. Hooke C. Recombinant tissue plasminogen activator for central venous access device occlusion. *J Pediatr Oncol Nurs* 2000; 17: 174-178.
9. Kerner JA Jr, Garcia-Careaga MG, Fisher AA, Poole RL. Treatment of catheter occlusion in pediatric patients. *JPEN J Parenter Enteral Nutr* 2006; 30: S73-S81.
10. Werlin SL, Lausten T, Jessen S, Toy L, Norton A, Dallman L, Bender J, Sabilan L, Rutkowski D. Treatment of central venous catheter occlusions with ethanol and hydrochloric acid. *JPEN J Parenter Enteral Nutr* 1995; 19: 416-418.
11. Timsit JF, Farkas JC, Boyer JM, Martin JB, Misset B, Renaud B, Carlet J. Central vein catheter-related thrombosis in intensive care patients. Incidence, risks factors, and relationship with catheter-related sepsis. *Chest* 1998; 114: 207-213.
12. Kuter DJ. Thrombotic complications of central venous catheters in cancer patients. *Oncologist* 2004; 9: 207-216.
13. Samy Modeliar S, Sevestre MA, de Cagny B, Slama M. Ultrasound evaluation of central veins in the intensive care unit: effects of dynamic manoeuvres. *Intensive Care Med* 2008; 34: 333-338.
14. Hoshal VL Jr, Ause RG, Hoskins PA. Fibrin sleeve formation on indwelling subclavian central venous catheters. *Arch Surg* 1971; 102: 353-358.
15. Rosovsky RP, Kuter DJ. Catheter-related thrombosis in cancer patients: pathophysiology, diagnosis, and management. *Hematol Oncol Clin North Am* 2005; 19: 183-202.
16. Mehall JR, Saltzman DA, Jackson RJ, Smith SD. Fibrin sheath enhances central venous catheter infection. *Crit Care Med* 2002; 30: 908-912.
17. Mustafa BO, Rathbun SW, Whitsett TL, Raskob GE. Sensitivity and specificity of ultrasonography in the diagnosis of upper extremity deep vein thrombosis: a systematic review. *Arch Intern Med* 2002; 162: 401-404.
18. Baarslag HJ, van Beek EJ, Koopman MM, Reekers JA. Prospective study of color duplex ultrasonography compared with contrast venography in patients suspected of having deep venous thrombosis of the upper extremities. *Ann Intern Med* 2002; 136: 865-872.