

# Ruptured sinus of Valsalva aneurysms – our surgical experience of 7 years



Abhishek Shrinivas Joshi, Balaji Dattatray Aironi, Ninad Sunil Kotkar, Dwarkanath Vivekanand Kulkarni, Uday Eknath Jadhav, Ketak Mahendra Nagare

Seth G.S. Medical College and K.E.M. Hospital, Mumbai, India

Kardiochirurgia i Torakochirurgia Polska 2021; 18 (2): 100-104

## Abstract

**Introduction:** Aneurysms of sinuses of Valsalva are rare aortic anomalies having an incidence of 1.4–4.94% in the Asian population. Spontaneous rupture is the most common complication and ruptured aneurysms usually present with congestive cardiac failure.

**Aim:** Our study was aimed at evaluating the clinical profile of patients with ruptured sinus of Valsalva aneurysms (RSOVA) and their distribution, the surgical management and post-operative course.

**Material and methods:** We retrospectively identified 21 patients who presented to us with RSOVA over a period of 7 years and underwent surgery for the same.

**Results:** RSOVA was more common in young males. Most cases involved the right coronary sinus (RCS) followed by the non-coronary sinus (NCS). The site of rupture was mostly the right ventricular outflow tract or the right atrium. All patients had a relatively asymptomatic post-operative course in the ward. On follow-up, most of the patients were symptom free.

**Conclusions:** Surgery on cardiopulmonary bypass with moderate hypothermia with excision of windssock deformity and patching of the rupture site is a safe method of treating ruptured sinus of Valsalva aneurysms. Patients need to be followed up regularly to monitor for the development of aortic regurgitation.

**Key words:** sinus, aorta, aneurysm, regurgitation.

## Introduction

Aneurysms of sinuses of Valsalva are rare aortic anomalies having an incidence of 1.4–4.94% in the Asian population. They account for 0.1% to 3.5% of all congenital heart defects and around 0.14% to 3.5% of all open heart procedures [1–3]. These aneurysms are congenital or acquired. The congenital aneurysms are thought to result from congenital absence of elastic and muscular tissue in the wall of the sinus of Valsalva (SOV) [4]. Acquired aneurysms of the sinuses of Valsalva may be secondary to syphilis or infective endocarditis. Males are affected more than females and the reported incidence is higher in people of Asian origin as compared to others [5]. SOV aneurysms are mostly associated with ventricular septal defect (VSD) or aortic regurgitation (AR). Spontaneous rupture is the most common complication. When complicated by rupture, patients usually present with congestive cardiac failure. Ruptured sinus of Valsalva aneurysms (RSOVA), if untreated, have a median survival of 2 years. Once ruptured, surgery is the mainstay of treatment. Surgery for RSOVA is associated with a good success rate and low mortality and morbidity.

Hence, it is very important to diagnose early and proceed with surgical repair in patients with RSOVA.

## Aim

In this report, we summarize our 7 years' experience with RSOVA at our centre.

## Material and methods

We identified 21 patients in a retrospective review during the period of January 2013 to January 2020 with ruptured sinus of Valsalva aneurysms. All these patients were operated on at a tertiary care centre. The departmental review board approved the study and waived the requirement of individual consent. We chose to exclude patients with a suspicion of infective endocarditis or those with non-ruptured sinus of Valsalva aneurysm. Surgery was performed on semi-emergency basis for these patients once diagnosed. The surgical repair was done on cardiopulmonary bypass (CPB) using moderate hypothermia in an arrested heart using standard aortobicaval cannulation. Median sternotomy was the approach. Myocardial protec-

**Address for correspondence:** Abhishek Shrinivas Joshi, Seth G.S. Medical College and K.E.M. Hospital, Mumbai, India, phone: +919820326126, e-mail: drabhisheksjoshi@gmail.com

**Received:** 19.11.2020, **accepted:** 18.04.2021.

tion was achieved via antegrade del Nido cardioplegia. The follow-up duration of these patients was between 1 year and 7 years. We analysed these patients with respect to gender, age at presentation, site of aneurysm, surgical repair and post-operative course.

### **Pre-operative evaluation**

Diagnosis in these patients was made with the help of trans-thoracic echocardiography. Many of these patients were evaluated with trans-oesophageal echocardiography as well to see for feasibility of percutaneous closure. Echocardiographic examination was conclusive in all patients and no patient underwent any other investigation such as computed tomography (CT) scan or cardiac magnetic resonance imaging (MRI).

### **Surgery**

All patients underwent surgical repair under cardiopulmonary bypass with moderate hypothermia through a median sternotomy. Aortobicaval cannulation was used and the procedure was done on an arrested heart with cold del Nido cardioplegia. An oblique aortotomy was used and cardioplegia was administered directly into the coronary ostia. The right atrium (RA) incision was made parallel to the atrioventricular (AV) groove and the left atrium (LA) was vented through the inter-atrial septum. Through the RA, the windsock formed due to the RSOVA was excised. In cases where it was not excised, on the right atrial/right ventricular side, closure was done with a Dacron patch (Sauvage Filamentous Dacron – BARD) or by direct closure. On the aortic side, a Dacron patch closure was done for all patients. Correction of associated anomalies such as VSD was done during the period of cardiac arrest.

### **Post-operative evaluation**

During the post-operative course in the ward, patients underwent a 2D echo once to look for any residual anomalies or any patch leak. Patients were started on Aspirin 75 mg post-operatively and those who underwent valve replacement were started on warfarin. Once discharged, patients were followed up on an outpatient basis and underwent yearly echocardiograms.

### **Data management**

The data was obtained from in-hospital and out-patient records for these patients and was interpreted using the SPSS Statistics V26 software package.

### **Results**

During the 7-year period that we analysed, we found 21 patients who were referred to our department with RSOVA. Out of the 21 patients, 17 were male and 4 were female. The mean age of these patients at referral was  $27.8 \pm 7.79$  years (range: 15–45 years). The most common symptoms at presentation were dyspnoea on exertion in 18 (86%) patients and palpitations in 15 (71%) patients

(Table I). On admission, all patients were symptomatic and the mean duration of symptoms was 5 months. Out of 21 patients, 13 and 5 patients were in New York Heart Association (NYHA) functional class III and IV respectively. The diagnosis was made on trans-thoracic echocardiography in all patients. Two patients underwent workup for device closure of the RSOVA, but due to technical difficulties during the procedure, they were referred for surgery.

The mean CPB time was  $136 \pm 50$  min (range: 85–307 min) and the mean aortic cross clamp time was  $98 \pm 37$  min (range: 57–222 min). In 16 patients, the site of origin was the right coronary sinus (RCS) and in 5 patients, it was the non-coronary sinus (NCS). The site of rupture was the right ventricular outflow tract (RVOT) in 14 patients and the RA in 7 patients. The origins of the RSOVA and their chamber of rupture are given in Table II.

Eleven out of 21 patients had a VSD in addition to the RSOVA and underwent patch closure. Four out of 21 patients had a bicuspid aortic valve. One patient had a sub-aortic spur causing sub-aortic obstruction which was excised intra-operatively. This same patient also had 2 separate openings of the left anterior descending artery (LAD) and left circumflex artery (LCx). Eighteen patients had less than mild aortic regurgitation (AR) at surgery and 2 patients had moderate AR. One patient had severe AR when taken for surgery and underwent aortic valve replacement (AVR).

The post-operative period generally was uneventful for the majority of patients. The mean ICU stay was  $2.3 \pm 0.8$  days and the mean post-operative duration of stay was  $8.1 \pm 3.3$  days. Post-operative complications included re-exploration due to bleeding in 1 patient and wound infection in 3 patients.

There was no immediate or 30-day mortality in our series. Out of 21, 15 patients were followed up regularly until the end of the study period. One patient had patch dehiscence and presented at 1 year after the original surgery. This patient underwent redo surgery with RSOVA repair; however, this patient succumbed in the post-operative period due to intractable ventricular arrhythmias. Two patients during

**Table I.** Symptom profile of patients

Symptom	Value
Dyspnoea on exertion	18/21 (86%)
Palpitations	15/21 (71%)
Chest pain	5/21 (23%)
Fatigue	11/21 (52%)

**Table II.** Anatomical distribution of RSOVA

Site of origin of RSOVA	Site of rupture	Number
RCS	RVOT	14
	RA	2
NCS	RA	5

**Table III.** Pre-operative and operative parameters

Variables	Value
Total number of patients	21
Age [years]	27.8 ±7.79
Sex:	
Male/female	17/4
CPB time [min]	136 ±50
Aortic cross clamp time [min]	98 ±37
Associated anomalies:	
VSD	11 (52%)
AR – mild/moderate/severe	18/2/1
Bicuspid aortic valve	4 (19%)
ICU stay [days]	2.3 ±0.8
Post-operative stay [days]	8.1 ±3.3
Regular follow-up	15 (71%)

follow-up came with severe AR and underwent redo AVR. One patient had a successful term pregnancy during her follow-up and another patient is under close follow-up for moderate AR.

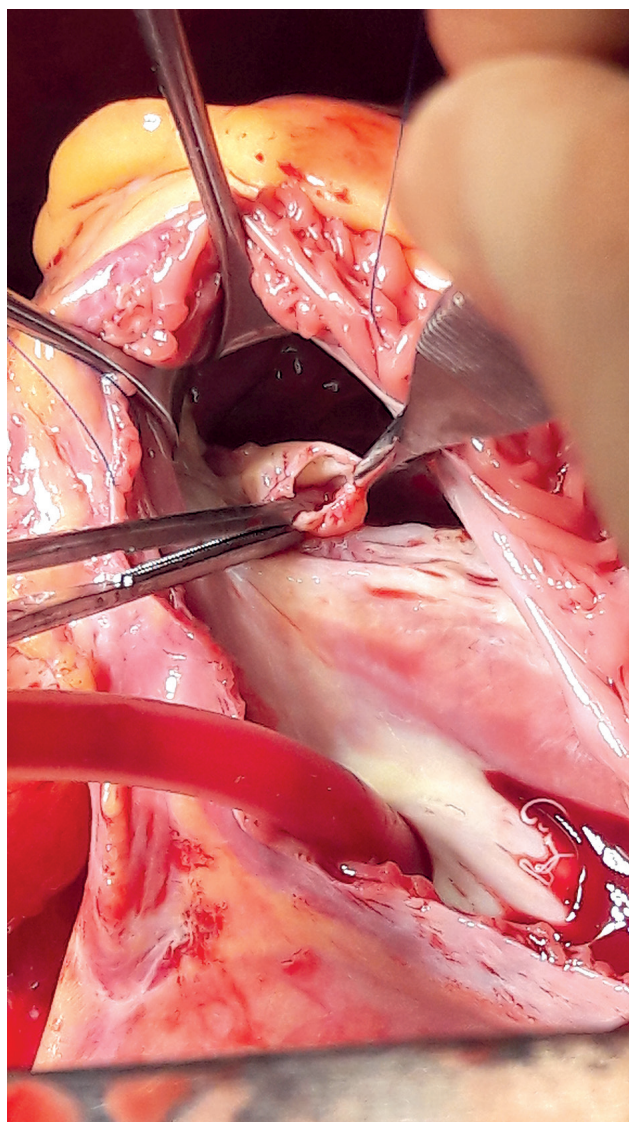
The pre-operative and operative data are summarised in Table III.

## Discussion

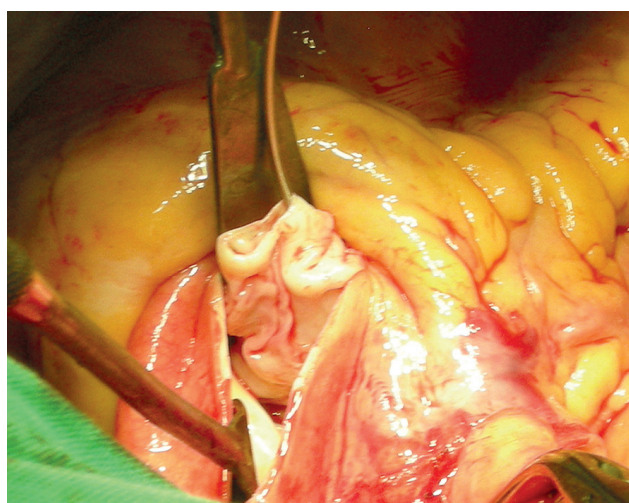
Aneurysms of the sinus of Valsalva are rare cardiac anomalies and have an incidence in the Asian population which is 5 times that of the western population [6, 7]. The description of the morphology of RSOVA was given by Edward *et al.* in 1957 where he showed that the aetiology is separation of the aortic media of the sinus from the media adjacent to the hinge line of the aortic valve cusp [8]. In 1962, Sakakibara and Konno classified congenital aneurysms of the sinuses of Valsalva into 4 types [9]. A modification was proposed by Xin-jin *et al.* to classify them into 5 types [10].

We had a very high percentage of male patients (81%) as compared to females (19%). The mean age of our patients was 27.8 years with a range of 15 to 45 years. This is very similar to other reports in the literature which showed a higher frequency of RSOVA in young males. Most of our patients were in NYHA functional class III or IV and had a mean duration of symptoms of around 5 months. Such late presentation is very common in the Indian set up and occurs due to logistical difficulties as well as poor education and literacy levels.

In our study, the right coronary sinus was the most involved followed by involvement of the non-coronary sinus (NCS) (Figures 1, 2). We did not see any case of left coronary sinus (LCS) involvement. LCS involvement is very rarely described even in the literature. The types of RSOVA that we encountered are very similar to the published literature [11–15].



**Figure 1.** Right coronary sinus – right ventricular outflow tract RSOVA seen through tricuspid valve



**Figure 2.** Right coronary sinus – right ventricular outflow tract RSOVA everted and seen through the aortic incision

RSOVA are generally associated with other cardiac anomalies, namely VSD, bicuspid aortic valves, AR, aortic coarctation and tricuspid insufficiency. VSD is most commonly found in these patients and we encountered a very high percentage (52%) of VSDs. Many previous studies have quoted a higher percentage of VSD as compared to AR in these patients [11–18]. Considerable AR was present in only 3 of our patients pre-operatively. Aortic regurgitation in RSOVA results from malcoaptation of the aortic valve cusp due to unbalanced diastolic closing pressure of the opposing cusps. Also, the Venturi effect at the prolapsing cusp can lead to distorted closure of the cusps [19]. In patients who have an associated VSD, prolapsed aortic cusps with a lack of supporting tissue can cause AR [20]. Over a period of time, valve cusps get sclerosed, thus increasing the AR and substantiating the need for aortic valve replacement rather than repair. We performed AVR for the 1 patient in whom the AR was very severe. Most of these operations were performed when aortic valve repair experience was lacking at our centre. The rate of AVR is higher in Asian patients as compared to western patients [21]. Bicuspid aortic valve, which is another commonly encountered entity along with RSOVA, was present in 4 (19%) out of 11 patients.

The surgical times of our series are longer as compared to other published reports. However, we did not encounter any untoward complication that might arise because of longer CPB times. Our patients had an uneventful post-operative stay and were discharged successfully. The reversal of NYHA status was clearly seen in our patients within their hospital stay (Table IV). We did not observe any in-hospital or 30-day mortality, and many surgeons have observed similar low figures of mortality for surgery on RSOVA. The hospital stay of our patients was in correspondence to the mean hospital stay for any of our other cardiac surgical patients. These factors stressed that RSOVA repair on CPB in an arrested heart is a relatively safe procedure to perform.

Follow-up is very important in patients after operations for RSOVA as they tend to develop AR, which has been highlighted by numerous articles in the past. Pre-operative infective endocarditis, co-existent VSD, bicuspid aortic valve, surgical approach and method of closure have been shown to influence the development of late AR [17]. Jung *et al.* found aortotomy and the aortic approach to be a significant risk factor for late AR in spite of the fact that the aortic approach facilitates better exposure of the aortic valve and possibility of repair [22]. We encountered 2 patients who presented to us with severe AR during follow-up and both underwent AVR. Both these patients had RSOVA of the RCS-RVOT type with a VSD and moderate AR prior to the first surgery, which had decreased to mild AR on post-operative echo. Over a period of time, its severity increased and they had to undergo a second operation. Probably, progression of the disease could be a reason why they progressed to severe AR as their 2D echo was near normal in the post-operative period.

Patch dehiscence, as can happen with VSDs, did happen in our series in 1 patient, and this patient underwent redo surgery with re-patching. This patient expired during the

**Table IV.** NYHA functional class of patients during the study

NYHA class	Before surgery	At discharge	Follow-up at 1 year
I	0	17	12
II	3	4	8
III	13	0	1
IV	5	0	0

redo surgery and this patient remains the only mortality in this series.

Various methods of closure of RSOVA are in practice today. Trans-catheter closure is also a safe and non-invasive technique for the treatment of this anomaly [23]. However, it has its own limitations and we had 2 patients who were referred to us due to technical difficulties in performing trans-catheter closure. Mo *et al.* described a case series of on-pump beating heart repair of RSOVA [24]. Buczkowski described a novel closure of RSOVA using the native aortic valve leaflet [25]. Similarly, minimally invasive trans-thoracic device closure of the aneurysm has been described by Gao *et al.* [26].

Although with the advent of time, percutaneous and minimally invasive approaches are taking their place in cardiac surgery, the safety of performing the same procedure in an arrested heart on cardiopulmonary bypass cannot be debated. We have obtained results which are comparable to existing literature using the conventional sternotomy approach using a cardiopulmonary bypass and cardioplegia. Hence our technique not only has general effectiveness but also is a very safe and secure technique to handle ruptured sinus of Valsalva aneurysms.

## Conclusions

RSOVA has a higher percentage of involvement in young males. VSD, aortic regurgitation and bicuspid aortic valve are anomalies commonly associated with it. Patients generally present with dyspnoea on exertion and palpitations. RCS-RVOT involvement is the most common type. Surgery on CPB with aortobicaval cannulation with moderate hypothermia with del Nido cardioplegia is a safe approach to tackle RSOVA and gives good immediate and long term results. A good quality of life can be given to these patients after surgery and a good follow-up of these patients is important to detect aortic regurgitation.

## Disclosure

The authors report no conflict of interest.

## References

1. Wang ZJ, Zou CW, Li DC, Li HX, Wang AB, Yuan GD, Fan QX. Surgical repair of sinus of Valsalva aneurysm in Asian patients. *Ann Thorac Surg* 2007; 84: 156-60.
2. Ring WS. Congenital Heart Surgery Nomenclature and Database Project: aortic aneurysm, sinus of Valsalva aneurysm, and aortic dissection. *Ann Thorac Surg* 2000; 69 (4 Suppl): S147-63.

3. Lisowski P, Hirnie T, Adamczuk A, Lisowska A, Sobkowicz B, Nadlewski S, Górny J. Rupture of the sinus of Valsalva aneurysm complicated by infective endocarditis – diagnosis difficulties. *Kardiol Pol* 2006; 64: 77-9.
4. Tomar M, Radhakrishnan S, Kaushal S, Iyer K. Unusual case of ruptured sinus of Valsalva: rupture into left ventricle cavity along with distortion of mitral valve requiring double valve replacement. *Images Paediatr Cardiol* 2009; 11: 1-6.
5. Lin CY, Hong GJ, Lee KC, Tsai YT, Tsai CS. Ruptured congenital sinus of valsalva aneurysms. *J Card Surg* 2004; 19: 99-102.
6. Moustafa S, Mookadam F, Cooper L, Adam G, Zehr K, Stulak J, Holmes D. Sinus of Valsalva aneurysms: 47 years of a single center experience and systematic overview of published reports. *Am J Cardiol* 2007; 99: 1159-64.
7. Smith RL, Irimpen A, Helmcke FR, Kerut EK. Ruptured congenital sinus of Valsalva aneurysm. *Echocardiography* 2005; 22: 625-8.
8. Edwards JE, Burchell HB. The pathological anatomy of deficiencies between the aortic root and the heart, including aortic sinus aneurysms. *Thorax* 1957; 12: 125-39.
9. Sakakibara S, Konno S. Congenital aneurysm of the sinus of Valsalva. Anatomy and classification. *Am Heart J* 1962; 63: 405-24.
10. Xin-Jin L, Xuan L, Bo P, Hong-Wei G, Wei W, Shou-Jun L, Sheng-Shou H. Modified Sakakibara classification system for ruptured sinus of Valsalva aneurysm. *J Thorac Cardiovasc Surg* 2013; 146: 874-8.
11. Luo X, Zhang D, Li B, Qi L, Gong L, Tang Y, Sun H. Surgical repair of a ruptured congenital sinus of Valsalva aneurysm: 10-year experience with 286 cases. *Eur J Cardiothorac Surg* 2019; 55: 1211-8.
12. Sarikaya S, Adademir T, Elibol A, Buyukbayrak F, Onk A, Kirali K. Surgery for ruptured sinus of Valsalva aneurysm: 25-year experience with 55 patients. *Eur J Cardiothorac Surg* 2013; 43: 591-6.
13. Choudhary SK, Bhan A, Sharma R, Airan B, Kumar AS, Venugopal P. Sinus of Valsalva aneurysms: 20 years' experience. *J Card Surg* 1997; 12: 300-8.
14. Au WK, Chiu SW, Mok CK, Lee WT, Cheung D, He GW. Repair of ruptured sinus of valsalva aneurysm: determinants of long-term survival. *Ann Thorac Surg* 1998; 66: 1604-10.
15. Dong C, Wu QY, Tang Y. Ruptured sinus of valsalva aneurysm: a Beijing experience. *Ann Thorac Surg* 2002; 74: 1621-4.
16. Yan F, Huo Q, Qiao J, Murat V, Ma SF. Surgery for sinus of valsalva aneurysm: 27-year experience with 100 patients. *Asian Cardiovasc Thorac Ann* 2008; 16: 361-5.
17. Murashita T, Kubota T, Kamikubo Y, Shiiya N, Yasuda K. Long-term results of aortic valve regurgitation after repair of ruptured sinus of valsalva aneurysm. *Ann Thorac Surg* 2002; 73: 1466-71.
18. Diwakar A, Patnaik SS, Hiremath CS, Chalam KS, Dash P. Rupture of sinus of valsalva – a 15 years single institutional retrospective review: preoperative heart failure has an impact on post operative outcome? *Ann Card Anaesth* 2019; 22: 24-9.
19. Nascimbene A, Joggerst S, Reddy KJ, Cervera RD, Ott DA, Wilson JM, Stainback RF. Aortic valve regurgitation that resolved after a ruptured coronary sinus aneurysm was patched. *Tex Heart Inst J* 2013; 40: 489-92.
20. Maruo A, Higami T, Obo H, Shida T. Ruptured sinus of Valsalva aneurysm associated with aortic regurgitation caused by hemodynamic effect solely. *Eur J Cardiothorac Surg* 2003; 24: 318-9.
21. Azakie A, David TE, Peniston CM, Rao V, Williams WG. Ruptured sinus of valsalva aneurysm: early recurrence and fate of the aortic valve. *Ann Thorac Surg* 2000; 70: 1466-70; discussion 70-1.
22. Jung SH, Yun TJ, Im YM, Park JJ, Song H, Lee JW, Seo DM, Lee MS. Ruptured sinus of Valsalva aneurysm: transaortic repair may cause sinus of Valsalva distortion and aortic regurgitation. *J Thorac Cardiovasc Surg* 2008; 135: 1153-8.
23. Sinha SC, Sujatha V, Mahapatro AK. Percutaneous transcatheter closure of ruptured sinus of valsalva aneurysm: immediate result and long-term follow-up. *Int J Angiol* 2015; 24: 99-104.
24. Mo A, Lin H. Surgical correction of ruptured aneurysms of the sinus of Valsalva using on-pump beating-heart technique. *J Cardiothorac Surg* 2010; 5: 37.
25. Buczkowski P, Walczak M, Stefaniak S, Puślecki M, Katyńska I, Jemielity M. Closure of ruptured aneurysm of the sinus of Valsalva using a native aortic valve leaflet. *Cardiovasc J Afr* 2014; 25: e4-6.
26. Gao L, Wu Q, Xu X, Zhao T, Yang Y. Minimally invasive transthoracic device closure of an acquired sinus of valsalva-right ventricle fistula in a pediatric patient. *Iran J Pediatr* 2014; 24: 327-30.