

Endoscopic resection of Abrikossoff tumour of the oesophagus – case report

Endoskopowa resekcja guza Abrikossoffa przełyku – opis przypadku

Cezary Popławski¹, Anna Szaflarska-Popławska², Dariusz Sosnowski¹

¹Department of Gastrointestinal Endoscopy Ludwik Rydygier *Collegium Medicum* in Bydgoszcz Nicolaus Copernicus University in Toruń

²Chair and Department of Paediatrics, Allergology and Gastroenterology Ludwik Rydygier *Collegium Medicum* in Bydgoszcz Nicolaus Copernicus University in Toruń

Przegląd Gastroenterologiczny 2008; 3 (5): 262–264

Key words: Abrikossoff tumour, oesophagus, endoscopic resection.

Słowa kluczowe: guz Abrikossoffa, przełyk, resekcja endoskopowa.

Address for correspondence: Anna Szaflarska-Popławska, MD, PhD, Department of Paediatrics, Allergology and Gastroenterology Ludwik Rydygier *Collegium Medicum* in Bydgoszcz Nicolaus Copernicus University in Toruń, 9 Maria Curie-Skłodowska Street, 85-094 Bydgoszcz, Poland, tel. +48 52 585 48 50, fax +48 52 585 40 86, e-mail: klped@cm.umk.pl

Abstract

Granular cell tumours are rare tumours that occur in various organs, including the digestive tract. Selection of treatment method for these tumours is still widely discussed in the literature. This report presents a 52-year-old patient in whom accidentally diagnosed granular cell tumour in the distal part of the oesophagus was removed as a whole using the lift-and-cut endoscopic method with a coagulation loop after previous tumour elevation by injection of physiological saline solution. Infiltration of deep layers of the oesophagus by tumour cells was previously excluded using endoscopic ultrasonography.

Abrikossoff was the first to describe granular cell tumour (GCT) in 1926 and he qualified this tumour as myoblastic myoma on the basis of morphological features and frequent localization on the tongue [1]. Subsequent studies confirmed that the majority of granular cell tumours originate from Schwann cells and this fact was proved by their immunoreactivity with S-100 protein, neuron-specific enolase and the presence of incomplete basal lamina and many intracellular autophagocytosing vacuoles comprising myelin connected with cell membrane [2].

Granular cell tumours occur rarely, but the frequency of their diagnosis has significantly increased during recent years due to wide gastrofibroscopy accessibility [3]. These tumours can occur at any age, but are found extremely rarely in children. Tumours are

Streszczenie

Guzy z komórek ziarnistych należą do rzadkich guzów występujących w różnych narządach, w tym w obrębie przewodu pokarmowego. Wybór sposobu leczenia tych guzów jest nadal szeroko dyskutowany w piśmiennictwie. W niniejszej pracy przedstawiono przypadek 52-letniego pacjenta, u którego przypadkowo wykryty guz z komórek ziarnistych w obrębie dystalnej części przełyku został w całości usunięty metodą endoskopową *lift and cut* z zastosowaniem pętli koagulacyjnej po wcześniejszym uniesieniu guza przez wstrzyknięcie roztworu soli fizjologicznej. Naciekanie głębszych warstw przełyku przez komórki guza zostało wcześniej wykluczone przy użyciu metody ultrasonografii endoskopowej.

most often diagnosed during the 4th–6th decade of life, twice to three times more often in women than in men, and three times more often in dark-skinned persons [4]. Tumours can occur in every organ. They are most often found on the tongue (23–28% of cases) and in different regions of the head and the neck, such as the orbital cavity, the larynx, the parotid glands, the peripheral nerves or rarely the cranial nerves [5]. About 1–8% of granular cell tumours are located in the digestive tract and about 1/3 of them in the oesophagus [6].

Granular cell tumours are usually asymptomatic and are revealed accidentally as isolated submucosal tumours with granulated or normal mucosa above the tumour, sometimes with ulceration or decreased mucosa that macroscopically resembles lipomas [3, 6]. Not seldom, foci of tumour cells are situated directly

under the mucosa and many biopsy specimens allow an appropriate diagnosis to be established. It should be remembered that the tumour can cause pseudoepitheliomatous hyperplasia situated above the mucosa and imitate invasive squamous cell cancer [5, 6]. Granular cell tumour usually occurs individually, but there are described cases of multiple tumours both within and beyond the digestive tract [6]. Considering histopathology, granular cell tumours are composed of fusiform cells grouped in characteristic nests that reveal immunoreactivity with S-100 protein [7].

Malignant granular cell tumours are extremely rare and constitute 1-2% of all tumours [2]. The macroscopic and microscopic picture of benign and malignant tumours is similar. Some authors suggest diagnosing malignant tumours in the case of regional lymph nodes involvement and/or distant metastases, but there have been described cases of malignant tumours causing local recurrence without metastases [2]. It seems that tumour diameter larger than 5 cm, deeper lesion localization within soft tissues, necrosis, increased size and significant polymorphism of cell nuclei with hyperchromasia and mitotic activity can suggest malignant character of the tumour [6, 8].

Case report

A 52-year-old patient after right-sided laser chordectomy in 2004 due to cancer of the right vocal cord was sent to the Surgical Department due to

abdominal pains in the middle epigastrium. His status during admission was good – there were no significant abnormalities in physical examination, except for tenderness in the middle epigastrium. There were no abnormalities in laboratory tests during admission (blood cell count, ionogram, ALAT, AspAT, CK-MB, creatinine, bilirubin, APTT, amylase in the serum and in the urine), besides leukocytosis (18.38 K/Ul) and non-significantly increased creatinine level (1.5 mg/dl). The chest X-ray film revealed the presence of a shadow 1 cm in diameter and located on the left above the diaphragm and resembling the nipple, showing varying shades. The X-ray film of the abdomen did not present features of mechanical ileus and perforation of the digestive tract, but it only showed single fluid levels in the mesogastrium. Abdominal ultrasonography revealed liver lesions – in the form of enlargement and hyperechogenicity of the organ – and also showed the presence of a cyst 12 mm in diameter. Chronic gastritis with *Helicobacter pylori* infection was diagnosed on the basis of endoscopic examination of the upper part of the digestive tract. Chronic gastritis was cured using proton pump inhibitors. After one month control endoscopic examination revealed chronic gastritis, but additionally also the presence of endoscopic features of hiatus hernia and a 3 × 6 mm yellow tumour indenting into the oesophagus lumen at the level of 33 cm from the incisors (Figures 1 and 2). Histopathological assessment of a biopsy specimen

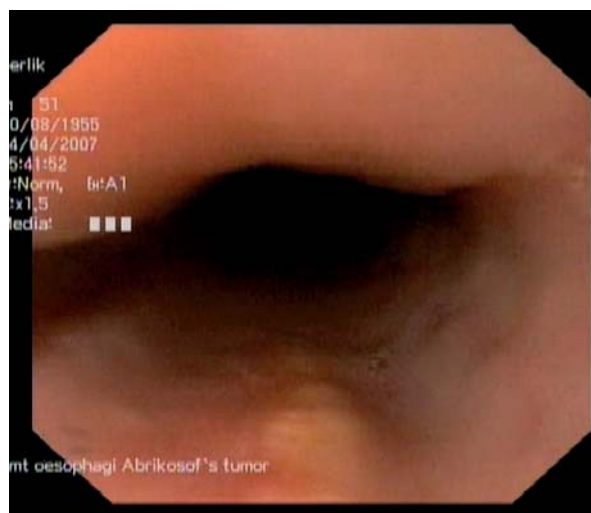


Fig. 1. Endoscopic picture showing a yellowish submucosal tumour in the lower part of the oesophagus

Ryc. 1. Obraz endoskopowy zmiany o charakterze żółtawego guza podśluzówkowego w dolnej części przełyku

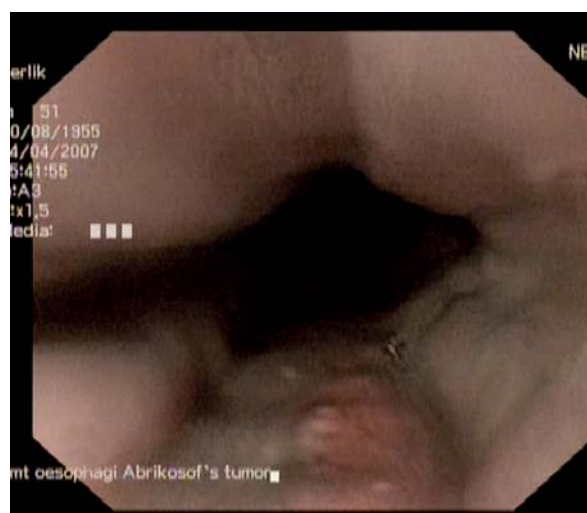

Fig. 2. Endoscopic picture with narrow band imaging system showing a submucosal tumour in the lower part of the oesophagus

Ryc. 2. Obraz endoskopowy zmiany o charakterze guza podśluzówkowego w dolnej części przełyku z zastosowaniem metody NBI

taken from the lesion in the oesophagus elicited the presence of cells typical for Abrikossoff tumour. Infiltration of the oesophagus wall by the tumour was excluded on the basis of endoscopic ultrasonography. There were noted only non-significant thickening concerning the hypoechogenic layer of the mucosa and lamina propria of the mucosa with preserved continuity of the mucosa, submucosa, muscular layer and external membrane. The lesion described in the oesophagus was removed endoscopically using a coagulation loop after previous injection of physiological saline solution and adrenaline under the mucosa (lift-and-cut method), but place after removal was provided using APC argon photocoagulation. The results of histopathological examination confirmed complete removal of a lesion that had the character of Abrikossoff tumour.

Discussion

This report presents a 52-year-old patient in whom a single submucosal granular cell tumour in the distal part of the oesophagus was removed as a whole using the endoscopic lift-and-cut method with a coagulation loop after previous tumour elevation by injection of physiological saline solution. Infiltration of deeper layers of the oesophagus by tumour cells was previously excluded using endoscopic ultrasonography. This method is particularly useful for assessment of tumour size and tumour infiltration concerning the lamina propria of the mucosa, and that is why this method is useful for risk assessment concerning endoscopic methods of treatment [3, 6, 9]. Abrikossoff tumour location in the lower part of the oesophagus concerns the majority of patients with this type of tumour [10].

Selection of treatment method for granular cell tumours is still discussed in the literature. Some authors propose procrastination with periodic endoscopic controls, especially in the case of tumours smaller than 10 mm and without features of tumour enlargement or its malignant transformation [6, 7, 10]. Such management can be risky, because the final diagnosis often cannot be established before total lesion removal [9]. Traditional surgical methods are also used in the treatment of submucosal tumours. However, it is necessary to remember that many patients have relative contraindications for surgical intervention [5]. Nowadays endoscopic methods are most often proposed to remove submucosal tumours, indicating the possibility of incomplete resection, using traditional polypectomy with a diathermic loop [9]. Prior injection of a small amount of physiological saline solution [9] or dehydrated alcohol [3] is particularly advised to divide the infiltration from the lamina

propria of the mucosa. On the one hand this enables total resection to be performed, and on the other hand it decreases perforation risk [9]. Subsequent tumour resection can be performed using endoscopic mucosectomy with accessories for oesophageal varices ligation [9]. Some authors also propose treatment of granular cell tumours using coagulation with the argon beamer [11].

According to our assessment the described patient requires periodic endoscopic control. Once a year or once in two years is the frequency of control endoscopic examinations proposed by some authors in the case of non-resected small tumours [10]. It seems that previously diagnosed cancer of the vocal cord is a convincing factor for endoscopic control in the case of the described patient.

References

1. Abrikossoff AL. Uber Myome auesgehend von der quergestreifen wilkurlichen muskulatur. Virchows Arch A Pathol Anat 1926; 260: 215-33.
2. Simsir A, Osborne BM, Greenebaum E. Malignant granular cell tumor: a case report and review of the recent literature. Hum Pathol 1996; 8: 853-8.
3. Brandimarte G, Tursi A, Vittori I, Monardo E. Granular cell tumour of the oesophagus: a rare case of dysphagia with differential diagnosis of oesophageal neoplastic lesions. Dig Liver Dis 2000; 32: 803-6.
4. Wright: Chapter in book: Weiss SW, Goldblum JR. Granular cell tumours. In: Enzinger and Weiss's (2001) soft tissue tumors. 4th ed. St Louis, Mo Mosby, 2001; 1178-87.
5. Sposto MR, Navarro CM, de Andrade CR. Granular cell tumour (Abrikossoff's tumour): a case series. Oral Oncology 2006; 42: 194-7.
6. Goldblum JR, Rice TW, Zuccaro G, Richter JE. Granular cell tumors of the esophagus: a clinical and pathologic study of 13 cases. Ann Thorac Surg 1996; 62: 860-5.
7. Sánchez Muñoz D, Hoyas Pablos E, Ramirez Martin Del Campo M i wsp. Different approaches to therapy of esophageal granular cell tumor (Abrikossoff tumor). Scand J Gastroenterol 2006; 8: 993-4.
8. Onoda N, Kobayashi H, Satake K i wsp. Granular cell tumor of the duodenum: a case report. Am J Gastroenterol 1998; 93: 1993-4.
9. Shikuwa S, Matsunaga K, Osabe M i wsp. Esophageal granular cell tumor treated by endoscopic mucosal resection using a ligating device. Gastrointest Endosc 1998; 6: 529-32.
10. Orłowska J, Pachlewski J, Gugulski A, Butruk E. A conservative approach to granular cell tumor of the esophagus: four case reports and literature review. Am J Gastroenterol 1993; 2: 311-5.
11. Casetti T, Bertinelli E, Cantoni F i wsp. Endoscopic treatment of granular cell tumor of esophagus by argon plasma coagulation (APC). Gastrointest Endosc 1998; 4: A1.