

Strangulation of a Meckel's diverticulum in a femoral hernia (Littre's hernia)

Piotr Misiak, Łukasz Piskorz, Leszek Kutwin, Sławomir Jabłoński, Jacek Kordiak, Marian Brocki

Department of Chest Surgery, General and Oncological Surgery, University Hospital No. 2., Medical University of Lodz, Poland

Prz Gastroenterol 2014; 9 (3): 172–174

DOI: 10.5114/pg.2014.43580

Key words: Meckel's diverticulum, strangulation, femoral hernia.

Address for correspondence: Piotr Misiak MD, PhD, Department of Chest Surgery, General and Oncological Surgery, University Hospital No. 2, Medical University of Lodz, 113 Żeromskiego St, 90-549 Łódź, phone: +48 510 115 108, e-mail: pitmis@interia.pl

Abstract

Femoral hernia is usually presented as a flexible, round, domed shape lying on the medial side of the thigh about 2–3 cm below the inguinal ligament. Among the external hernias, femoral hernia is the second most common inguinal hernia. Its prevalence reaches 20%. Among all inguinal hernias, femoral hernias are characterised by a high level of incarceration and strangulation. This can be as high as 60%. We would like to present a case of 71-year-old patient who was admitted to the Clinic urgently due to strangulation of Meckel's diverticulum in a right-sided femoral hernia. Strangulation of Meckel's diverticulum in femoral hernia is an extremely rare entity. It was described for the very first time in 1700 by Littre.

Introduction

Femoral hernia is usually presented as a flexible, round, domed shape lying on the medial side of the thigh about 2–3 cm below the inguinal ligament. The diameter of femoral hernias rarely exceeds 5 cm. It has been estimated that for women the percentage of prevalence is high and reaches as much as 34% of all hernias, while for men the prevalence rate reaches less than 5% [1]. The increased incidence among women is directly related to the construction of a wider pelvis, a history of births and progressive with age relaxation of tissues. Narrow and rigid femoral canal foster to incarceration and strangulation of the contents of hernial sac, even as much as 60%. Thus prompt surgery is needed to avoid complications. Awareness of this condition may help to avoid delay in management [2, 3].

Strangulation of Meckel's diverticulum in femoral hernias (Littre's hernia) is an extremely rare entity. Meckel's diverticulum is a vestigial remnant of the omphalomesenteric duct (also called the vitelline duct or yolk stalk) and is reported to occur in from 0.2% to 2.0% of the general population [1]. For the very first time it was described in 1598 by Fabricius Hildanaus and later named after Johann Friedrich Meckel, who described the embryological origin of this type of diverticulum in 1809 [4].

Case report

A 71-year-old female was admitted to the Clinic of Thoracosurgery, General and Oncological Surgery Military Academy Hospital in Lodz with a 2-day history of progressive pain in the lower abdomen radiating to the right groin.

One day before admission the patient noticed the presence of a painful lump approximately 3 cm below the inguinal ligament on the medial side of the right thigh. The medical interview revealed that for about 12 h the pain was accompanied by stool retention without stopping of gas.

During the examination in the emergency unit the general, cardiovascular and respiratory examination were normal. Blood pressure measurement indicated a value of 140/80 and heart rate was approximately 100 beats per minute. The abdomen was slightly distended, painful in lower abdomen region with diminished peristalsis. Rectal examination revealed absence of stool and slight tenderness during the palpation of right side of the rectal wall.

At the medial side of the right thigh we found a tender lump 4 cm long and 3 cm in diameter that was irreducible. The skin over the lump was hot and slightly erythematous. The laboratory examinations showed increased value in white blood count (WBC) $15.0 \times 10^3/\mu\text{l}$ (4.0–11.0), and there were no other abnormalities. Ul-

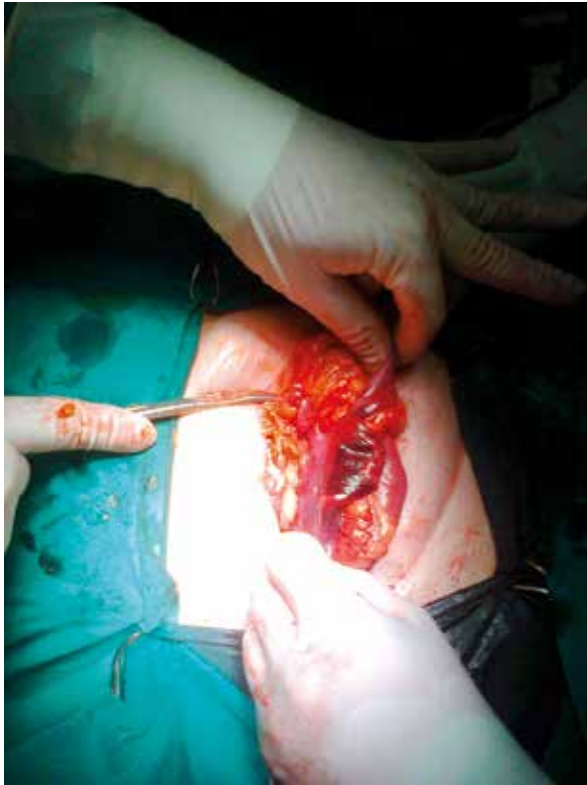

Figure 1. Intraoperative findings

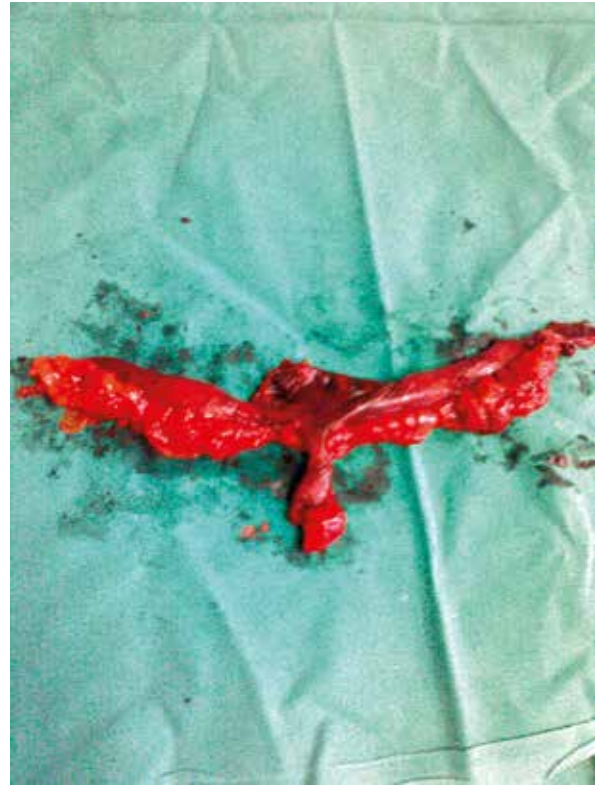


Figure 2. Resected intestine with Meckel's diverticulum

trasound examination of the abdominal cavity revealed the presence of distended intestinal loops, with ineffective peristalsis filled with a liquid content. Furthermore, in the above study, on the medial side of the right thigh, the radiologist described an incarcerated femoral hernia containing an immovable intestinal loop. Thus the patient was qualified to urgent surgical procedure.

Under general anaesthesia, a right incision 1 cm above the lump was made, and the femoral hernia sac was identified and dissected. After opening the sac a significant amount of dark-purple fluid was visualised. The contents of the hernia sac consisted of necrotic ileal loop with Meckel's diverticulum protruding at its antimesenteric border (Figures 1 and 2).

After widening the hernial gate by cutting the transverse fascia and partially the inguinal ligament, we performed resection of the necrotic part of the ileum with mechanical anastomosis side by side. A Cooper's ligament repair was used to close the femoral ring and the defect in the posterior wall of the inguinal canal.

The postoperative period was uneventful, and the patient was discharged on the third day after surgery.

Discussion

Femoral hernias occur more often in women (4 : 1 ratio F : M), more often as a small lump, approximately 5 cm in diameter, usually localised in the area of the medial right thigh (2 : 1 ratio R : L) [1–3]. It has been estimated that more than 20 million hernias are repaired yearly around the world, and 20% of these are operations of femoral hernias [5]. The percentage of incarceration and strangulation in cases of femoral hernias is high, even as much as 60% [2]. This relatively high incidence is not surprising considering the narrowness and unyielding character of the femoral ring. In most cases the lacunar ligament brings about the constriction.

After passing the femoral ring, the hernial sac invaginates to the femoral canal, which does not occur in normal conditions, then the hernia leaves the femoral canal through the foramen ovale in fascia lata, which is called the external femoral ring [1].

Femoral hernia is always acquired. This hernia may contain: stomach, omentum, colon, small intestines (when the wall of the small intestine is partially strangulated it is a so-called Richter's hernia), the appendix (De Garengeot hernia), urinary bladder, fallopian tube and ectopic testis [1, 3, 6–8].

The differential diagnosis includes enlarged inguinal lymph nodes, inguinal hernia, hydrocele of the cord or of the canal of Nuck, varices of the greatest saphenous vein, femoral artery aneurysm, ectopic testis and psoas abscess [1, 8].

Incarceration of femoral hernia is a potentially life threatening complication. The leading symptom is usually an irremovable painful lump, located on the medial side of the thigh, often difficult to palpate in obese patients.

The clinical symptoms are often ambiguous and largely dependent on the contents of the hernial sac. In cases of isolated incarceration of the appendix, Meckel's diverticulum or other internal organs of the abdominal cavity, such as bladder or fallopian tube, the patient may not present symptoms characteristic for gastrointestinal occlusion, and often the correct diagnosis occurs intraoperatively. In some cases the first symptom reported by patients admitted to hospital is the occurrence of a faecal fistula with its mouth beneath the lacunar ligament [7].

In the clinical case mentioned above, the patient presented symptoms distinctive for the early phase of gastrointestinal occlusion (stool retention with partially preserved, yet slowly deteriorating peristalsis). Notably, the ultrasonographic diagnostics contributed to the correct preoperational diagnosis, which, despite it being the 21st century, is not accessible in every hospital during ER treatment.

In the presented case we applied a sub-inguinal incision along the long axis of the hernial sac. Femoral access tends to cause considerably less perioperative trauma. Nonetheless, throughout this access resection of the ischaemic intestine fragment is highly difficult to conduct. Moreover, the operation of femoral hernia in Cooper's ligament repair are characterised by a higher percentage of recurrence when compared to other operational methods conducted via access above the inguinal ligament [1]. Because of this it should be used in the first order on elderly patients, while on the younger patients a high approach from above the inguinal ligament should be applied.

Conclusions

Incidence of Meckel's diverticulum in femoral hernia is extremely rare. The clinical symptoms of strangulation and necrosis of an intestinal fragment can be inconclusive. Every hernia with strangulation signs should be operated on immediately after hospital admittance. Ultrasound diagnostics is an additional examination that supports the correct preoperational diagnosis.

References

1. Baum RK, Olch IY. Meckel's diverticulum incarcerated in a femoral hernia. *Calif Med* 1958; 88: 386-8.
2. Davies M, Davies C, Morris-Stiff G, et al. Emergency presentation of abdominal hernias: outcome and reasons for delay in treatment – a prospective study. *Ann R Coll Surg Engl* 2007; 89: 47-50.
3. Rebai W, Hentati H, Makni A, et al. Appendicitis in strangulated femoral hernia: a case report. *La Tun Med* 2010; 88: 193-5.
4. Piskorz Ł, Śmigieński J, Lesiak T, et al. Meckel's diverticulum and its complications [Polish]. *Lek Woj* 2011; 89: 148-54.
5. Dabbas N, Adams K, Pearson K, et al. Frequency of abdominal wall hernias: is classical teaching out of date? *JRSM Short Rep* 2011; 2: 5.
6. Doddi S, Sagar V, Singhal T, et al. Femoral hernia with a twist. *Case Report Med* 2010; 2010. pii: 650829.
7. Payson BA, Schneider KM, Victor MB. Strangulation of a Meckel's diverticulum in a femoral hernia (Littre's). *Ann Surg* 1956; 144: 277-81.
8. Alzaraa A. Unusual contents of the femoral hernia. *Obstet Gynecol* 2011; 2011: 71792.

Received: 20.10.2011

Accepted: 25.04.2012