

Adalimumab for endoscopic and histopathological mucosal healing in paediatric patients with moderate to severe Crohn's disease

Edyta Szymanska¹, Maciej Dadalski², Wieslawa Grajkowska³, Sylwia Szymanska³, Maciej Pronicki³, Jaroslaw Kierkus²

¹Department of Paediatrics, Nutrition and Metabolic Disorders, Children's Memorial Health Institute, Warsaw, Poland

²Department of Gastroenterology, Hepatology, and Feeding Disorders, Children's Memorial Health Institute, Warsaw, Poland

³Department of Pathology, Children's Memorial Health Institute, Warsaw, Poland

Gastroenterology Rev 2017; 12 (1): 44–48

DOI: 10.5114/pg.2016.64746

Key words: adalimumab, deep remission, mucosal healing, Crohn's disease.

Address for correspondence: Edyta Szymanska MD, Department of Paediatrics, Nutrition, and Metabolic Disorders, Children's Memorial Health Institute, Al. Dzieci Polskich 20, 04-730 Warsaw, Poland, phone: +48 513 017 570, e-mail: edyta.szymanska@onet.com.pl

Abstract

Introduction: Deep remission, defined as clinical remission with mucosal healing (MH), with anti-tumor necrosis factor (TNF)- α agents is a new target for therapy in Crohn's disease (CD). Provided that the efficacy of infliximab (IFX) for induction of MH in CD has been demonstrated, there are much less data for adalimumab (ADA), and none concerning MH on histopathological examination.

Aim: To assess the impact of biological therapy with ADA on both endoscopic and histopathological MH in paediatric patients with CD.

Material and methods: Twenty-three children (10 boys and 13 girls) aged 13.0 ± 9.3 years with moderate to severely active CD diagnosed at the mean age of 5.5 ± 0.83 years were included into the study. Seven (30.4%) patients had been previously treated with infliximab and switched to ADA due to intolerance or loss of response. Colonoscopy and gastroscopy with sample collection were performed in all patients before and after induction treatment with ADA. Clinical activity of the disease was assessed using the Paediatric Crohn's Disease Activity Index (PCDAI), and the endoscopic activity was scored using the Simple Endoscopic Score (SES-CD). Histological changes were evaluated by a self-adapted numerical scoring system.

Results: Four (17.4%) patients reached clinical remission ($PCDAI \leq 10$). When comparing data at baseline and at a week after ADA treatment, a significant decrease was observed in median PCDAI and in SES-CD score between the initial and control colonoscopies. We reported a decrease in histological scale, which was not statistically significant. A correlation was found between PCDAI and SES-CD score.

Conclusions: Biological therapy with ADA has a positive impact on endoscopic mucosal healing in paediatric patients with CD, which is not associated with histological evidence of suppression of inflammation. Endoscopic MH correlates better than microscopic one with clinical remission.

Introduction

Crohn's disease (CD), along with ulcerative colitis (UC), belongs to the inflammatory bowel disease (IBD) group [1, 2]. The pathogenesis of this condition has not been established yet, so there is no causal treatment for CD [3]. Consequently, the treatment has been limited to obtaining the longest possible remission and preventing relapses [4, 5]. Recently, however, therapeutic goals in CD are evolving beyond the control of symptoms towards deep remission, which encompasses clinical re-

mission and mucosal healing (MH). The ultimate goals are to prevent bowel damage, reduce long-term disability, and maintain normal quality of life [6, 7]. Novel therapies such as biological agents, including infliximab (IFX) and adalimumab (ADA), have been demonstrated to improve in a considerable manner both the clinical and endoscopic variables [8–10]. In CD, so-called “deep remission” (in adults) has been recently defined as Crohn's Disease Activity Index (CDAI) < 150 and complete MH [11]. Moreover, in the near future the concept

of deep remission might also include MH on histopathological examination in CD. However, there were studies, carried out on paediatric patients, which demonstrated little correlation between endoscopic MH and clinical remission of the disease, as determined by the Crohn's disease activity index (PCDAI) [12, 13]. In some studies endoscopic evidence of mucosal healing was not necessarily associated with histological evidence of suppression of inflammation [14, 15]. Nonetheless, it must be stressed that in CD histological assessment of mucosal healing is the only way to establish in an objective manner the reversion of the mucosa to a normal state [16]. Nonetheless, deep histological remission is at present not recommended as a primary endpoint for therapeutic trials because of the lack of a standardised approach.

Aim

As data concerning deep remission in children with CD are limited, the aim of this study was to verify the impact of induction therapy with ADA on mucosal healing with particular consideration of microscopic improvement.

Material and methods

A retrospective analysis of patients diagnosed with CD and treated with biologic therapy with ADA at the Department of Gastroenterology, Hepatology, and Feeding Disorders of the Children's Memorial Health Institute was performed. The analysis included an 8-year period of time – between 2005 and 2013 (Table I).

The primary objective of this study was to evaluate the clinical, endoscopic, and microscopic activity of the disease in our patients prior to treatment (baseline) and after induction therapy (endpoint) with ADA. Disease activity was evaluated using PCDAI, which takes into account both clinical and biochemical parameters. Clinical remission was defined as PCDAI < 10. Selected endoscopic parameters (ulcer size, ulcerated and affected surfaces, stenosis) were scored from 0 to 3 using the Simple Endoscopic Score (SES-CD). Mucosal healing was defined as a complete absence of ulcers or a significant decrease in SES-CD as a sign of inflammatory lesion decrease in the presence of ulcerated surfaces, while stationary endoscopic features stood for the lack of progression or regression. Histological changes were precisely described and evaluated by a numerical scoring system for CD, which was adopted for the purpose of this study (Table II).

Deep microscopic remission was defined as a complete absence of inflammation in histological examination or a significant decrease in the scoring of histological scale. Stationary microscopic features were considered as the lack of progression or regression.

Statistical analysis

The proportion of patients in clinical response and in clinical remission after ADA treatment was assessed. All analyses were based on a per-protocol principle. The Wilcoxon test was used to compare quantitative variables, and $p < 0.05$ was regarded as significant. Scorings in SES-CD and histological grading scale were used as two independent variables in the analysis of discrimination between the group with clinical response vs. the group with no response.

Results

Seven (30.4%) out of 23 patients had previously been treated with IFX and had switched to ADA due to intolerance (3/7) or loss of response (4/7). Four (17.4%) patients reached clinical remission, and 15 (65.2%) children responded to the therapy. When comparing data at baseline and after ADA treatment, a significant decrease was observed in median PCDAI (baseline median (interquartile range) 45 (30.0–65.0) vs. 15

Table I. Detailed characteristics of analysed CD patients treated with adalimumab ($n = 23$)

Parameter	Characteristic
Gender, n (%):	
Males	10 (30.3)
Females	13 (69.7)
Age [years]	5.5 ± 0.83
Mean duration time of disease [months]	18.5 ± 8.5
Non-TNF- α naïve patients (former treatment with IFX), n (%)	7 (30.4)
PCDAI, median (interquartile range)	45.0 (10.0–67.5)
Involved region (%):	
Ileal (L1)	4.3
Colonic (L2)	52.2
Ileocolonic (L3)	30.3
Upper disease (L4)	26.1
Behaviour (%):	
B1	84.5
B2	1.9
B3	13.6
SES-CD, median (interquartile range)	14.0 (6.0–27.0)
Histological score, median (interquartile range)	6.0 (0.0–15.0)

B1 – non-stricturing, non-penetrating, B2 – stricturing, B3 – penetrating, IFX – infliximab.

Table II. Self-adapted numerical histologic scoring system for CD

Features	Lesions localisation					Score
	Terminal ileum	Right colon	Transverse colon	Left colon	Rectum	
0 – normal						
1 – minimal inflammation/inactive						
2 – active inflammation						
3 – severe inflammation, ulceration						
Total score						

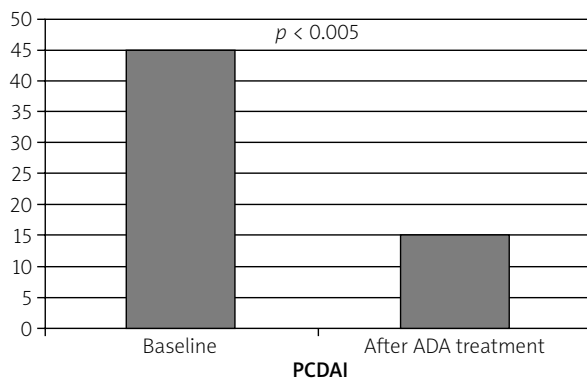


Figure 1. Impact of ADA on clinical remission: a significant decrease was observed in median PCDAI (baseline median (interquartile range) 45 (30.0–65.0) vs. 15 (0.0–15.0)) following ADA treatment

(0.0–15.0) after ADA treatment) (Figure 1), and in SES-CD score between the initial and control colonoscopies (14.0 (6.0–27.0) vs. 9.5 (0.0–27.0)) (Figure 2). Four (17.4%) out of 23 patients had complete mucosal healing (score of 0) in control endoscopy vs. none in ini-

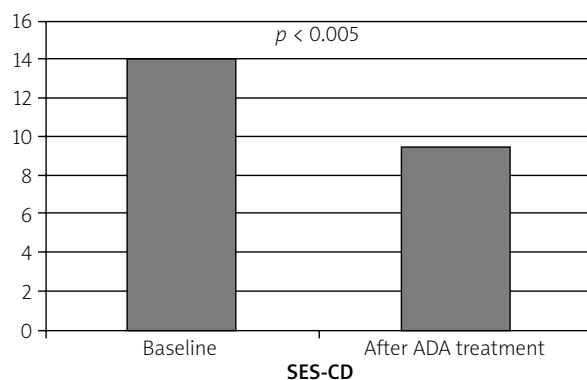


Figure 2. Impact of ADA on endoscopic mucosal healing: a significant decrease was observed in SES-CD score between the initial and control colonoscopies (14.0 (6.0–27.0) vs. 9.5 (0.0–27.0))

tial colonoscopy. No statistically significant decrease in histological score was reported (5.7 (0.0–15.0) vs. 5.3 (0.0–15.0)) (Figure 3). Separate analysis of the subgroup who switched from IFX to ADA demonstrated comparable results after ADA treatment: mean SES-CD 8.9 (0.0–20.0) and mean histologic score 5.3 (2.0–15.0), respectively. One (14.3%) child had complete mucosal healing, while no switched patient had complete remission on histopathological examination.

Only SES-CD score had a significant impact on discrimination between the group with clinical remission vs. no remission – partial Wilks' $\lambda = 0.0036$, while histological changes did not discriminate significantly between those two groups – partial Wilks' $\lambda = 0.6336$.

Discussion

The aim of this study was to provide evidence of a successful ADA treatment as regards mucosal healing and to assess its impact on deep remission expressed by suppression of inflammation in histopathological examination in children with moderate to severe CD. Current data on the mucosal effects of anti-tumor necrosis factor (TNF)- α agents are limited in the case of

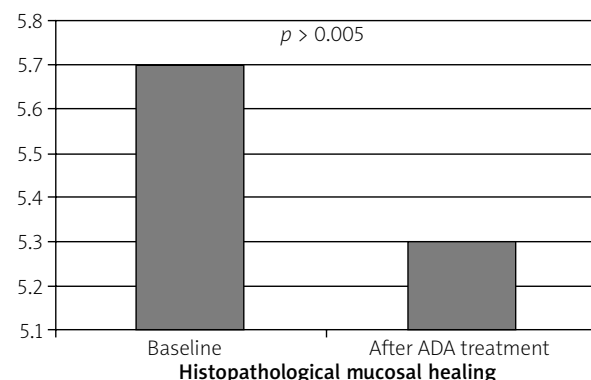


Figure 3. Impact of ADA on histopathological mucosal healing: no statistically significant decrease in histological score was reported (5.7 (0.0–15.0) vs. 5.3 (0.0–15.0))

paediatric CD. This study was the first one to assess the impact of biological therapy with ADA therapy on both endoscopic and histopathological mucosal healing in children with CD. Although there is no universally accepted definition of MH, in most trials as well as in clinical practice, it is defined as a complete absence of ulcers or a significant decrease in SES-CD. There is also no established standard for MH on histopathological examination. Moreover, it has been demonstrated that gross endoscopic healing on ileocolonoscopy may not be paralleled in histopathology [17]. Besides, no standardised histopathological scoring system exists for CD, and there is variation in the interpretation of pathologists. Therefore, we decided to develop a self-adapted numerical scoring system for CD, based on the score of 0–3 of the following five segments of intestine: ileum, right colon, transverse colon, left colon, and rectum. We are aware of certain limitations of that method. First of all, the scale has not been validated, and secondly, a patchy pattern of inflammation in CD makes microscopic evaluation difficult. Nonetheless, we assumed that a numerical system would be more clear and better reflect histological changes than a traditional descriptive protocol. Our results have shown that mucosal healing correlated better with clinical remission than MH on histopathological examination, and endoscopic MH was not necessarily associated with histopathological remission. It may be explained by the fact that superficial endoscopic changes heal easier, thus remission on ileocolonoscopy is achieved sooner than the microscopic one. It takes more time to suppress deep histopathological inflammation, and a common situation is that although a patient enters clinical remission and has macroscopic MH on endoscopic examination, there is still no or little microscopic improvement.

Recently, a retrospective centre study to evaluate the safety and efficacy, in terms of endoscopic, clinical, and laboratory response of IFX (29/33 patients) and ADA (29/33 patients) in a cohort of paediatric patients with CD has been published. With regard to ADA therapy, 25% of patients achieved mucosal healing and 50% showed an endoscopic response [18]. In our study comparable results were noted: 17.4% children had complete mucosal healing, and endoscopic response was reported in 65.5% of patients. Additionally, we demonstrated that a switch from a first anti-TNF- α agent to a second anti-TNF- α agent had no significant impact on either endoscopic or histopathological MH, which is consistent with the previously published findings from other authors [19]. When comparing outcomes of IFX therapy to ADA treatment in our patients, we observed slightly worse results for the second ones, which may be explained by the fact that most of our switched pa-

tients presented with more severe course of disease and were qualified to ADA therapy mostly due to loss of response to IFX.

The EXTEND study, a randomised, double-blind, placebo-controlled, maintenance/withdrawal trial of ADA has demonstrated that at week 12 MH was achieved in 27% of patients receiving continuous ADA compared with 13% for the induction-only/placebo group ($p = 0.056$). The efficacy of maintenance ADA treatment was demonstrated at week 52, with 24% of patients receiving continuous adalimumab achieving mucosal healing and no patients with mucosal healing in the induction only/placebo ($p < 0.001$) [20]. This shows that greater mucosal healing is seen in patients receiving continuous ADA than in those on the induction scheme. In our study the patients received only continuous ADA, and there was no placebo/induction group, but we additionally analysed histopathological healing, which was not studied in the EXTEND trial.

To the best of our knowledge, it is the first such study conducted on a paediatric population. Nonetheless, we are aware of its limitations, such as the retrospective nature of the study and non-validated scoring system for histopathological assessments.

Conclusions

According to this study, biological therapy with adalimumab has a positive impact on endoscopic mucosal healing in paediatric patients with CD, which is not associated with histopathological evidence of suppression of inflammation. Mucosal healing on endoscopic examination correlates better than MH on histopathological examination with clinical remission.

Conflict of interest

The authors declare no conflict of interest.

References

1. Baumgart DC, Sandborn WJ. Inflammatory bowel disease: clinical aspects and established and evolving therapies. *Lancet* 2007; 369: 1641-57.
2. Hanauer SB. Inflammatory bowel disease. *N Engl J Med* 1996; 334: 841-8.
3. Benchimol EI, Fortinsky KJ, Gozdyra P, et al. Epidemiology of pediatric inflammatory bowel disease: a systematic review of international trends. *Inflamm Bowel Dis* 2011; 17: 423-39.
4. Dignass A, Van Assche G, Lindsay JO, et al. The second European evidence-based Consensus on the diagnosis and management of Crohn's disease: current management. *J Crohns Colitis* 2010; 4: 28-62.
5. Tung J, Loftus EV Jr, Freese DK, et al. A population-based study of the frequency of corticosteroid resistance and dependence in pediatric patients with Crohn's disease and ulcerative colitis. *Inflamm Bowel Dis* 2006; 12: 1093-100.

6. Ben-Horin S, Kopylov U, Chowers Y. Optimizing anti-TNF treatments in inflammatory bowel disease. *Autoimmun Rev* 2014; 13: 24-30.
7. Colombel JF, Louis E, Peyrin-Biroulet L, Sandborn WJ, Panaccione R. Deep remission: a new concept? *Dig Dis* 2012; 30: 107-11.
8. Kierkus J, Dadalski M, Szymanska E, et al. The impact of infliximab induction therapy on mucosal healing and clinical remission in Polish pediatric patients with moderate-to-severe Crohn's disease. *Eur J Gastroenterol Hepatol* 2012; 24: 495-500.
9. D'haens G, Van Deventer S, Van Hogezaand R, et al. Endoscopic and histological healing with infliximab anti-tumor necrosis factor antibodies in Crohn's disease: a European multicenter trial. *Gastroenterology* 1999; 116: 1029-34.
10. Paul S, Del Tedesco E, Marotte H, et al. Therapeutic drug monitoring of infliximab and mucosal healing in inflammatory bowel disease: a prospective study. *Inflamm Bowel Dis* 2013; 19: 2568-76.
11. Zallot C, Peyrin-Biroulet L. Deep remission in inflammatory bowel disease: looking beyond symptoms. *Curr Gastroenterol Rep* 2013; 15: 315.
12. Munkholm P, Langholz E, Davidsen M, et al. Disease activity courses in a regional cohort of Crohn's disease patients. *Scand J Gastroenterol* 1995; 30: 699-706.
13. Pimentel-Nunes P, Dinis-Ribeiro M, Magro F. Systematic review on drug and diet-induced endoscopic remission in Crohn's disease. *Eur J Gastroenterol Hepatol* 2009; 21: 491-503.
14. Korelitz BI, Sommers SC. Response to drug therapy in Crohn's disease: evaluation by rectal biopsy and mucosal cell counts. *J Clin Gastroenterol* 1984; 6: 123-7.
15. D'Haens G, Geboes K, Rutgeerts P. Endoscopic and histologic healing of Crohn's (ileo-) colitis with azathioprine. *Gastrointest Endosc* 1999; 50: 667-71.
16. Kornbluth A, Sachar DB. Ulcerative colitis practice guidelines in adults (update): American College of Gastroenterology, Practice Parameters Committee. *Am J Gastroenterol* 2004; 99: 1371-85.
17. Geboes K, Dalle I. Influence of treatment on morphological features of mucosal inflammation. *Gut* 2002; 50 (Suppl 3): III37-42.
18. Nobile S, Gionchetti P, Rizzello F, et al. Mucosal healing in pediatric Crohn's disease after anti-TNF therapy: a long-term experience at a single center. *Eur J Gastroenterol Hepatol* 2014; 26: 458-65.
19. Beigel F, Deml M, Schnitzler F, et al. Rate and predictors of mucosal healing in patients with inflammatory bowel disease treated with anti-TNF-alpha antibodies. *PLoS One* 2014; 9: e99293.
20. Rutgeerts P, Assche GV, Sandborn WJ, et al. Adalimumab induces and maintains mucosal healing in patients with Crohn's disease: data from the EXTEND trial. *Gastroenterology* 2012; 142: 1102-11.

Received: 27.07.2015

Accepted: 24.10.2015