

# Carcinoid tumour of the oesophagus: a systematic review

Mazaher Ramezani<sup>1</sup>, Masoud Sadeghi<sup>2,3</sup>

<sup>1</sup>Molecular Pathology Research Centre, Emam Reza Hospital, Kermanshah University of Medical Sciences, Kermanshah, Iran

<sup>2</sup>Medical Biology Research Centre, Kermanshah University of Medical Sciences, Kermanshah, Iran

<sup>3</sup>Students Research Committee, Kermanshah University of Medical Sciences, Kermanshah, Iran

Gastroenterology Rev 2018; 13 (3): 196–199

DOI: <https://doi.org/10.5114/pg.2018.78285>

**Key words:** neuroendocrine tumour, carcinoid tumour, oesophagus.

---

**Address for correspondence:** Masoud Sadeghi MSc, Medical Biology Research Centre, Kermanshah University of Medical Sciences, 67145-1673 Kermanshah, Iran, phone: +98 9188566877, e-mail: [sadeghi\\_mbrc@yahoo.com](mailto:sadeghi_mbrc@yahoo.com)

## Abstract

**Introduction:** Knowledge about oesophageal carcinoids is based primarily on case reports, and therefore information about them is incomplete.

**Aim:** To collect information on oesophageal carcinoid tumours in a systematic review study.

**Material and methods:** Databases including PubMed, Scopus, and Web of Science were searched for the characteristics of oesophageal carcinoid tumour. Studies included original articles, case series, or case reports, reporting at least one of the characteristics of benign carcinoid tumour or carcinoid tumour.

**Results:** Out of 670 studies searched, after evaluation and excluding non-relevant studies, 14 studies were included and analysed in the systematic review. These studies included 19 patients with carcinoid tumour of whom 57.9% were males with a mean age of 55.5 years. Dysphagia and weight loss were the most prevalent symptoms and signs in the patients. Lower oesophagus was the most prevalent site of tumour.

**Conclusions:** This meta-analysis showed that the mean age at diagnosis of oesophageal carcinoid was around 55 years, with 1.4 times greater prevalence among males, and located mainly in the distal oesophagus. The mean tumour size was 2.4 cm. The main symptoms and signs of this disease were dysphagia, weight loss, and reflux. The tumour behaviour was mainly non-aggressive except for cases associated with adenocarcinoma.

## Introduction

Endocrine tumours of the gastrointestinal tract, which are known as carcinoids, herein collectively termed neuroendocrine tumours (NETs), originate from the diffuse neuroendocrine cell system [1]. Typical carcinoid, atypical carcinoid, small cell neuroendocrine carcinoma, and large cell neuroendocrine carcinoma are subgroups of neuroendocrine tumours [2]. The traditional term of carcinoid is not adequate to cover all NETs [3]. Over 90% of all carcinoid tumours originate in the gastrointestinal tract, and most carcinoid tumours are gastrointestinal in origin, but they only account for 1.5% of all gastrointestinal neoplasms [4]. Neuroendocrine tumours of the oesophagus are very rare and represent only 0.05% of all gastrointestinal NETs [5] and therefore are one of the rarest of all carcinoid tumours [6]. Brenner *et al.* were the first researchers to describe a carci-

noid originating within the oesophagus [7]. Diagnosis of oesophageal carcinoid can be suggested by barium meal, endoscopy with biopsy, and computed tomography scanning [3]. Nowadays, somatostatin analogues play a fundamental role in the treatment of NETs of the gastrointestinal tract [8]. Because knowledge about oesophageal carcinoid is based primarily on case reports, the treatment of choice has not been established [6, 9]. We found a lack of adequate basic data about oesophageal carcinoid even in reference books such as Robbins and Cotran Pathologic Basis of Disease [10] or Odze & Goldblum Surgical Pathology of the GI Tract, Liver, Biliary Tract, and Pancreas [11].

## Aim

Based on this vague and incomplete information, we aimed to collect information on oesophageal carci-

noid tumours in a systematic review study. We used the term carcinoid for typical carcinoid tumours or well-differentiated neuroendocrine tumours.

## Material and methods

### Search strategies

Three databases (PubMed, Scopus, and Web of Science) were searched for the characteristics of carcinoid tumour of oesophagus using the term “carcinoid” combined with “oesophageal” for publications with English abstracts.

### Study selection

One author (M.S) searched the studies, and then a second author (M.R) who was blinded to the first author. The disagreement between two authors was resolved with a two-way conversation. Studies included: 1) original articles, case series, or case reports; 2) reporting at least one of the characteristics of benign carcinoid tumour or carcinoid tumour.

### Data extraction

Name of first author, year of publication, number of patients, age, sex, tumour size, tumour behaviour, signs and symptoms; tumour site, and additional findings were extracted for every study.

## Results

Out of 670 studies searched, 18 studies were assessed for eligibility. Four studies were excluded, and therefore 14 studies [4, 6, 7, 9, 12–21] were included and analysed in the systematic review (Figure 1).

Fourteen studies from 1968 to 2016 included 19 patients with carcinoid tumour; 11 (57.9%) patients were male and 8 (42.1%) patients were female (Table I). The mean age at diagnosis was 55.5 years (range: 26–82 years). The mean tumour size was 2.44 cm (range: 0.3–12 cm). Out of nine studies reporting behaviour of the tumour, six studies (66.7%) had non-aggressive behaviour. Out of 11 studies reporting signs of tumour, six (54.5%), four (36.4%), three (27.3%), one (9%), one (9%), one (9%), and one (9%) cases had a history of dysphagia, weight loss, heartburn, lassitude and fatigue, gastrointestinal bleeding, epigastric soreness, and no symptoms, respectively. Out of 15 cases reporting the tumor site, the lower oesophagus was in 12 (80%), the upper oesophagus in 2 (13.3%), and the middle oesophagus in one (6.7%).

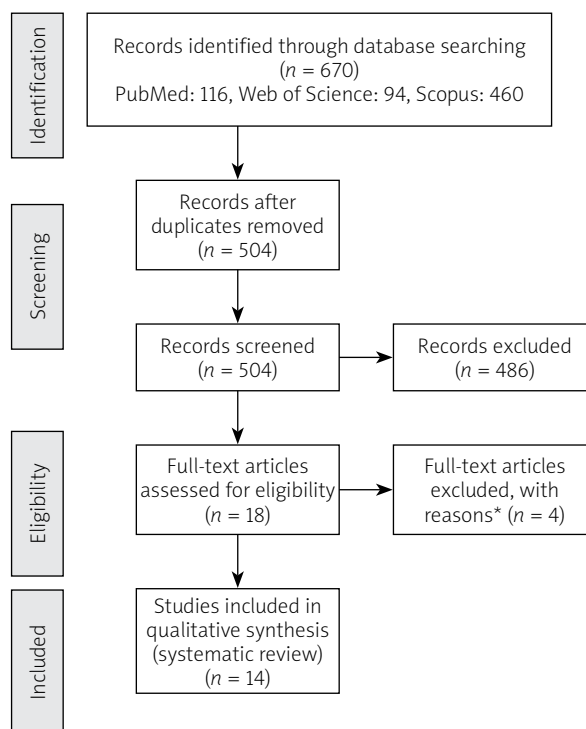
## Discussion

This study reported a number of characteristics of oesophageal carcinoid that were ambiguous in reference books and sources. A review in early 2017 included

a total of 1574 oesophageal cancers; 14 (0.89%) were cases of neuroendocrine neoplasm and 1/14 (7.1%) had oesophageal carcinoid [2]. Hoang *et al.* [6] included 13 patients who were diagnosed as upper gastrointestinal carcinoid tumours, of which just 1 (7.7%) patient had oesophageal carcinoid, and in another study this figure was 7.9% [22].

Lindberg *et al.* [3] concluded that most NET patients are male, mainly in the sixth to seventh decade of life. Neuroendocrine tumours of the oesophagus are typically located in the distal half of the organ. They show no special hormonal syndrome, but present with clinical features that are also common to the other types of oesophageal cancer, i.e. dysphagia, severe weight loss, and sometimes chest pain [1]. The NET tumours are usually of large size (> 4 cm) [3].

Studies reported before 1990 showed that oesophageal carcinoid usually occurs in the lower oesophagus, with a male-to-female ratio of 6 : 1 [23, 24], who presented most commonly with dysphagia, weight loss, pain, reflux esophagitis, fatigue, and melanotic stools. This study reported that the age at diagnosis of oesophageal carcinoid ranged from 30 to 82 years [23]. Lesions of oesophageal carcinoids are typically large, polypoid, and confined to the submucosa or lamina propria [25]. In one of the reference books [11] it was mentioned



**Figure 1.** Flowchart of the systematic review study

\*4 studies were review.

**Table I.** Characteristics of the studies included in the review ( $n = 14$ )

First author, year	Number of patients	Age	Sex	Size of tumour [cm]	Behavior of tumour	Additional findings	Signs and symptoms	Tumour site
Brodman, 1968	1	66	F	–	Aggressive	–	–	Lower
Brenner, 1969 [7]	1	56	M	–	Aggressive	–	17-week history of severe dysphagia and weight loss	Lower
Chong, 1979 [12]	1	55	M	2	–	Mucin-producing adenocarcinoma	1-month history of dysphagia	Upper
Rankin, 1980 [13]	1	54	M	12	–	–	4-month history of progressive dysphagia and 14-lb weight loss	Lower
Cary, 1993 [14]	1	57	M	–	–	Adenocarcinoma	20-year history of heartburn with a 3-month history of lassitude and fatigue	Lower
Partensky, 1993 [15]	1	64	M	4	Non-aggressive	–	Dyspepsia and episodic dysphagia	Lower
Hauser, 1995 [16]	3	Mean: 48	F	–	–	–	–	–
Tanida, 1998 [17]	1	63	M	1.1	–	–	–	Lower
Hoang, 2002 [6]	4	Mean: 63 (range: 48–82)	M: 3 F: 1	Mean: 1.5 (range: 0.3–3.5)	Non-aggressive	Adenocarcinoma: 2	Dysphagia and weight loss – dysphagia and heartburn	Lower: 2 Middle: 1 Unknown: 1
Chuah, 2005 [4]	1	26	M	0.7	Non-aggressive	–	Gastrointestinal bleeding	Lower
Kreuseler, 2010 [18]	1	77	F	1.5	Non-aggressive	–	2-month history of dysphagia and consecutive weight loss	Upper
Lim, 2013 [19]	1	49	F	0.8	Non-aggressive	–	Intermittent epigastric soreness and heartburn	Lower
Yagi, 2015 [20]	1	43	F	0.3	Non-aggressive	–	–	Lower
Kim, 2016 [9]	1	56	M	0.5	Non-aggressive	–	–	Lower

that carcinoid tumours are uncommon in the oesophagus, and these cases showed a male predominance, and most of them were distal, particularly at the gastro-oesophageal junction. Fifty per cent of them were metastatic at the time of diagnosis.

This disease is very rare, and therefore the number of reported patients is low in the present study. In the literature the definition of carcinoid in the studies was different.

## Conclusions

This meta-analysis showed that the mean age at diagnosis was 55.5 years (range: 26–82 years). The tumour was around 1.4 times more prevalent in males and located mainly in the distal (lower) oesophagus. The mean tumour size was 2.4 cm (range: 0.3–12 cm) and the most tumours were non-secretor. The main

symptoms of this disease were dysphagia, weight loss, and reflux. The tumour behaviour was mainly non-aggressive except for cases associated with adenocarcinoma.

## Conflict of interest

The authors declare no conflict of interest.

## References

1. Klöppel G, Anlauf M. Epidemiology, tumour biology and histopathological classification of neuroendocrine tumours of the gastrointestinal tract. *Best Pract Res Clin Gastroenterol* 2005; 19: 507-17.
2. Tustumi F, Takeda FR, Uema RH, et al. Primary neuroendocrine neoplasm of the oesophagus – report of 14 cases from a single institute and review of the literature. *Arq Gastroenterol* 2017; 54: 4-10.

3. Lindberg GM, Molberg KH, Vuitch MF, et al. Atypical carcinoid of the oesophagus. A case report and review of the literature. *Cancer* 1997; 79: 1476-81.
4. Chuah SK, Hu TH, Kuo CM, et al. Upper gastrointestinal carcinoid tumours incidentally found by endoscopic examinations. *World J Gastroenterol* 2005; 11: 7028-32.
5. Modlin IM, Sandor A. An analysis of 8305 cases of carcinoid tumours. *Cancer* 1997; 79: 813-29.
6. Hoang MP, Hobbs CM, Sobin LH, et al. Carcinoid tumour of the oesophagus: a clinicopathologic study of four cases. *Am J Surg Pathol* 2002; 26: 517-22.
7. Brenner S, Heinlich H, Widman M. Carcinoid of oesophagus. *New York J Med* 1969; 69: 1337-9.
8. Kos-Kudła B. Treatment of neuroendocrine tumours: new recommendations based on the CLARINET study. *Contemp Oncol (Pozn)* 2015; 19: 345-349.
9. Kim NR, Kim YJ, Hwang IC. A carcinoid tumor of the esophagus treated with endoscopic ablation therapy. *J Nepal Med Assoc* 2016; 55: 97-9.
10. Robbins and Cotran Pathologic Basis of Disease. 9<sup>th</sup> ed. Kumar V, Abbas AK, Aster JC (eds.). Elsevier Saunders, Philadelphia 2015; 774.
11. Odze RD, Goldblum JR. Surgical Pathology of the GI Tract, Liver, Biliary Tract and Pancreas. 3<sup>rd</sup> ed. Elsevier Saunders, Philadelphia 2015; 813-4.
12. Chong FK, Graham JH, Madoff IM. Mucin-producing carcinoid ("composite tumour") of upper third of oesophagus: a variant of carcinoid tumour. *Cancer* 1979; 44: 1853-9.
13. Rankin R, Nirodi NS, Browne MK. Carcinoid tumour of the oesophagus: report of a case. *Scott Med J* 1980; 25: 245-9.
14. Cary NR, Barron DJ, McGoldrick JP, et al. Combined oesophageal adenocarcinoma and carcinoid in Barrett's oesophagitis: potential role of enterochromaffin-like cells in oesophageal malignancy. *Thorax* 1993; 48: 404-5.
15. Partensky C, Chayvialle JA, Berger F, et al. Five-year survival after transhiatal resection of oesophageal carcinoid tumour with a lymph node metastasis. *Cancer* 1993; 72: 2320-2.
16. Hauser H, Wolf G, Uranüs S, et al. Neuroendocrine tumours in various organ systems in a ten-year period. *Eur J Surg Oncol* 1995; 21: 297-300.
17. Tanida S, Miyamoto T, Katagiri K, et al. Carcinoid of the oesophagus located in lamina propria. *J Gastroenterol* 1998; 33: 541-5.
18. Kreuseler T, Stolte M, Adamek RJ. Neuroendocrine tumour of the oesophagus – successful endoscopic treatment of a very rare entity. *Dtsch Med Wochenschr* 2010; 135: 19-21.
19. Lim CS, Park SJ, Park MI, et al. Successful endoscopic mucosal resection of a low oesophageal carcinoid tumour. *Clin Endosc* 2013; 46: 576-8.
20. Yagi M, Abe Y, Sasaki Y, et al. Esophageal carcinoid tumour treated by endoscopic resection. *Dig Endosc* 2015; 27: 527-30.
21. Estrozi B, Bacchi CE. Neuroendocrine tumours involving the gastroenteropancreatic tract: a clinicopathological evaluation of 773 cases. *Clinics (Sao Paulo)* 2011; 66: 1671-5.
22. Broicher K, Hienz HA. Karzinoid-Syndrom bei im Oesophagus lokalisiertem Primartumor. *Z Gastroenterol* 1974; 12: 377-84.
23. Griffin M, Sweeney EC. The relationship of endocrine cells, dysplasia and carcinoembryonic antigen in Barrett's mucosa to adenocarcinoma of the oesophagus. *Histopathology* 1987; 11: 53-62.
24. Ready AR, Soul JO, Newman J, et al. Malignant carcinoid tumour of the oesophagus. *Thorax* 1989; 44: 594-6.
25. Adsay NV, Klimstra DS. Neuroendocrine tumors of the gastrointestinal and pancreatobiliary tracts. In: *Surgical Pathology of GI Tract, Liver, Biliary Tract and Pancreas*. 3<sup>rd</sup> ed. Odze RD, Goldblum JR (eds). Elsevier; Philadelphia, PA, USA 2015; 803-20.11.

**Received:** 25.08.2017

**Accepted:** 4.01.2018