

Bronchobiliary fistula. Endoscopic management

Andrzej Modrzejewski¹, Tomasz Tereszczuk², Marek Buszkiewicz², Paweł Chęciński³, Andrzej Dmytrzak⁴, Martin Inman²

¹Pomeranian Medical University, Szczecin

²Department of General Surgery, Provincial Hospital, Gorzów Wielkopolski

³Medical University of Poznań

⁴Aestheticmed, Szczecin

Videosurgery and other miniinvasive techniques 2009; 4 (2): 83–87

Abstract

Bronchobiliary fistula is an infrequent condition, and there is no consensus on the most effective methods of diagnosis and treatment. The authors present two cases of bronchobiliary fistula. The suspicion of a fistula was made on bronchoscopy examination, when bile was found within the bronchial tree. Examination of a sample taken from the bronchial tree proved to contain bilirubin. In both patients, a complicated abscess of the right lobe of the liver caused bronchobiliary fistula. The abscess had developed due to a disturbance in the outflow of bile (purulent inflammation of the bile ducts due to a bile stone and scarring of the ampulla of Vater). A final diagnosis can be established with endoscopic retrograde cholangio-pancreatography. During endoscopy, a stent was placed in the right hepatic duct. Two months later a control endoscopic retrograde cholangio-pancreatography examination was performed. No leakage of contrast agent from the biliary ducts into the bronchial tree was found and the stent was removed. Endoscopic retrograde cholangio-pancreatography and procedures made during this examination are an up-to-date method of treatment of bronchobiliary fistula.

Key words: bronchobiliary fistula, endoscopic retrograde cholangiopancreatography.

Introduction

Bronchobiliary fistula is a condition where bile leaks out from the biliary tract into the bronchial tree. The disease is very infrequent. Usually, it is a congenital state or complicates severe abdominal and thoracic trauma. Other causes include liver and infrahepatic abscesses. Bronchobiliary fistula occurs in 4% of liver abscesses and 10% of infrahepatic abscesses [1]. Another condition which may lead to bronchobiliary fistula is hydatid cyst. Disturbances in bile flow can also be a causative factor. Chronic pancreatitis can result in tissue cicatrization with common bile duct

constriction and formation of a fistula [2]. Other origins were post-operative complications after biliary, pancreatic and gastric surgery or after liver transplantation [3]. Also, a fistula in liver cirrhosis was described [4]. There are only exceptional reports on bronchobiliary fistula in Polish literature, with only 2 cases described [5]. In the first case, the fistula developed after cholecystectomy with extrahepatic bile duct drainage. In another, it was a complication of traumatic liver rupture with subphrenic abscess formation.

The aim of this study was to present our experience in treatment of this rare condition in relation to the literature data.

Address for correspondence

Andrzej Modrzejewski, 21bc Wierzbowa St 3, 71-025 Szczecin, phone 609 503 130, e-mail amodrzejewski@interia.pl

Case reports

Case I

In a 46-year old male treated in a surgical ward of another hospital (3 Apr 2008 – 11 Apr 2008) a 76 mm abscess of the right liver lobe was diagnosed on abdominal ultrasound. Seven years earlier, the patient suffered from acute pancreatitis complicated by pseudocyst, which was treated with Roux-en-Y internal drainage into the small bowel a year later. He was treated for 5 years for diabetes and two years earlier was treated for Hodgkin lymphoma with chemotherapy and radiotherapy of the extraperitoneal lymph nodes and spleen.

After admission to the surgical department, the liver lesion was punctured through the intercostal space, under ultrasound guidance and local anaesthesia, and pus was aspirated. A 9F pigtail drain was introduced into an abscess. Pus was cultured and *Escherichia coli* and *Streptococcus anginosus* were cultivated. Ciprofloxacin was administered and drainage was removed 7 days after discharge from hospital. On 28 Apr 2008 the patient was admitted to the department of pulmonology of another hospital for pneumonia. Chest X-ray revealed right dome of the diaphragm at the level of the 4th intercostal space, while left dome remained at the 6th. Opacity above the right diaphragm suggestive of pleural effusion was also seen. First abdominal ultrasound found heterogeneous, normoechoic and enlarged liver with two hypoechoic lesions of 48 and 43 mm located subphrenically. Subsequent ultrasonic examinations however did not confirm the presence of an abscess. Ten-millimetre thick fluid collection was found in the right posterior costodiaphragmatic recess and 35 mm hypoechoic (fluid?) space was discovered in the anterior one. In the left posterior recess, a layer of 5 mm effusion was found. Thoracic CT scan with intravenous contrast, backed with HRCT scans, confirmed elevated position of the right dome of the diaphragm. A peripheral lesion of 20-85 HU density adjacent to the parietal pleura was found at the level of the 8th and 9th left lung segments. The 50 × 70 mm lesion had a rough, pitted contour suggestive of empyema or cancer. At the same scan level, dense fluid of 20 HU, 20 mm thick was also noticed. The lesion infiltrated the diaphragm and subphrenic segments of the liver. Lymph nodes

neighbouring the carina were enlarged to 8-12 mm. Ceftriaxone and metronidazole were administered and clinical improvement was noted. Control X-ray showed some resolution of the findings located above the right dome. On May 16th, the patient was transferred to the thoracic surgery department, where he stayed until 20 May 2008. Guided aspiration of the right pleura was tried, with no material obtained. The patient was then asymptomatic and chest X-ray showed some improvement. On June 9th the patient was readmitted to the department of thoracic surgery for fever, dyspnoea, and exhausting cough productive of yellow-stained sputum. Diffuse opacity covered the lower lobe of the right lung on chest radiograph. The right dome of the diaphragm could not be identified and soft consolidations were seen in the upper and middle lobe. Right-sided non-homogeneous pleural effusion, up to 28 mm thick in the anterior recess, was found on ultrasound examination. The liver was enlarged, with 21 mm fluid collection below the diaphragm within the right lobe. On bronchofibroscopy, no pathology was found in the trachea, carina and bronchial tree. However, yellow-coloured discharge was found in the bronchi, which was continuously leaking in spite of aggressive rinsing. Lab tests of the bronchoalveolar lavage discovered presence of bilirubin. The patient was administered clindamycin, amikacin and cipro-floxacin with clinical improvement. On 16 June 2008, the patient was transferred to our department. Endoscopic retrograde cholangiopancreatography (ERCP) was performed with contrast accumulation outside the biliary tree in the subdiaphragmatic region and leakage into the bronchial tree of the right lung. Cicatrization of the ampulla of Vater was also found, so papillotomy was performed and an endoprosthesis was placed in the right hepatic duct. Bronchobiliary fistula was confirmed with computed tomography immediately after ERCP (Figure 1). Coughing and expectoration receded within two days. Endoscopic retrograde cholangiopancreatography was repeated 2 months later and showed no leak of the contrast media into the bronchial tree. The endoprosthesis was removed.

Case II

Another patient, 51 years old, was treated in the surgical department of another hospital from

25 July to 31 July 2008. He had undergone open cholecystectomy for acute cholecystitis. No gallstones were found. Two days later, he presented with obstructive jaundice, fever and inflammation in the right lumbar region. The patient was transferred to our department. On admission, he complained of dyspnoea and cough. His core temperature was 38.6°C and the skin was jaundiced. Inflammatory infiltrate of the skin and subcutaneous tissue was seen in the right lumbar region. Gallstones were found in the biliary tree on ultrasound. Chest X-ray showed zonal opacity from atelectasis and pneumonia. Bilateral pleural effusion was also found, up to the 7th rib level in the right midaxillary line. White blood count was 16 G/l, serum bilirubin 9 mg/dl, alanine aminotransferase activity 282 U/l, aspartate aminotransferase 198 U/l, and alkaline phosphatase 337 U/l. Endoscopic retrograde cholangiopancreatography was performed. Ampulla of Vater was found at the edge of the deep diverticulum. Three 4-5 mm gallstones in the common bile duct and pyogenic discharge from the biliary tree were found. Cholangitis due to choledocholithiasis was diagnosed. Papillotomy was performed and biliary stones were removed. Intensive respiratory rehabilitation was implemented. The patient's condition improved slightly, but cough and fever did not withdraw. Computed tomography showed pneumonia and atelectasis in the lower lobe of the right lung with pleural effusion, and an abscess of the right liver lobe adjacent to the diaphragm. Ultrasound-guided percutaneous drainage of an abscess was performed with aspiration of 600 ml of pus. Inflammation in the lumbar region receded, but fever and cough persisted. Percutaneous, ultrasound guided drainage of the right pleural cavity was instilled and continued for a few consecutive days. No bacterial colonization of the effusion was found. Liver abscess was rinsed with saline and targeted antibiotics were administered; however, no clinical improvement was seen. Bronchoscopy was performed, with yellowish discharge found bilaterally. Lab tests of the bronchoalveolar lavage confirmed the presence of bilirubin. Consecutive ERCP revealed a bronchobiliary fistula between the right liver lobe biliary tree and the right lung. Endoscopic papillotomy was done and an endoprosthesis was placed in the right hepatic duct. Fever dropped off and the cough receded gradually. The patient was

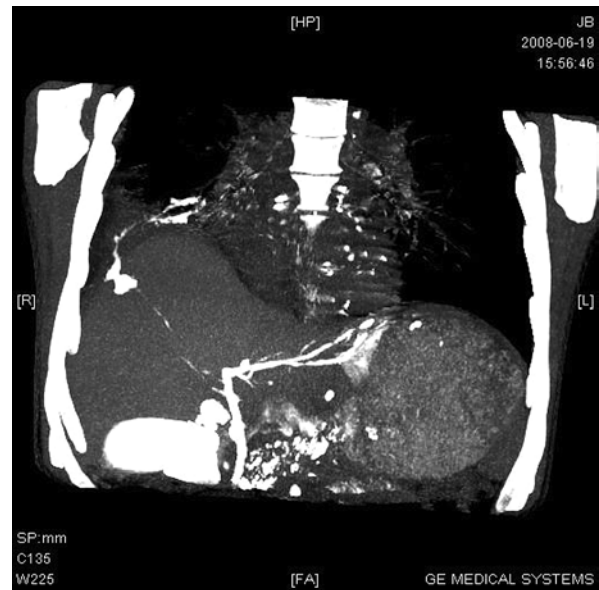


Figure 1. Computed tomography performed immediately after ERCP endoprosthesis placement in the right hepatic duct and radiopaque contrast injection. Leakage of contrast from the biliary tree into pleural cavity and bronchial tree is visible

discharged after a month. Control ERCP after 2 months did not show any signs of bronchobiliary fistula and the endoprosthesis was removed from the bile ducts.

Discussion

Similarly to reports by other authors, causes of bronchobiliary fistula in our patients were also pyogenic liver diseases: liver abscess in one case and cholangitis in another. It is difficult to explain why symptoms of the fistula, i.e. expectoration of bile, developed only after liver abscesses and the pleurae were drained. There are insufficient data to support iatrogenic origin of the fistula. Residual choledocholithiasis following cholecystectomy was a causative factor in the second case.

Coughing up of bile is a typical manifestation of a bronchobiliary fistula. Lobar bronchopneumonia is common. Other symptoms include jaundice and pain in the right hypochondrium. Fistula is often accompanied by cholangitis and subphrenic abscess [6]. Nevertheless, problems with making a correct diagnosis are common [6], which was also the case in

our patients. On chest radiograph, lower lobe pneumonia was usually seen. Similar findings were discovered in our patients. Radiological features are not characteristic of bronchobiliary fistula and usually do not lead to final diagnosis. Scintigraphy, percutaneous transhepatic cholangiography, Kehr drainage cholangiography or fistulography if an external fistula is present, all provide additional information [6]. Magnetic resonance cholangiography can also prove helpful [7]. Some authors deny the usefulness of bronchoscopy and bronchography [6]. In our patients however, bronchoscopy was an important technique for establishment of diagnosis. In the first case it was performed for exhausting cough and dyspnoea, while fever and accompanying cough were indications in another patient. It was bronchoscopy which revealed yellowish discharge in the bronchial tree; bronchoalveolar lavage was performed and presence of bilirubin was confirmed in a subsequent lab test. Fiberoptic examination may also be helpful in planned thoracic surgery.

We agree with other authors that ERCP is the most important diagnostic test when bronchobiliary fistula is suspected [8-13]. When diagnosis is still uncertain, immediate CT following ERCP is recommended. This strategy was implemented in both our patients. Combination of the two methods allows for definite diagnosis, which is advocated by all authors before beginning any treatment. Some authors, however, give up ERCP and percutaneous transhepatic cholangiography [7, 14], relying solely on physical examination and chest X-ray before surgical exploration. Treatment of bronchobiliary fistula is difficult, usually prolonged and can be associated with a substantial complication rate and mortality. The majority of the available literature presents traditional surgical methods of intervention. Two main techniques have been used: from the thoracic access and via laparotomy. Surgeons, who prefer thoracotomy, usually perform lung lobectomy or segmentectomy, open the diaphragm and correct the hepatic lesions [7, 14-16]. A publication summarizing treatment of 63 patients with bronchobiliary fistula from hydatid cyst reported that 47 patients were treated with lung resection, 16 with lung decortication, 51 underwent complete cyst resection and 12 partial. Only in 4 patients was thoracotomy supplemented with laparotomy [14]. Treatment of bronchobiliary fistula through abdominal access usually consists of two stages [6]. First, biliary drainage and evacuation of an abscess are achieved.

Secondly, bile outflow was corrected, most frequently with choledocho-jejunal Roux-en-Y drainage [2, 6]. In patients with irreversible damage of lung parenchyma or bronchi, and in patients with post-traumatic fistula without bile flow disturbances, resection of the right lung lower lobe can be necessary [6]. This treatment modality necessitates numerous surgical procedures to be performed in some patients. For instance, 16 patients with bronchobiliary fistula underwent 42 surgical operations [6]. Due to the extent of surgery and its character, such therapy is associated with a substantial number of complications, from 14 to 30% [14, 16]. Biliary fistulas and progression of pulmonary changes are the most frequent ones [16]. Post-operative mortality is 7-13% [14, 16]. Such inferior results lead to a search for methods of treatment other than conventional surgery. There are unique notions on the possibility of laparoscopic treatment of bronchobiliary fistula [17]. Percutaneous, transhepatic biliary drainage is performed more often [18-20]. Sometimes such drainage is accompanied by dilation of the narrowed common bile duct and placement of a self-expanding endoprosthesis (stent) [18] or stent graft [20]. Additional percutaneous drainage of the pleural empyema and liver abscess is often needed [19].

Endoscopic retrograde cholangiopancreatography and endoscopic therapy are used more often. They are aimed at facilitating bile outflow from extrahepatic bile ducts, as in other types of biliary fistula [21]. Endoscopic papillotomy is thought to play a crucial role. If bile outflow is impaired by gallstones, they ought to be removed on endoscopy [12, 13]. One of our patients underwent such a procedure. If endoscopic papillotomy is not effective, nasobiliary drainage can be implemented [9]. Placement of the endoprosthesis in the biliary tree is much more effective and better tolerated [8, 10, 11, 21]. In both our patients papillotomy could have been done and spontaneous closure of the bronchobiliary fistula could have been awaited. However, we decided that supplementation of papillotomy with placement of an endoprosthesis is safer and more effective. We did it mostly for clinical presentation of biliary fistula in our patients, its prolonged course and progression.

Conclusions

1. Suspicion of a bronchobiliary fistula requires endoscopic retrograde cholangiopancreatography.

2. Endoscopic papillotomy is a crucial step of fistula treatment, which can be supplemented with placement of the prosthesis in the biliary tract.
3. Endoscopic methods often need to be combined with percutaneous drainage of perihepatic fluid collections.

References

1. Ochsner A, De Bakey ME. Subphrenic abscess, collected review and analysis of 3608 collected and personal cases. *Int Abstr Surg* 1938; 66: 292-319.
2. Eck BD, Passinault WJ. Bronchobiliary fistula. A rare complication of chronic pancreatitis. *Int J Pancreatol* 1996; 20: 213-6.
3. Yeatman CF, Fisher RA, Carucci LR, Halvorsen RA. Bronchobiliary fistula after liver transplantation. *J Comput Assist Tomogr* 2004; 28: 717-20.
4. Jamal Y, Tombazzi C, Waters B, Ismail MK. Bronchobiliary fistula in a cirrhotic patient: a case report and review of the literature. *Am J Med Sci* 2008; 335: 315-9.
5. Modrzejewski T. Dwa przypadki przetoki oskrzelowo-żółciowej. *Pol Tyg Lek* 1956; 16: 703-5.
6. Gugenheim J, Ciardullo M, Traynor O, Bismuth H. Bronchobiliary fistulas in adults. *Ann Surg* 1988; 207: 90-4.
7. Eryigit H, Oztas S, Urek S, et al. Management of acquired bronchobiliary fistula: 3 case reports and a literature review. *J Cardiothorac Surg* 2007; 2: 52.
8. Katsinelos P, Paroutoglou G, Chatzimavroudis G, et al. Successful treatment of intractable bronchobiliary fistula using long term biliary stenting. *Surg Laparosc Endosc Percutan Tech* 2007; 17: 206-9.
9. Partrinou V, Dougenis D, Kritikos N, et al. Treatment of postoperative bronchobiliary fistula by nasobiliary drainage. *Surg Endosc* 2001; 15: 758.
10. Oettl C, Schima W, Metz-Schimmerl S, et al. Bronchobiliary fistula after hemihepatectomy: cholangiopancreatography, computed tomography and magnetic resonance cholangiography findings. *Eur J Radiol* 1999; 32: 211-5.
11. Khandelwal M, Inverso N, Conter R, Campbell D. Endoscopic management of a bronchobiliary fistula. *J Clin Gastroenterol* 1996; 23: 125-7.
12. Moreira VF, Arocena C, Cruz F, et al. Bronchobiliary fistula secondary to biliary lithiasis. Treatment by endoscopic sphincterotomy. *Dig Dis Sci* 1994; 39: 1994-9.
13. Brem H, Gibbons GD, Cobb G, et al. The use of endoscopy to treat bronchobiliary fistula caused by choledocholithiasis. *Gastroenterology* 1990; 98: 490-2.
14. Kabiri H, Chafik A, al Aziz S, et al. Treatment of hydatid bilio-bronchial and bilio-pleuro-bronchial fistulas by thoracotomy. *Ann Chir* 2000; 125: 654-659.
15. Esme H, Fidan F, Orman A, et al. A case of bronchobiliary fistula associated with subdiaphragmatic abscess after hepatic surgery. *IJTCVS* 2005; 177-9.
16. Tocchi A, Mazzoni G, Miccini M, et al. Treatment of hydatid bronchobiliary fistulas: 30 years of experience. *Liver Int* 2007; 27: 209-14.
17. Vega CG, Carbajal RA, López AJ, et al. Fistula biliobronquial manejada mediante cirugía laparoscópica. Informe de un caso. *Rev Mex Cir Endos* 2001; 2: 103-8.
18. Schwartz ML, Coyle MJ, Aldrete JS, Keller FS. Bronchobiliary fistula: complete percutaneous treatment with biliary drainage and stricture dilation. *Radiology* 1988; 168: 751-2.
19. Delande S, Goffette P, Verbaandert C, et al. Bronchobiliary fistula and cholangiocarcinoma: a case report and principles of management. *Acta Clin Belg* 2007; 62: 438-41.
20. Gandini R, Konda D, Tisone G, et al. Bronchobiliary fistula treated by self-expanding ePTFE-covered nitinol stent-graft. *Cardiovasc Intervent Radiol* 2005; 28: 828-31.
21. Jamry A, Brocki M, Santorek-Strumiłło E, Wcisło S. Endoskopowe leczenie przecieku żółci po cholecystektomii laparoskopowej – ograniczenia diagnostyczne i wybór postępowania terapeutycznego. *Wideochirurgia i inne techniki matoinwazyjne* 2007; 2: 24-8.