

Comparison of visualization of the middle ear by microscope and endoscopes of 30° and 45° through posterior tympanotomy

Emilia B. Karchier, Kazimierz Niemczyk, Adam Orłowski

Department of Otolaryngology, Medical University of Warsaw, Poland

Videosurgery Miniinv 2014; 9 (2): 276–281

DOI: 10.5114/wiitm.2014.41618

Abstract

Introduction: Endoscopic-assisted microsurgery of the middle ear enables the field of view of the surgeon to be expanded during the removal of inflammatory tissue from the tympanic cavity and during myringo- and ossiculoplasty. Canal wall up tympanoplasty with posterior tympanotomy is a gold standard in surgical treatment of chronic otitis media. Most applications of endoscopy in middle ear surgery concern exclusively the endoscopic transcanal approach.

Aim: To determine the usefulness of endoscopic visualization during the standard surgical approach through the posterior tympanotomy.

Material and methods: The study compared the visualization of the elements of the middle ear through the posterior tympanotomy by endoscopes with 30° and 45° optics and a microscope. Posterior tympanotomy was performed in eleven temporal bones. Visualization of the tympanic recesses was assessed on a subjective scale. A microscope and 30° and 45° endoscopes were used for inspection of the hypotympanum, sinus tympani, Eustachian tube, Prussak's space and footplate. Friedman ANOVA test and Dunn's multiple comparisons test were used for statistical analysis of the data.

Results: Visualization of particular recesses by endoscopes, both 30° and 45°, was excellent, while the microscopic view was statistically significantly worse, especially for sinus tympani, Prussak's space and footplate. There were no significant differences in visibility of the middle ear spaces between the two types of endoscopic optics.

Conclusions: Additional application of the endoscopes during middle ear surgery provides valuable information due to excellent visualization of key recesses usually hidden from the microscope.

Key words: middle ear cholesteatoma, tympanoplasty, middle ear ventilation.

Introduction

Endoscopic technique has been used in the middle ear for more than 20 years. Currently there are two main methods of endoscopic surgery in the middle ear:

- exclusively endoscopic transcanal tympanoplasty;
- endoscopic-assisted tympanoplasty.

Today's aspiration for minimally invasive surgery results in great interest in exclusive endoscopic surgery of the middle ear. On the other hand,

the leading otosurgical centers remain skeptical about the assumptions of this approach. The treatment of chronic otitis media is carried out by endoscopic-assisted canal wall up tympanoplasty with posterior tympanotomy. Additional use of an endoscope allows for excellent visualization of the tympanic cavity and verification of myringo- and ossiculoplasty.

Most publications are focused on endoscopic anatomy of the middle ear through the external auditory canal.

Address for correspondence:

Emilia Karchier MD, Department of Otolaryngology, Medical University of Warsaw, 1 Banacha St, 02-097 Warsaw, Poland, phone: +48 607 039 022, e-mail: emiliakarchier@op.pl

Aim

The aim of our study was to determine and compare the visibility of the particular elements of the middle ear through the posterior tympanotomy by use of a microscope and endoscopes with optics of 30° and 45°.

Material and methods

For the study were used 11 temporal bones fixed in formalin. Atticoantromastoidectomy and posterior tympanotomy were carried out under an operating microscope. Then, an evaluation of the visualization of the tympanic cavity was performed by entering the endoscope through the posterior tympanotomy. In this study we used Storz endoscopes with optics of 30° and 45° and a diameter of 2.7 mm. The view from the endoscope was obtained using the endoscopic camera and recorded through a TelePack set from Storz.

The visibility of each anatomical area was assessed for the microscope, 30° endoscope and 45° endoscope. An adopted four-grade scale was used for evaluating the visibility of particular structures. Zero meant no visibility, while three represented the situation of full visual inspection of the area.

The study determined the visibility of the following structures:

- anterior recess of epitympanum,
- eustachian tube orifice,
- footplate,
- sinus tympani,
- hypotympanum.

Statistical analysis

For statistical analysis we performed non-parametric Friedman ANOVA by ranks test because of the ordinal scale of the data. Dunn's multiple comparisons test was used to compare differences between rank sums.

Results

Visualization of the specific anatomical area of the tympanic cavity through the posterior tympanotomy is presented in the form of a graph (Figure 1).

A detailed view of all studied areas was better visible in the endoscopic optics than by microscope. Endoscopes, both 30° and 45°, provided excellent visualization of the tympanic cavity recesses, mainly due to their proximity and magnification. Visualization of the footplate, sinus tympani and Prussak's space was

statistically significantly better in the endoscopes in comparison to the microscope (Table I). However, statistical analysis revealed no significant differences in visualization of the orifice of the Eustachian tube and hypotympanum between endoscopes and microscope. There were no statistically significant differences in visualization of the recesses of the tympanic cavity between the two types of endoscopes.

Discussion

The aim of the study was to define the suitability of different endoscopes in visualization of particular anatomical areas of the middle ear by posterior tympanotomy. Previous anatomical studies showed an access via the external auditory canal [1], and more recently, an access via the Eustachian tube [2], and both of these approaches [3] in the visualization of the tympanic cavity.

A key step of canal wall up tympanoplasty is posterior tympanotomy, which allows one to perfectly visualize the tympanic cavity and remove inflammatory tissue from it. The best visualization of the recesses of the tympanic cavity is important because of the possibility of removing the inflammation, such as cholesteatoma or granulation tissue from the ear totally. Due to the widespread use of endoscopy as a method for supporting the standard surgical technique, the authors attempted to determine whether the use of endoscopy through the posterior tympanotomy would improve visualization of the tympanic cavity elements in comparison to microscope vision.

The tympanic cavity is a small air space limited by a rigid skeletal frame, and that is why both the size and the angle of rigid optics may be important for the visualization of individual elements. The size of the posterior tympanotomy restricts the insertion and manipulation of an endoscope with a diameter of 4 mm, so the authors used in the study endoscopes with a diameter of 2.7 mm. However, due to the small size of the tympanic cavity, it was supposed that the insertion of optics of higher angle would be less useful because of their property of visualizing objects located more laterally.

The authors were concerned that a wide viewing angle of 45° optics would focus on the extra-tympanic structures, but it turned out that after insertion to the tympanic cavity it proved excellent visualization of areas that are not well controlled in optical microscopy – these areas were: the footplate and

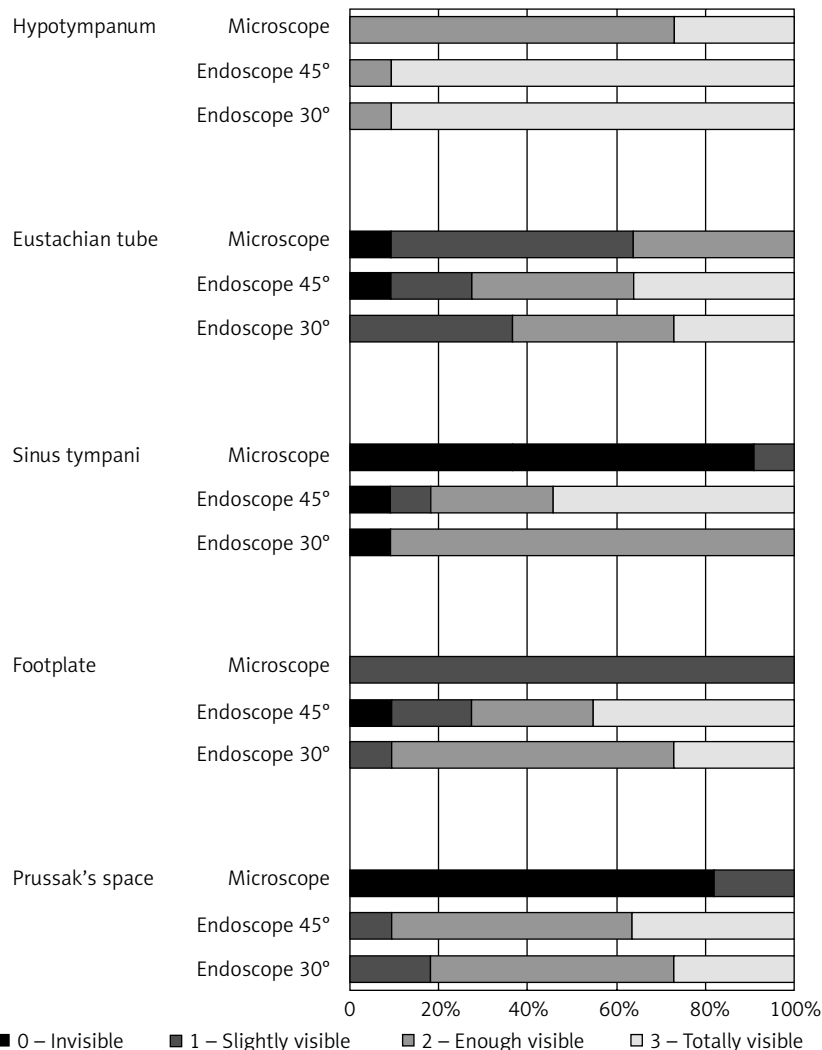


Figure 1. Comparison of visualization of the recesses of the tympanic cavity by an operating microscope and two types of endoscopes

sinus tympani located anterior to the facial nerve (Photos 1 and 2).

Also, Prussak's space, difficult to control in the operating microscope, was well visualized by both types of endoscopes (Photos 3 and 4). Similarly, both the tympanic estuary of the Eustachian tube, and hypotympanum were perfectly visible and comparable with any of the optics (Photos 5 and 6) in all tested specimens. Endoscopes inserted through posterior tympanotomy allowed for significantly better visualization of the sinus tympani, footplate and Prussak's space than is possible to gain by the operating microscope.

Currently, for the surgical treatment of chronic otitis media, endoscopy is used as a tool to support the classical surgical technique, as well as the only

instrument of visualization. Exclusively endoscopic surgery of the middle ear is actually a version of transmeatal access to the tympanic cavity. This technique involves the use of endoscopes – usually 45° – inserted into the tympanic cavity through the external auditory canal (EAC). The skin of the EAC is cut on the circumference of the annulus. After preparation of the skin of the EAC and tympanic membrane annulus, scutum and – at varying degrees – the posterior wall of the external auditory canal are removed, depending on the location and extent of cholesteatoma. This method enables access to the epitympanum and ossicular chain.

Followers of this method point out that it makes it possible to remove the main cause of chronic

otitis media in a minimally invasive way. They underline that the causes of chronic otitis media are expanded ligaments and membranous folds, which inhibit the ventilation between the epitympanum and tympanic cavity. The impediment of permeability of isthmus is the consequence of particular disorders in the tympanic cavity in fetal development. The advantages of exclusively endoscopic technique is the lack of necessity of cutting tissues behind the ear and the lack of need to perform posterior tympanotomy. On the other hand, the problem of this approach is the necessity for the surgeon or assistant to keep the endoscope, which makes the number and range of tools limited. In response to this problem there are specially designed tools that fulfill two functions, such as suction needle and raspatory [6].

This interesting application of ear endoscopy was developed by Marchioni, who used endoscopy to identify those structures which may be responsible for reducing the ventilation of the tympanic cavity and mastoid. The tensor fold separating the epitympanum from the mesotympanum and vertical fold located between the anterior and posterior recess of the epitympanum can be endoscopically visualized through the external auditory canal. This connective tissue blocking the flow of air between the tympanic cavity and epitympanum may lead to inflammation of the mucosa, even when the tubal patency is preserved. According to endoscopy followers, identification and removal of these folds blocking ventilation of the tympanic cavity enables minimally invasive casual surgery of chronic otitis media [8].

Table I. Statistical analysis of subjective visibility of recesses of tympanic cavity – comparison of visualization by endoscopes and microscope

		Rang sum difference	Value of <i>p</i>
Prusak's space			
Endoscope 30°	Endoscope 45°	1.000	> 0.05
Endoscope 30°	Microscope	17.000	< 0.001
Endoscope 45°	Microscope	16.000	< 0.01
Footplate			
Endoscope 30°	Endoscope 45°	-1.000	> 0.05
Endoscope 30°	Microscope	11.500	< 0.05
Endoscope 45°	Microscope	12.500	< 0.05
Sinus tympani			
Endoscope 30°	Endoscope 45°	-5.000	> 0.05
Endoscope 30°	Microscope	12.500	< 0.05
Endoscope 45°	Microscope	17.500	< 0.001
Eustachian tube			
Endoscope 30°	Endoscope 45°	1.500	> 0.05
Endoscope 30°	Microscope	7.500	> 0.05
Endoscope 45°	Microscope	9.000	> 0.05
Hypotympanum			
Endoscope 30°	Endoscope 45°	0	> 0.05
Endoscope 30°	Microscope	10.500	> 0.05
Endoscope 45°	Microscope	10.500	> 0.05

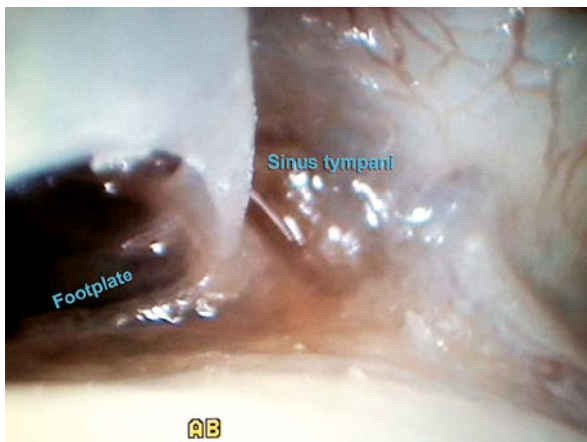

Photo 1. Sinus tympani – endoscope of 30°

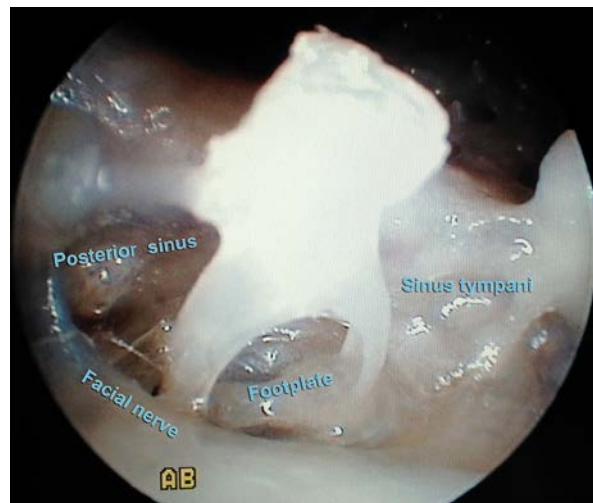


Photo 2. Sinus tympani – endoscope of 45°

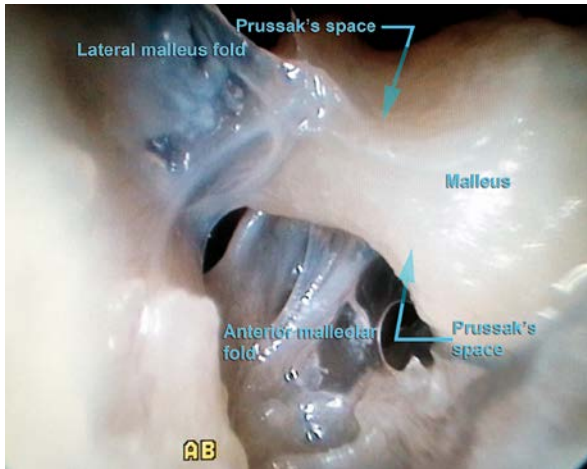


Photo 3. Anterior epitympanic space – endoscope of 30°

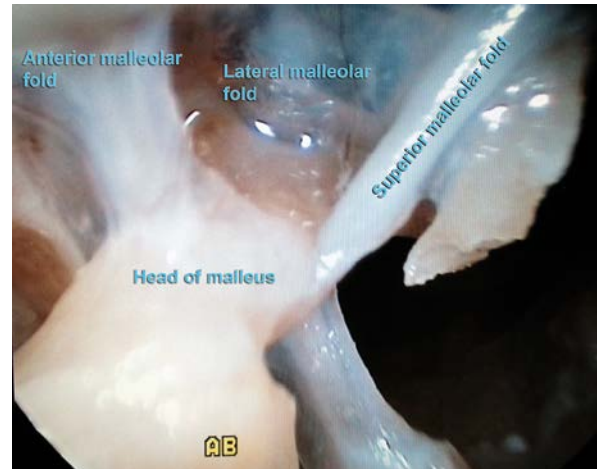

Photo 4. Anterior epitympanic space – endoscope of 45°

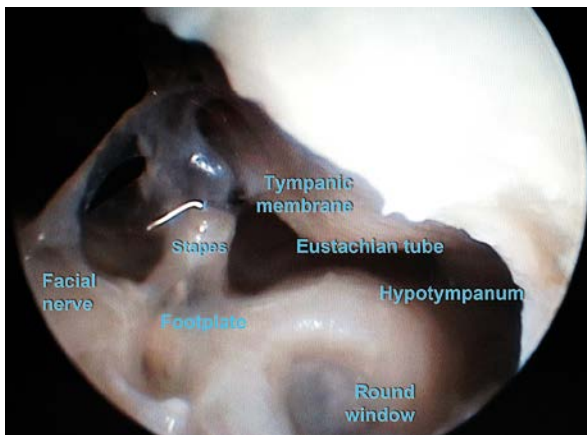


Photo 5. Hypotympanum – endoscope of 45°

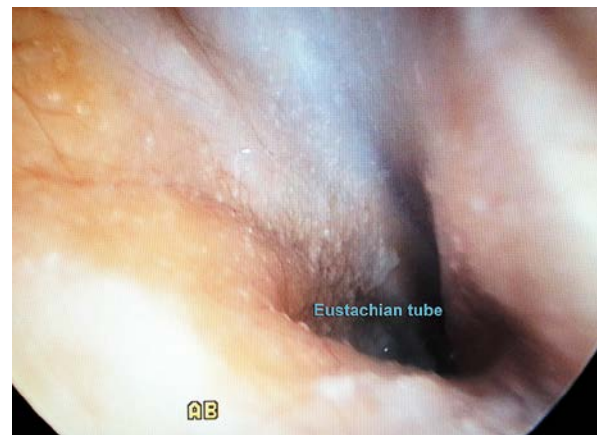

Photo 6. Eustachian tube – endoscope of 30°

For this purpose the transmeatal approach seems to be quite sufficient. However, mastoidectomy at least may be necessary for removing cholesteatoma and inflammatory bone of the mastoid. Due to the need to perform an incision behind the ear for mastoidectomy, carrying out posterior tympanotomy provides an additional point of view of the tympanic cavity. Moreover, the performance of posterior tympanotomy enables one to create an air reservoir in the mastoid widely connected with the tympanic cavity. Saving the posterior wall of the external auditory canal allows one to preserve the anatomical conditions in the EAC, which is why destroying it during an exclusively endoscopic transmeatal approach for removing cholesteatoma from the mastoid seems to be an undesirable effect, which interferes with the anatomy of the ear.

Currently, in surgery for chronic otitis media, we perform endoscopy-assisted tympanoplasty [9]. All stages of the procedure are carried out as a standard procedure by microscope with two-way access: posterior tympanotomy and by the external auditory canal. The additional use of the endoscope inserted by posterior tympanotomy enables total removal of inflammatory tissue from the recesses of the tympanic cavity and keeping control during myringo- and ossiculoplasty. In some cases, when the tympanic membrane is preserved, especially during the second-look tympanoplasty, the procedure is performed only by the posterior tympanotomy, and then the use of an endoscope further improves the visibility of the tympanic cavity structures, enabling us to find even a small remnant or recurrence of cholesteatoma, and inspect the reconstruction of the ossicular chain precisely.

The aim of the endoscopic examination in the laboratory situation was to determine optimal endoscopic optics for the tympanic cavity visualization through the posterior tympanotomy. In particular, it is important to remove the cholesteatoma from the sinus tympani and anterior recess of the epitympanum, which are invisible directly in optical microscopy through the posterior tympanotomy.

Some researchers point out that the cause of recurrent cholesteatoma is insufficient removal of the tympanic cavity, especially when it grows deep into the sinus tympani [10, 11]. This area is not directly visible by microscope through the posterior tympanotomy, which is why the authors apply endoscopes to visualize the tympanic cavity structures for therapeutic benefits. Endoscopes with optics of 30° and 45° make it possible to see the sinus tympani and Prussak's space precisely. According to the study, there were no significant differences in the visualization of particular anatomical areas of the middle ear by the 30° and 45° optics. However, differences in visualization of these key areas for complete removal of cholesteatoma were significantly more favorable for the endoscopes than for the microscope. Visualization of recesses of the tympanic cavity was found to be significantly better by using both types of endoscopes than using the microscope.

Conclusions

Additional application of endoscopes during middle ear surgery provides valuable information due to excellent visualization of key recesses usually hidden from the microscope. Thanks to the use of endoscopes during canal wall up tympanoplasty with posterior tympanotomy, efficiency of cholesteatoma removal from the tympanic cavity may be significantly better.

References

1. Marchioni D, Alicandri-Ciufelli M, Piccinini A, et al. Surgical anatomy of transcanal endoscopic approach to the tympanic facial nerve. *Laryngoscope* 2011; 121: 1565-73.
2. Klug C, Fabinyi B, Tschabitscher M. Endoscopy of the middle ear through the eustachian tube: anatomic possibilities and limitations. *Am J Otolaryngol* 1999; 20: 299-303.
3. Tschabitscher M, Klug C. Two-port endoscopy of the middle ear. *Arch Otolaryngol Head Neck Surg* 1999; 125: 433-7.
4. Nogueira Junior JF, Martins BM, Aguiar CV. Fully endoscopic stapes surgery (stapedotomy): technique and preliminary results. *Braz J Otorhinolaryngol* 2011; 77: 721-7.
5. Tarabichi M. Endoscopic management of cholesteatoma: long-term results. *Otolaryngol Head Neck Surg* 2000; 122: 874-81.
6. Migirov L, Shapira Y, Horowitz Z, et al. Exclusive endoscopic ear surgery for acquired cholesteatoma. *Otology Neurotol* 2011; 32: 433-6.
7. Marchioni D, Mattioli F, Alicandri-Ciufelli M, et al. Endoscopic evaluation of middle ear ventilation route blockage. *Am J Otolaryngol* 2010; 31: 453-66.
8. Marchioni D, Alicandri-Ciufelli M, Molteni G, et al. Ossicular chain preservation after exclusive endoscopic transcanal tympanoplasty: preliminary experience. *Otology Neurotol* 2011; 32: 626-31.
9. Karchier E, Morawski K, Bartoszewicz R, Niemczyk K. Application of endoscopy in middle ear surgery. *Otolaryngol Pol* 2012; 66: 191-5.
10. Badr-el-Dine M. Value of ear endoscopy in cholesteatoma surgery. *Otology Neurotol* 2002; 23: 631-5.
11. Marchioni D, Mattioli F, Alicandri-Ciufelli M, et al. Transcanal endoscopic approach to the sinus tympani: a clinical report. *Otology Neurotol* 2009; 30: 758-65.

Received: 17.04.2013, **accepted:** 29.05.2013.