

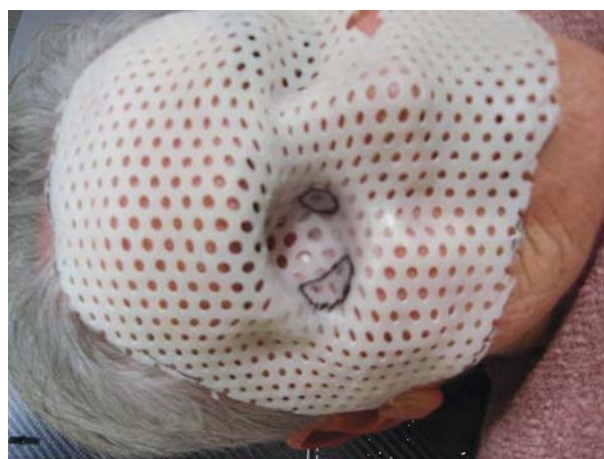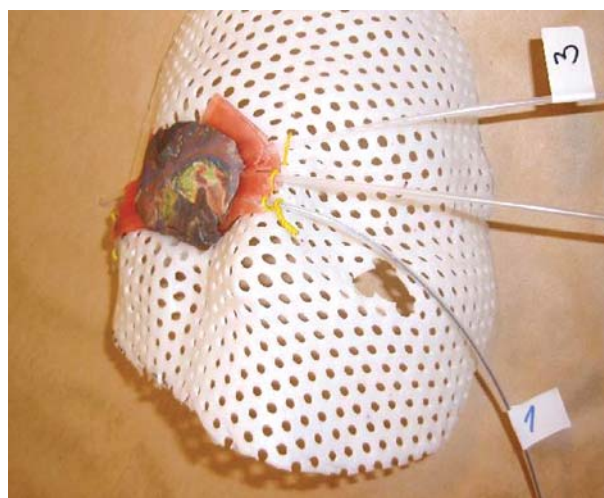
## HDR brachytherapy for skin carcinoma of the face: treatment by customized mask – case report

Lukačko Pavol, Pobjíková Margita, Lederleitner Dávid, Štross Igor

National Oncology Institute, Bratislava, Slovak Republic

**Background and purpose:** Patients with skin neoplasia of the face and scalp, in particular basal cell carcinoma, can be successfully treated with radiation therapy. HDR brachytherapy has been used for a long time in the treatment of skin cancers as, it allows treatment of complex surfaces and good cosmetic results are obtained.

**Material and methods:** 77-year old woman diagnosed with basalioma of the lower eyelid in 2005. Several surgical approaches were performed by plastic surgeons without consulting any oncologist. She has undergone repetitious surgeries always but local failure always followed each



“curative” surgical approach. In 2007 the last surgical treating method for this woman was the orbital exenteration. Nineteen months after an orbital exenteration next local failure developed. With help of dermatologist the lesion was contoured (with margin of 0.5 cm) by a radiopaque wire and fixed to the skin of the patient with plaster strips. A thermoplastic mask was performed, and fixed to patient’s head. On the interest region the plastic catheters were fixed to the mask, the catheters were parallel to each other at a distance of 1.0 cm. Flexible flap of 0.5 cm was not used, because of steep radius of orbital space. The source skin distance was 0.3 cm. Treatment plan was performed with a 3-D TPS Nucletron PLATO system, BPS release 14.2.3 from two orthogonal films. The dose of 4.5 Gy pre fraction was prescribed to 5 mm from the center of catheters (to 85% isodose). Total dose of 45 Gy was administrated in 10 fractions, five fractions per week.

**Results:** In case of these patient a complete remission was obtained with good esthetic result and no severe late toxicity.

**Conclusions:** HDR brachytherapy is a useful technique in the treatment of primary skin cancers with low toxicity and excellent cosmetic results. We think, that proper multidisciplinary treatment in this case could have preserved patient from mutilating surgery.