

QUIZ

WHAT IS YOUR DIAGNOSIS?

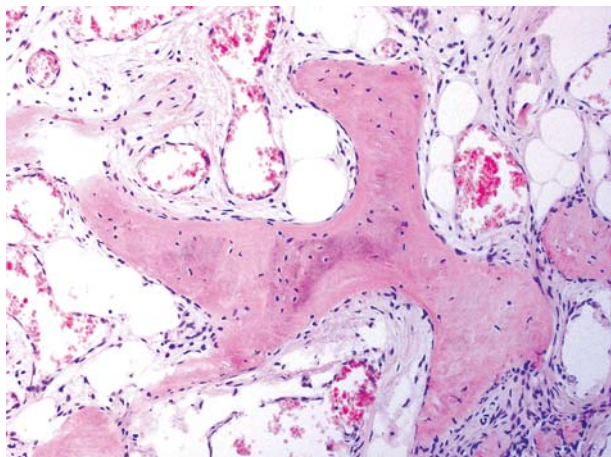


Fig. 1

Case description

A 27-year-old male presented with complaints of progressive and generalized muscle weakness and bone pains for about past six years. Recently the patient has become confined to bed with minimal assisted mobility. He had fractures of his right arm and clavicle with only a minimal trauma. There was no significant family history of the metabolic bone disease or fracture. An intra-articular, 4 cm in diameter tumour of the left knee was surgically removed. The microscopic findings of the tumour are presented below (Fig. 1-5).

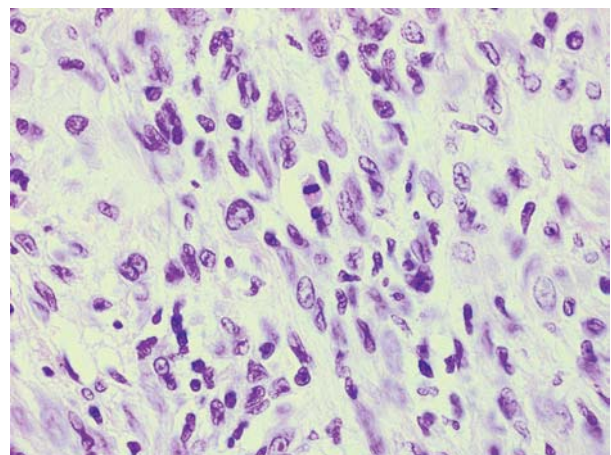


Fig. 2

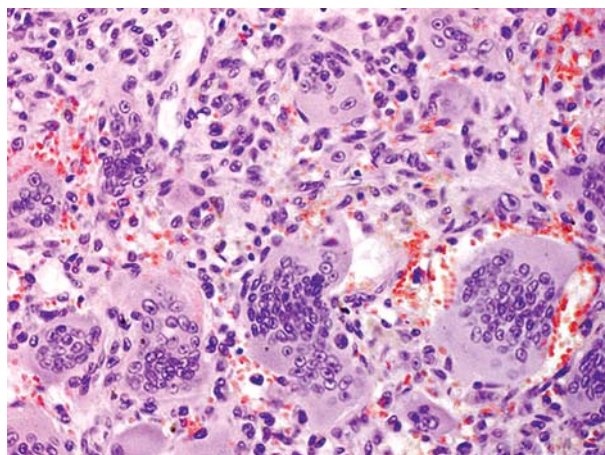


Fig. 3

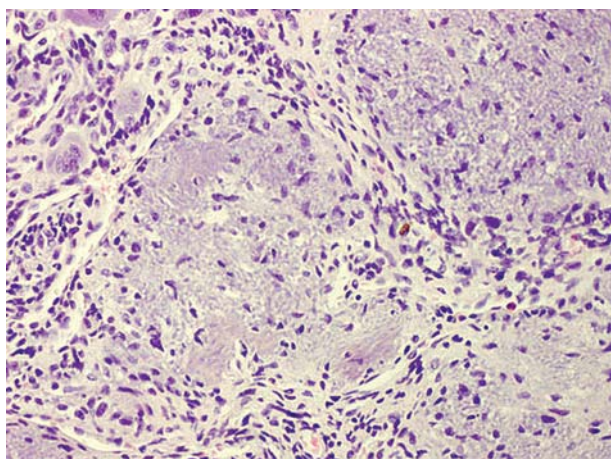


Fig. 4

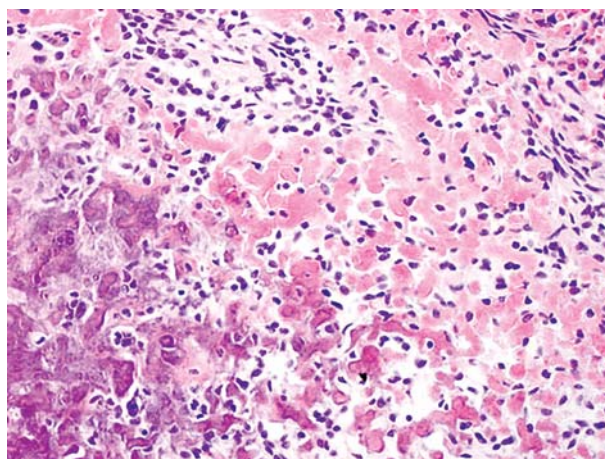


Fig. 5

Anna Szumera-Ciećkiewicz¹, Konrad Ptaszyński¹, Andrzej Paweł², Piotr Rutkowski³

¹Department of Pathology, Maria Skłodowska-Curie Memorial Cancer Center and Institute of Oncology, ul. Roentgena 5, 02-781 Warsaw, phone +48 22 546 27 26, e-mail: annacieckiewicz@coi.waw.pl

²Department of Gastroenterology, ³Department of Soft Tissue/Bone Sarcoma and Melanoma, Maria Skłodowska-Curie Memorial Cancer Center and Institute of Oncology, Warsaw

Answers should be sent to the Editorial Office by 24.12.2009. The correct answer will be announced in the next issue of the *Polish Journal of Pathology*. All participants with the highest number of correct answers to the quizzes published in vol. 60 (4 issues) will be entered into the prize draw for a book.