


# Indications for laparoscopic adrenalectomy as a determinant of the perioperative and postoperative course: a retrospective, single-centre cohort study

## *Wskazania do adrenalektomii laparoskopowej jako wyznacznik przebiegu okołoperacyjnego i pooperacyjnego: retrospektywne, jednośrodkowe badanie kohortowe*

Łukasz Niedziela<sup>1,2</sup> , Emilia Niedziela<sup>2,3</sup>, Mateusz Obarzanowski<sup>1,2</sup>, Paweł Orłowski<sup>1,2</sup>, Marcin Kosowski<sup>1,2</sup>, Aldona Kowalska<sup>2,3</sup>, Stanisław Góźdź<sup>2,4</sup>, Jarosław Jaskulski<sup>1,2</sup>

<sup>1</sup>Department of Urology, Holycross Cancer Centre, Kielce, Poland

<sup>2</sup>Collegium Medicum, Jan Kochanowski University, Kielce, Poland

<sup>3</sup>Department of Endocrinology, Holycross Cancer Centre, Kielce, Poland

<sup>4</sup>Department of Clinical Oncology, Holycross Cancer Centre, Kielce, Poland

Medical Studies/Studia Medyczne 2023; 39 (4): 311–318

DOI: <https://doi.org/10.5114/ms.2023.134081>

**Key words:** adrenal gland neoplasms, adrenalectomy, laparoscopy.

**Słowa kluczowe:** nowotwory nadnerczy, adrenalektomia, laparoscopia.

### Abstract

**Introduction:** Laparoscopic adrenalectomy (LA) is a widely used method for the surgical management of adrenal tumours.

**Aim of the research:** To compare the perioperative and postoperative course in patients with adrenal lesions based on indications for LA.

**Material and methods:** We conducted a retrospective, single-centre data analysis of patients undergoing LA between January 2015 and December 2021. The patients were divided into 4 cohorts, depending on endocrine and oncological indications: (1) hormonally active tumours, (2) non-functioning tumours measuring < 40 mm with suspected radiologic features, (3) non-functioning tumours measuring ≥ 40 mm, and (4) metastases. We established our outcomes on clinical characteristics (age, sex, BMI, Charlson Comorbidity Index (CCI), ASA score, smoking history), perioperative data (side, operation time, blood loss, intraoperative complications, conversion to open surgery, time of drainage, and duration of hospital stay), and postoperative data (histopathological report, 30-day complication rate).

**Results:** A total of 140 patients were included in the study. Comparative analysis of the groups showed differences in ASA score, smoking history, and CCI. The mean operating time was 112 min, and it was significantly longer in the group of patients with adrenal metastases (149 min,  $p = 0.002$ ). Intraoperative complications were observed in 5 (3.6%) patients, conversion to open surgery was performed 3 times (2.1%). No life-threatening complications were observed in the postoperative period.

**Conclusions:** LA is a safe method of surgical treatment of adrenal tumours. Removal of adrenal metastases is an advanced laparoscopic procedure that requires an experienced surgeon. The course of treatment depends on the qualification and preparation of patients for the procedure by a multidisciplinary team.

### Streszczenie

**Wprowadzenie:** Adrenalektomia laparoskopowa jest powszechnie stosowaną metodą chirurgicznego leczenia guzów nadnerczy.

**Cel pracy:** Porównanie przebiegu okołoperacyjnego i pooperacyjnego u pacjentów z guzami nadnerczy poddanych adrenalektomii laparoskopowej w zależności od wskazań do zabiegu.

**Materiał i metody:** Przeprowadzono retrospektywną, jednośrodkową analizę danych pacjentów poddanych laparoskopowej adrenalektomii od stycznia 2015 roku do grudnia 2021 roku. Pacjentów podzielono na 4 kohorty na podstawie endokrynologicznych i onkologicznych wskazań do zabiegu, które obejmowały: 1) guzy aktywne hormonalnie, 2) guzy niewydzielające < 40 mm o podejrzanym cechach radiologicznych, 3) guzy niewydzielające ≥ 40 mm, 4) przerzuty. Analizie zostały poddane: cechy kliniczne (wiek, płeć, BMI, wskaźnik Charlson Comorbidity Index (CCI), grupa w skali ASA, nikotynizm), dane okołoperacyjne (strona operowana, czas operacji, utrata krwi, powikłania śródoperacyjne, konwersja, czas drenażu i hospitalizacji) oraz dane pooperacyjne (wynik histopatologiczny, powikłania).

Medical Studies/Studia Medyczne 2023; 39/4

**Wyniki:** Do badania włączono 140 pacjentów. Analiza porównawcza badanych grup wykazała różnice w zakresie ryzyka okołoperacyjnego według skali ASA, odsetka palaczy tytoniu i wskaźnika predykcyjnego CCI. Średni czas operacji wyniósł 112 min i był istotnie dłuższy u pacjentów z przerzutami do nadnerczy (149 min,  $p = 0,002$ ). Powikłania śródoperacyjne stwierdzono u 5 (3,6%) pacjentów, natomiast konwersję do operacji otwartej wykonano trzykrotnie (2,1%). Nie odnotowano zagrażających życiu powikłań w okresie pooperacyjnym.

**Wnioski:** Laparoskopowa adrenalectomia stanowi bezpieczną metodę chirurgicznego leczenia guzów nadnerczy. Usuwanie zmian przerzutowych do nadnerczy jest zaawansowaną operacją laparoskopową i wymaga dużego doświadczenia operatora. Przebieg leczenia zależy od odpowiedniej kwalifikacji i przygotowania pacjentów do zabiegu przez zespół wielodyscyplinarny.

## Introduction

Although the history of adrenal surgery dates back to the beginning of the 20<sup>th</sup> century, it was in 1992 when Michael Gagner successfully performed and reported the first laparoscopic adrenalectomy (LA) via a lateral transperitoneal approach [1]. Since then, minimally invasive LA has become the standard of care for treating surgical adrenal diseases, due to its safety, feasibility, and cost-effectiveness [2–4]. Because the surgical management of adrenal pathologies is of interest to urologists, and oncological and paediatric surgeons, a variety of surgical techniques and approaches have been developed. Although the procedure is regarded as relatively safe, in 2019 the European Society of Endocrine Surgeons (ESES) recommended that adrenal surgery should be continued only in high-volume centres, with the involvement of an integrated multidisciplinary team performing at least 6 cases per year [5]. The widespread use of robotic technology led to the development and standardization of robot-assisted adrenalectomy [6]. However, to date, robotic surgery, with its higher cost as the most significant drawback, has not substituted LA as the gold standard of surgical management of adrenal diseases [7–9]. Surgical treatment should be offered to patients with adrenal incidentaloma when imaging examinations suggest a malignant lesion or when there is hormonal activity [7, 10–12]. Endocrinological indications to LA include suspected pheochromocytoma, as well as adrenal tumours in patients with ACTH-independent Cushing’s syndrome, primary hyperaldosteronism, or hyperandrogenic syndrome [10–12]. The main oncological indication is a tumour that does not meet the imaging criteria of benign adrenal adenoma, regardless of the size. According to the recommendations of the European Society of Endocrinology, a tumour with a diameter  $\leq 4$  cm with benign imaging features does not require surgery. However, given the clinician’s or patient’s uncertainty about the increasing incidence of malignancy of the larger the mass, surgery may be considered in lesions  $> 4$  cm, even if imaging characteristics suggest a benign nature of the mass, allowing for an individualized approach [11]. There are differences in recommendations regarding the laparoscopic method, which is suggested for lesions  $\leq 8$  cm [7, 10] or even smaller  $\leq 6$  cm [11]. However, a clearly bor-

derline size of adrenal tumour for LA has not been established. Caution should be exercised on attempting a LA approach for benign adrenal masses  $> 10$  cm due to the limitations of laparoscopic equipment [12]. LA is recommended in adrenal masses with radiological findings suspicious of malignancy but without evidence of local invasion. It also refers to patients with isolated adrenal metastases, in whom surgery gives favourable outcomes and durable survival [13]. Open adrenalectomy remains the gold standard of surgical management for adrenocortical carcinoma as well as adrenal masses with signs of local invasion [7, 10, 11, 14–16].

## Aim of the research

The aim of this single-centre study was to compare the perioperative and postoperative course based on different indications for transperitoneal LA in this heterogeneous group of patients.

## Material and methods

In this cohort study, we conducted a retrospective data analysis of 172 patients undergoing LA at a single academic medical centre between January 2015 and December 2021. Institutional Review Board approval was not necessary because these procedures were clinically indicated and all patients signed a standard informed consent form for surgery. Written consent was waived due to the retrospective design of the present study. The procedures of LA during simultaneous laparoscopic radical nephrectomy were not considered in this evaluation ( $n = 29$ ). Patients who underwent bilateral simultaneous adrenalectomy ( $n = 3$ ) were also excluded from this analysis. All patients were consulted by an endocrinologist and an anaesthesiologist prior to surgery. Pre-operative workup included imaging studies (computed tomography (CT) and, in selected cases, magnetic resonance imaging (MRI) or positron emission tomography (PET)), hormonal evaluation, as well as pharmacological preparation when required. The patients were divided into 4 cohorts depending on endocrine and oncological indications to the procedure, which included the following: (1) hormonally active tumours, (2) non-functioning tumours measuring  $< 40$  mm in diameter if suspected features in radiologic studies were observed, (3) non-functioning tumours

measuring  $\geq 40$  mm in diameter, and (4) metastases. Patients with tumours measuring  $> 100$  mm in diameter (hormonally active and non-functioning tumours as well as metastases) and with high suspicion of primary malignancy and local invasion were offered open adrenalectomy in the Department of Oncologic Surgery and were excluded from the study. We analysed the clinical characteristics (age, sex, body mass index (BMI), Charlson Comorbidity Index (CCI) [17], American Society of Anesthesiologists (ASA) score, smoking history), preoperative size of the tumour (maximal size in imaging studies), perioperative data (side, operation time, blood loss, intraoperative complications, conversion to open surgery, time of drainage, and duration of hospital stay), and postoperative data (histopathological report, 30-day complication rate). Patients diagnosed with pheochromocytoma underwent genetic evaluation after surgery.

### Statistical analysis

The data were collected and stored using Microsoft Excel. Continuous and ordinal variables were expressed as the mean (standard deviation) or median (interquartile range) for normally and non-normally distributed variables, respectively. Categorical data were presented as the number of patients and percentages. Group comparisons were performed using the Fisher exact test or  $\chi^2$  test for qualitative variables and Welch's *t* test for quantitative, normally distributed variables, and Welch's ANOVA test was used for quantitative, non-normally distributed variables. The effect size was measured with partial omega square ( $\omega_p^2$ ), epsilon square ( $\epsilon^2_{ordinal}$ ), or Hedges'g formula. Statistical significance was set at  $p < 0.05$ , which was calculated using Holm's correction method for multiple comparisons. Data were analysed using R statistical language (version 4.1.1; R Core Team, 2021) [18].

## Results

### Baseline characteristics

The presented analysis of the study group included 140 patients, and 56.4% were female. Mean age of all patients was 56.7 years (58.2 for female and 54.7 for male). CT was the most common imaging study performed in the primary evaluation ( $n = 126$ ). MRI and PET were used mostly as additional differential tests (Figure 1). The mean (SD) size of the lesion evaluated in pre-operative work-up was 37.3 (17.2) mm, ranging from 7 to 90 mm. We conducted comparative analysis of 4 cohorts depending on indications to the procedure: (1) hormonally active tumours ( $n = 64$ ), (2) non-functioning tumours measuring  $< 40$  mm in diameter if suspected features in radiologic studies were observed ( $n = 25$ ), (3) non-functioning tumours measuring  $\geq 40$  mm in diameter ( $n = 30$ ), and (4) metastases ( $n = 21$ ). Baseline characteristics of the study

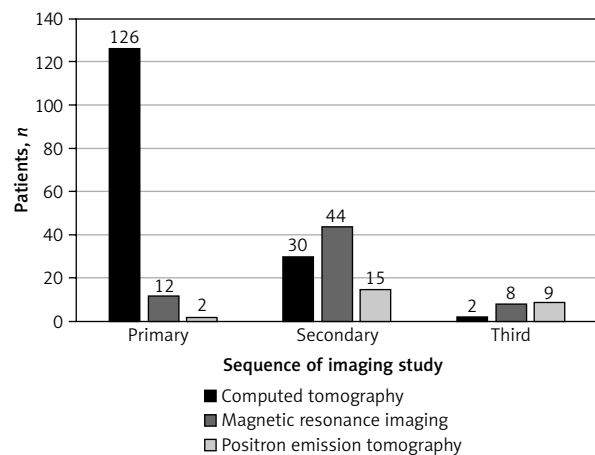


Figure 1. Type, number and sequence of performed imaging studies

groups are presented in Table 1. There were no significant differences between cohorts in terms of mean age, sex, and BMI. Prior to surgery, the physical status of the majority of patients in group 3 was ASA 2, while those with metastatic lesions (group 4) were assessed mainly as ASA 3. In other groups there was no significant difference in terms of ASA physical status. CCI, which predicts the 10-year risk of mortality in patients with multiple comorbidities, was significantly higher in the metastatic group ( $p < 0.01$ ;  $\omega_p^2 = 0.59$ , large effect size). There was a significantly greater percentage of active smokers in the group of patients with non-secreting tumours  $\geq 40$  mm than in the group of patients with hormonally active tumours, which was represented mostly by non-smokers and past smokers ( $p = 0.003$ ) (Figure 2).

### Perioperative data

Our analysis revealed 79 left-sided transabdominal lateral laparoscopic adrenalectomies, and 61 patients had a surgery on the right side. The mean (SD) total operation time of LA was 112.1 (38.1) min, ranging from 50 to 255 min. In 5 patients, we performed additional procedures due to the occurrence of LA (e.g. renal cyst marsupialization, removal of the retroperitoneal suspected lymph node). The duration of surgery was not specified in 7 cases. These 12 patients were excluded from the assessment of the operative time. The mean volume of intraoperative blood loss was 31.2 ml, and in 77.9% of patients it was described as negligible. Damage to a small section of the adrenal surface during surgery was reported in 12 (8.4%) cases, which did not affect the haemodynamic status of the patients as well as the radicality of the resection. Intraoperative complications were described in 5 (3.6%) patients, and they involved damage to the tumour vessels, inferior vena cava, and the tail of the pancreas. Three (2.1%) patients required conversion to open surgery due to excessive bleeding,

**Table 1.** Comparison of 4 cohorts depending on indication to the procedure: (1) hormonally active tumours, (2) non-functioning benign tumours measuring < 40 mm in diameter if suspected features in radiologic studies were observed, (3) non-functioning benign tumours measuring ≥ 40 mm in diameter, and (4) metastases

Parameter	All patients n = 140	Group 1 n = 64	Group 2 n = 25	Group 3 n = 30	Group 4 n = 21	P-value
Demographics:						
Age [year]	56.7 [13.6]	54.1 [14.5]	60.0 [12.9]	55.3 [12.9]	62.1 [11.7]	0.04
Gender [male]	61 (43.6)	29 (45.3)	7 (28.0)	13 (43.3)	12 (57.1)	0.24
Body mass index [kg/m <sup>2</sup> ]	27.9 [4.8]	27.4 [4.9]	29.0 [5.0]	28.2 [4.6]	27.9 [4.1]	0.63
Medical history:						
Charlson Comorbidity Index	5.2 [2.6]	4.2 [2.0]	5.5 [2.5]	4.4 [1.4]	9.0 [2.1]	< 0.01
Smoking history:						0.013
Non-smokers	32 (23.7)	8 (12.9)	6 (24.0)	14 (50.0)	4 (20.0)	
Former smokers	27 (20.0)	16 (25.8)	3 (12.0)	2 (7.1)	10 (50.0)	
Active smokers	76 (56.3)	38 (61.3)	16 (64.0)	12 (42.9)	6 (30.0)	
ASA score:						0.012
1	4 (2.9)	2 (3.1)	1 (4)	1 (3.3)	0 (0.0)	
2	67 (47.9)	30 (46.9)	11 (44)	21 (70.0)	5 (23.8)	
3	65 (46.4)	31 (48.4)	12 (48)	6 (20.0)	16 (76.2)	
4	4 (2.9)	1 (1.4)	1 (4)	2 (6.7)	0 (0.0)	
Preoperative size of the tumour [mm]	37.3 [17.2]	32.5 [16.8]	28.4 [8.1]	53.3 [13.5]	39.0 [16.3]	< 0.001
Perioperative data:						
Side [left]	79 (56.4)	30 (46.9)	16 (64.0)	18 (60.0)	15 (71.4)	0.169
Operation time [min]	112.1 [38.1]	104.0 [29.4]	101.7 [38.5]	110.3 [34.5]	149.0 [46.1]	0.002
Blood loss [ml]	0 {0–0}	0 {0–0}	0 {0–0}	0 {0–0}	0 {0–100}	
Intraoperative complications [if any]	5 (3.6)	2 (3.1)	1 (4.0)	0 (0.0)	2 (9.5)	0.17
Conversion to open surgery	3 (2.1)	1 (1.6)	0 (0.0)	0 (0.0)	2 (9.5)	
Postoperative data:						
Drainage [day]:						0.217
1	29 (20.7)	11 (17.2)	8 (32.0)	7 (23.3)	3 (14.3)	
2	94 (67.1)	46 (71.9)	14 (56.0)	18 (60.0)	16 (76.2)	
3	13 (9.3)	6 (9.4)	2 (8.0)	5 (16.7)	0 (0.0)	
4	4 (2.9)	1 (1.6)	1 (4.0)	0 (0.0)	2 (9.5)	
Length of stay [day]	3.3 [1.1]	3.2 [1.0]	3.2 [1.0]	3.2 [1.1]	3.7 [1.4]	0.38
Complication 30-day [if any]	15 (10.7)	7 (10.9)	3 (12.0)	2 (6.7)	3 (14.3)	

Values are presented as mean [standard deviation], median {interquartile range} or number (percentage); ASA score – American Society of Anesthesiologists physical status classification.

pancreatic tail injury, and suspected tumour thrombus extension into the renal vein of a solitary kidney. 67.1% of patients required drainage of the operated area for 2 days. The mean (SD) length of hospitalization was 3.3 (1.1) days. During hospitalization, 15 patients were consulted by endocrinologists to adjust or introduce hormonal substitution or further treatment

depending on indication to the procedure (e.g. patients suspected of pheochromocytoma or metastasis to the only remaining adrenal gland).

Welch’s ANOVA test revealed that surgeries of metastases lasted significantly longer (149 min, SD 46.1) in relation to other cohorts ( $p = 0.002$ ,  $\omega_p^2 = 0.22$ , large effect size) (Figure 3). When comparing groups, there

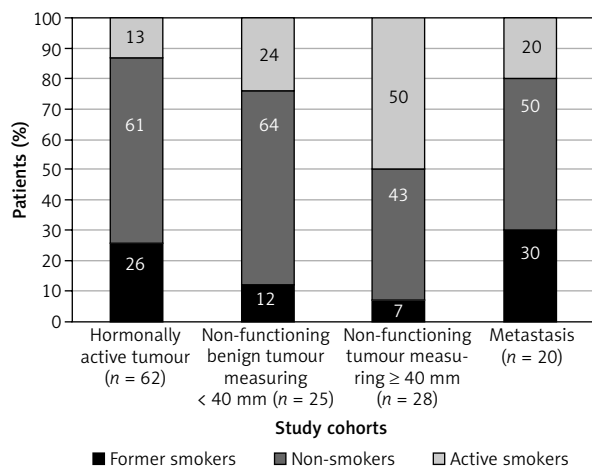


Figure 2. Smoking history in compared cohorts

were no significant differences in terms of side of operated adrenal gland, blood loss, intraoperative and 30-day postoperative complications, length of drainage, and duration of hospitalization. Our analysis showed that performing additional imaging studies prior to surgery did not reduce the rate of intra- and postoperative complications or the length of hospital stay.

#### Tumour characteristics and postoperative data (30 days after surgery)

In total 64 patients were diagnosed with the functioning tumours, including 40 pheochromocytomas. The most common histopathological diagnosis was adenoma ( $n = 52$ ). In 21 cases adrenal glands were affected by metastases of different origin, most often renal cell carcinoma ( $n = 18$ ). There were isolated cases of patients diagnosed with primary malignancies such as adrenal cortical carcinoma, sarcoma, and lymphoma (Table 2).

The assessment of postoperative morbidities within 30 days after surgery (30-d) was done using the Clavien-Dindo Classification (CDC) [19]. A total of 23 complications were reported in 18 patients during the period under review. The most serious complication was an evisceration, corresponding to CDC grade IIIb, which occurred in 1 patient. Our analysis showed that 2 patients experienced cardiovascular events, including exacerbation of coronary artery disease and cardiac arrhythmia. During the outpatient visit with histopathological results, patients were referred for further endocrine follow-up including observation, hormonal tests, or adjuvant treatment. Genetic evaluation showed that pheochromocytoma was a part of multiple endocrine neoplasia syndrome (MEN) in 5 of the 40 patients. All of them were affected by MEN2a syndrome, including a pregnant woman who underwent successful surgery in the second trimester.

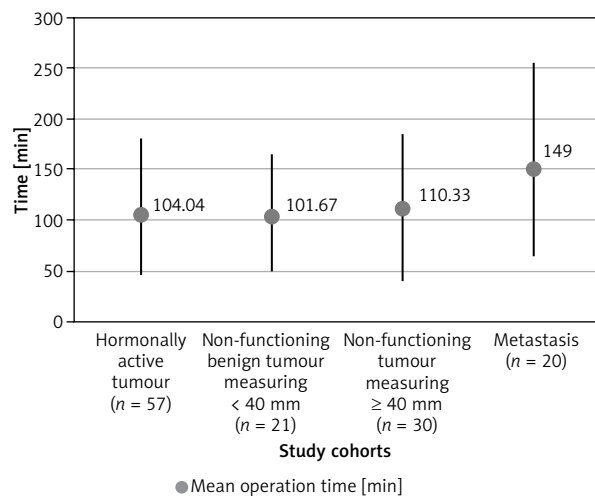


Figure 3. Operation time in compared cohorts

Table 2. Tumour characteristics (number of tumours)

Histopathology	Number of tumours
Adenoma:	52
Non-functioning	28
Autonomously cortisol-secreting	2
Aldosterone-secreting	21
Androgen-secreting	1
Nodular hyperplasia	2
Myelolipoma/angiomyolipoma	7
Cyst	3
Ganglioneuroma	3
Haemangioma	4
Teratoma	1
Other	4
Pheochromocytoma	40
Adrenocortical carcinoma	1
Sarcoma	1
Lymphoma	1
Metastasis:	21
Renal cancer	18
Colon cancer	1
Lung cancer	2

#### Discussion

Laparoscopic method is reasonable for most adrenal tumours requiring surgical resection and is regarded as a point of reference in adrenal surgery. Although many international and national scientific societies recommend the choice of laparoscopic access

based on the experience of the surgeon, it is estimated that 85% of health centres, including ours, perform lateral transperitoneal LA [4, 7, 10]. Our department meets the criteria of a high-volume centre as defined in the consensus statement of the European Society of Endocrine Surgeons. The results of our study showed that LA is a feasible, safe, and repetitive procedure with a low complication rate.

Taking into consideration the variety of indications for LA in this heterogeneous group of patients, the essential role of the multidisciplinary team, including urologists, surgeons, endocrinologists, and anaesthesiologists, in the qualification of patients for surgery should be emphasized. This refers particularly to a group of patients with pheochromocytoma, who are at high risk of intraoperative haemodynamic instability [10, 20, 21]. The cooperation of the multidisciplinary team minimized the cardiovascular 30-day complications (1.4%) and contributed to the survival of all operated patients (mortality rate 0%).

According to the recommendations of the European Society of Endocrinology, the most important aim of imaging studies is to assess the risk of adrenal tumour malignancy, and CT is indicated as the initial imaging tool [10–12]. If the image of an adrenal tumour is inconclusive in this examination and the tumour does not show hormonal activity, other imaging tests are required. The main oncological indication for adrenal incidentaloma surgery is a tumour that does not meet the imaging criteria of benign adrenal adenoma (density in unenhanced CT over 30 HU, contrast medium washout < 50% in the 10<sup>th</sup> min, or lack of lipids in MRI), irrespective of its size [10, 11]. Regarding the indications for surgery of adrenal incidentalomas, tumour size was a subject of debate, the conclusion of which was to establish an arbitrary cut-off point below which lesions ≤ 4 cm with benign radiologic features did not require surgical treatment [11]. However, the risk of malignancy and of pheochromocytoma increases with increasing tumour size. Surgery may be considered as an individual approach in larger lesions (> 4 cm) even if imaging characteristics suggest a benign nature of the lesion. Our analysis showed no significant differences in perioperative and postoperative course in cohorts (group 2 and 3) differing in tumour size based on the arbitrary cut-off point (4 cm). Therefore, this factor should not be considered as influencing the decision to treat lesions > 4 cm with benign imaging features. This is consistent with the results of another study in which the risk of intraoperative and postoperative complications was independent of tumour size [22].

Adrenocortical carcinoma (ACC) is a rare endocrine malignancy with poor prognosis. Patients with lesions highly suspected of primary malignancy were treated in the Department of Oncologic Surgery and were excluded from this analysis. However, because

the final diagnosis is based on histopathological results, our study showed 3 laparoscopically removed primary malignant lesions, including sarcoma, lymphoma, and R1 resection of ACC, requiring further oncologic treatment. Although a minimally invasive approach for small tumours suspected of malignancy can be considered in experienced high-volume centres, open adrenalectomy remains the gold standard of surgical management for ACC to achieve R0 resection [7, 14–16].

Adrenal glands are common sites of metastases in patients with advanced cancers. The incidence of these lesions in adrenal incidentalomas is generally estimated at 5–7% (range 0–21% in surgical series). The adrenalectomy is indicated when the adrenal lesion is isolated and the primary tumour has been, or can be, removed [11, 13]. Large autopsy studies identified breast carcinoma, melanoma, and lung carcinoma as primary malignant disorders with the highest percentage of metastases to adrenal glands (58%, 50%, and 42%, respectively) [23]. The largest published study describing the localization of metastases from renal cell carcinoma (RCC) puts the adrenal gland in the fifth place with a frequency of 6–10% depending on the subtype of RCC [24]. Spertalis *et al.* [25] performed a meta-analysis of 87 original studies involving 660 patients, showing that among metastatic adrenal lesions treated surgically, lung and renal cancers were the most common primary origins. Metastases are often detected in patients who are followed up after treatment for pre-existing cancer. As our study presented, renal cell carcinoma (especially clear cell and papillary subtypes) constituted about 85.7% of the histopathological diagnoses of resected metastatic lesions. This result may be explained by the systematic outpatient follow-up and imaging tests in patients after surgical treatment of RCC in our department (in accordance with the guidelines of the European Association of Urology). As presented, the cohort with adrenal metastases had significantly worse 10-year predictive survival based on the Charlson Comorbidity Index ( $p < 0.01$ ) and longer mean operative time ( $p = 0.002$ ) compared to patients operated on for other indications. Thus, metastatic lesions are the most surgically challenging indication for LA. However, the studies available in the literature have shown little or no increase in operative time in case of metastatic lesions [26, 27].

The mean duration of transabdominal LA in our analysis was 112.1 min. This is comparable to large surgical studies, in which the mean operative time ranges from 84 to 146 min [1, 2, 8, 9, 27–31]. In the literature, the overall conversion rate to open surgery is reported to be between 0 and 5.6% [1–3, 8, 26–31]. Malignancy, tumour size, and obesity were identified as risk factors of conversion [26, 29, 31]. The results of our analysis showed that intraoperative change to open approach

was necessary in 3 patients (with histopathological diagnosis of pheochromocytoma and metastases of RCC origin), corresponding to a conversion rate of 2.1%. However, we did not observe any significant 30-day complications in these cases. The average rate of perioperative complications of LA reported in the literature ranges from 0 to 18.6%, with bleeding being the most frequent complication [2, 8, 20, 26, 27, 29, 30]. The observed complication rate of 5.6% in our analysis is in line with the above studies. In Alberici *et al.* [31], preoperative 'difficulty score' nomograms were proposed to predict a complicated perioperative course, reflecting such critical events as conversion to open surgery and prolonged operative time. Although it requires further external validation, the use of nomograms can be an additional measurement in preoperative assessment to help with appropriate qualification of patients and reduce adverse events during surgery.

The widely used Clavien-Dindo classification (CDC) was implemented to evaluate complications in an objective, simple, and reproducible manner. Our analysis showed that postoperative complications occurred in 12.9% of patients, and in most cases they were mild (CDC < 3). Only 1 patient had a CDC grade IIIb complication (evisceration), which is the cut-off point above which the most severe complications are found. There were no life-threatening complications requiring intensive-care unit management (grade IV), and the mortality rate (grade V) in our study was 0%. It is comparable with the results of other centres, in which the mortality rate ranges from 0% to 1%, which is undeniable proof of the safety of LA [1–3, 27–30].

The main limitation of this single-centre study is its retrospective nature. Our data concerned transabdominal laparoscopic adrenalectomies performed more than a decade after the first procedure of this type in our centre. This may have affected peri- and postoperative outcomes, including operative time and complication rate, due to changes in the experience of our team and the use of different types of surgical equipment over the years. Another limitation is the fact that in this analysis we did not include potential postoperative complications that might have occurred more than 30 days after hospital discharge, which could have affected the overall complication rate.

## Conclusions

Based on our study, we proved that transperitoneal LA is a safe, repetitive, gold standard for the surgical management of adrenal tumours. The perioperative and postoperative course is mostly comparable in patients undergoing LA for different indications. Given the long operating time and associated comorbidities, metastatic lesions are the most surgically challenging indications for LA. The results of the treatment depend on appropriate qualification and preparation of patients undergoing LA, which can be achieved by

close cooperation of a multidisciplinary team including urologists, surgical oncologists, endocrinologists, and anaesthesiologists.

## Conflict of interest

The authors declare no conflict of interest.

## References

- Gagner M, Lacroix A, Prinz RA, Bolté E, Albala D, Potvin C, Hamet P, Kuchel O, Quéryn S, Pomp A. Early experience with laparoscopic approach for adrenalectomy. *Surgery* 1993; 114: 1120-1124.
- Gagner M, Pomp A, Heniford BT, Pharand D, Lacroix A. Laparoscopic adrenalectomy: lessons learned from 100 consecutive procedures. *Ann Surg* 1997; 226: 238-246.
- Heslin MJ, Winzeler AH, Weingarten JO, Diethelm AG, Urist MM, Bland KI. Laparoscopic adrenalectomy and splenectomy are safe and reduce hospital stay and charges. *Am Surg* 2003; 69: 377-381.
- Stefanidis D, Goldfarb M, Kercher KW, Hope WW, Richardson W, Fanelli RD. SAGES guidelines for minimally invasive treatment of adrenal pathology. *Surg Endosc* 2013; 27: 3960-3980.
- Mihai R, Donatini G, Vidal O, Brunaud L. Volume-outcome correlation in adrenal surgery-an ESES consensus statement. *Langenbecks Arch Surg* 2019; 404: 795-806.
- Desai MM, Gill IS, Kaouk JH, Matin SF, Sung GT, Bravo EL. Robotic-assisted laparoscopic adrenalectomy. *Urology* 2002; 60: 1104-1107.
- Ball MW, Hemal AK, Allaf ME. International Consultation on Urological Diseases and European Association of Urology International Consultation on Minimally Invasive Surgery in Urology: laparoscopic and robotic adrenalectomy. *BJU Int* 2017; 119: 13-21.
- Morino M, Benincà G, Giraudo G, Del Genio GM, Rebecchi F, Garrone C. Robot-assisted vs laparoscopic adrenalectomy: a prospective randomized controlled trial. *Surg Endosc* 2004; 18: 1742-1746.
- Ma W, Mao Y, Zhuo R, Dai J, Fang C, Wang C, Zhao J, He W, Zhu Y, Xu D, Sun F. Surgical outcomes of a randomized controlled trial compared robotic versus laparoscopic adrenalectomy for pheochromocytoma. *Eur J Surg Oncol* 2020; 46: 1843-1847.
- Bednarczuk T, Bolanowski M, Sworczak K, Górnicka B, Cieszanowski A, Otto M, Ambroziak U, Pachucki J, Kubicka E, Babińska A, Koperski Ł, Januszewicz A, Prejbisz A, Górska M, Jarzab B, Hubalewska-Dydejczyk A, Glinicki P, Ruchała M, Kasperlik-Załuska A. Adrenal incidentaloma in adults - management recommendations by the Polish Society of Endocrinology. *Endokrynol Pol* 2016; 67: 234-258.
- Fassnacht M, Arlt W, Bancos I, Dralle H, Newell-Price J, Sahdev A, Tabarin A, Terzolo M, Tsagarakis S, Dekkers OM. Management of adrenal incidentalomas: European Society of Endocrinology Clinical Practice Guideline in collaboration with the European Network for the Study of Adrenal Tumors. *Eur J Endocrinol* 2016; 175: G1-G34.
- Bittner JG 4th, Brunt LM. Evaluation and management of adrenal incidentaloma. *J Surg Oncol* 2012; 106: 557-564.
- Wachtel H, Roses RE, Kuo LE, Lindeman BM, Nehs MA, Tavakkoli A, Parangi S, Hodin RA, Fraker DL, James BC,

- Carr AA, Wang TS, Solórzano CC, Lubitz CC. Adrenalectomy for secondary malignancy: patients, outcomes, and indications. *Ann Surg* 2021; 274: 1073-1080.
14. Gaujoux S, Mihai R on behalf of the joint working group of ESES and ENSAT. European Society of Endocrine Surgeons (ESES) and European Network for the Study of Adrenal Tumours (ENSAT) recommendations for the surgical management of adrenocortical carcinoma. *Br J Surg* 2017; 104: 358-376.
  15. Fassnacht M, Dekkers OM, Else T, Baudin E, Berruti A, de Krijger R, Haak HR, Mihai R, Assie G, Terzolo M. European Society of Endocrinology Clinical Practice Guidelines on the management of adrenocortical carcinoma in adults, in collaboration with the European Network for the Study of Adrenal Tumours. *Eur J Endocrinol* 2018; 179: G1-G46.
  16. Sinclair TJ, Gillis A, Alobuia WM, Wild H, Kebebew E. Surgery for adrenocortical carcinoma: when and how? *Best Pract Res Clin Endocrinol Metab* 2020; 34: 101408.
  17. Charlson ME, Pompei P, Ales KL, MacKenzie CR. A new method of classifying prognostic comorbidity in longitudinal studies: development and validation. *J Chronic Dis* 1987; 40: 373-383.
  18. R Core Team (2021). *R: A Language and Environment for Statistical Computing*. R Foundation for Statistical Computing, Vienna, Austria. <URL: <https://www.R-project.org/>>.
  19. Dindo D, Demartines N, Clavien PA. Classification of surgical complications: a new proposal with evaluation in a cohort of 6336 patients and results of a survey. *Ann Surg* 2004; 240: 205-213.
  20. Tariel F, Dourmap C, Prudhomme T, Hascoet J, Soulie M, Moreau B, Thoulouzan M, Vezzosi D, Guenego A, Manunta A, Huyghe E, Peyronnet B. Adrenalectomy for pheochromocytoma: complications and predictive factors of intraoperative hemodynamic instability. *Am Surg* 2023; 89: 4772-1779.
  21. Urabe F, Kimura S, Iwatani K, Takahashi K, Ito K, Tashiro K, Tsuzuki S, Miki J, Kimura T, Furuta N, Egawa S. Risk factors for perioperative hemodynamic instability in pheochromocytoma: a systematic review and meta-analysis. *J Clin Med* 2021; 10: 4531.
  22. Mínguez Ojeda C, Gómez Dos Santos V, Álvaro Lorca J, Ruz-Caracuel I, Pian H, Sanjuanbenito Dehesa A, Burgos Revilla FJ, Araujo-Castro M. Tumour size in adrenal tumours: its importance in the indication of adrenalectomy and in surgical outcomes-a single-centre experience. *J Endocrinol Invest* 2022; 45: 1999-2006.
  23. Seidenwurm DJ, Elmer EB, Kaplan LM, Williams EK, Morris DG, Hoffman AR. Metastases to the adrenal glands and the development of Addison's disease. *Cancer* 1984; 54: 552-557.
  24. Dudani S, de Velasco G, Wells JC, Gan CL, Donskov F, Porta C, Fraccon A, Pasini F, Lee JL, Hansen A, Bjarnason GA, Beuselinck B, Pal SK, Yuasa T, Kroeger N, Kaneshvaran R, Reaume MN, Canil C, Choueiri TK, Heng DY. Evaluation of clear cell, papillary, and chromophobe renal cell carcinoma metastasis sites and association with survival. *JAMA Netw Open* 2021; 4: e2021869.
  25. Spartalis E, Drikos I, Ioannidis A, Chrysikos D, Athanasidis DI, Spartalis M, Avgerinos D. Metastatic carcinomas of the adrenal glands: from diagnosis to treatment. *Anti-cancer Res* 2019; 39: 2699-2710.
  26. Natkaniec M, Dworak J, Pędziwiatr M, Pisarska M, Major P, Dembiński M, Winiarski M, Budzyński A. Patients criteria determining difficulty of the laparoscopic lateral transperitoneal adrenalectomy. A retrospective cohort study. *Int J Surg* 2017; 43: 33-37.
  27. Battistella E, Ferrari S, Pomba L, Toniato A. Adrenal surgery: Review of 35 years experience in a single centre. *Surg Oncol* 2021; 37: 101554.
  28. Duralska M, Dzwonkowski J, Sierdziński J, Nazarewski S. High-volume center experience with laparoscopic adrenalectomy over two decades. *J Clin Med* 2022; 11: 23-35.
  29. Pędziwiatr M, Wierdak M, Ostachowski M, Natkaniec M, Białas M, Hubalewska-Dydejczyk A, Matłok M, Major P, Budzyński P, Migaczewski M, Budzyński A. Single center outcomes of laparoscopic transperitoneal lateral adrenalectomy--lessons learned after 500 cases: a retrospective cohort study. *Int J Surg* 2015; 20: 88-94.
  30. Coste T, Caiazzo R, Torres F, Vantghem MC, Carnaille B, Do Cao C, Douillard C, Pattou F. Laparoscopic adrenalectomy by transabdominal lateral approach: 20 years of experience. *Surg Endosc* 2017; 31: 2743-2751.
  31. Alberici L, Paganini AM, Ricci C, Balla A, Ballarini Z, Ortenzi M, Casole G, Quaresima S, Di Dalmazi G, Ursi P, Alfano MS, Selva S, Casadei R, Ingaldi C, Lezoche G, Guerrieri M, Minni F, Tiberio GAM. Development and validation of a preoperative "difficulty score" for laparoscopic transabdominal adrenalectomy: a multicenter retrospective study. *Surg Endosc* 2022; 36: 3549-3557.

#### Address for correspondence

**Łukasz Niedziela MD**  
Department of Urology  
Holycross Cancer Centre  
*Collegium Medicum*  
Jan Kochanowski University  
Kielce, Poland  
E-mail: lukasz.w.niedziela@gmail.com