

Case report

# Severe intrahepatic cholestasis and liver failure after stanozolol usage – case report and review of the literature

Piotr M. Stępień<sup>1</sup>, Katarzyna Reczko<sup>1</sup>, Anna Wiczorek<sup>2</sup>, Dorota Zarębska-Michaluk<sup>1</sup>, Paweł Pabjan<sup>1</sup>, Teodora Król<sup>2</sup>, Wiesław Kryczka<sup>1,3</sup>

<sup>1</sup>Clinic of Infectious Diseases, Regional Polyclinic Hospital, Kielce, Poland

<sup>2</sup>Department of Cell Biology and Electron Microscopy, Institute of Biology, Jan Kochanowski University, Kielce, Poland

<sup>3</sup>Department of Internal Diseases, Cardiology and Internal Medicine Nursing, Institute of Nursing and Maternity, Faculty of Health Sciences, Jan Kochanowski University, Kielce, Poland

## Abstract

Stanozolol is a 17 $\alpha$ -alkylated synthetic anabolic steroid used illegally by bodybuilders. We present a 19-year-old man who was taking 50 mg of stanozolol intramuscularly, every other day for 2 months, to improve muscle mass. On admission, his bilirubin concentration was 44.34 mg/dl. The serum levels of liver enzymes were normal, with only alanine aminotransferase being slightly elevated. Liver biopsy revealed toxic hepatitis of minor grade with periportal fibrosis and intrahepatic cholestasis. Medical treatment of the patient was conservative. Despite the therapy the patient's general condition deteriorated – bilirubin level increased to 56.64 mg/dl, and INR rose to 1.7. Then we decided to administer low doses of hydrocortisone. As a result of the treatment, bilirubin concentration was 14.61 mg/dl after 2 weeks. Finally all hepatic enzymes returned to normal values 5 months after stanozolol was discontinued. This treatment appears to be safe and leads to a more rapid reduction of bilirubin.

**Key words:** liver failure, stanozolol, anabolic steroids, hydrocortisone, cholestasis.

## Address for correspondence

Piotr M. Stępień, Clinic of Infectious Diseases, Regional Polyclinic Hospital, 7 Radiowa St., 25-317 Kielce, Poland, e-mail: p\_stepien@interia.pl

## Introduction

Stanozolol (CAS 10418-03-8) is a 17 $\alpha$ -alkylated synthetic anabolic steroid derived from dihydrotestosterone. In spite of the fact that stanozolol is on WADA's (World Anti-Doping Agency) prohibited list, it is used by both professional and amateur athletes, especially bodybuilders. Using anabolic androgenic steroids (AAS) is associated with a number of side effects including virilization, gynecomastia, psychiatric disorders and adverse lipid profiles [1,2]. Also several liver diseases such as cholestasis, peliosis hepatis and liver tumors (e.g. adenoma, hepatocellular carcinoma, angiosarcoma, etc.) may occur [3]. A spontaneous hepatic rupture with hemorrhage after using several types of AAS (decanoates, stanozolol, primabolin) has also been described previously [4]. Unfortunately, many people

believe that toxic and dangerous effects of AAS appear only after long-term administration. In our case report we present a young student who developed severe cholestasis in consequence of intramuscular injection of stanozolol.

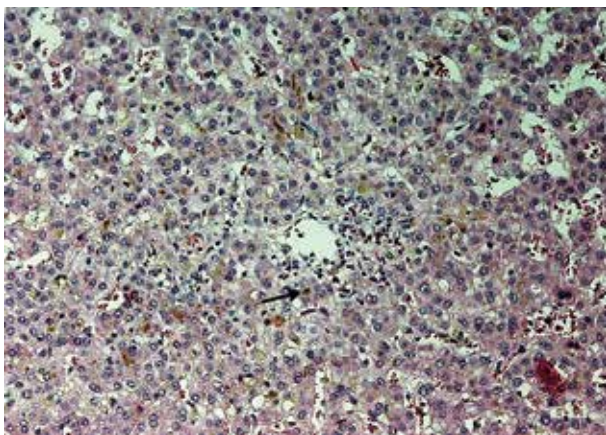
## Case report

A 19-year-old man, a previously healthy amateur bodybuilder, was admitted to our hospital because of general malaise, jaundice and severe itching. He had been injecting stanozolol, 50 mg intramuscularly, every other day for 2 months to improve his muscle mass. The symptoms appeared about 5 weeks before admission and increased gradually. Previously he had been taking supplements for athletes for several years. The patient had no history of liver disease, and he did

not smoke, drink alcohol or take drugs. Physical examination revealed a well-built (BMI = 29.32 kg/m<sup>2</sup>) man with jaundice. The liver extended about 3 cm below the costal margin. There were no stigmata of chronic liver disease. The remaining examination revealed no disturbances. There were no signs of encephalopathy or mental disorders.

Total bilirubin concentration on admission was 44.34 mg/dl (normally 0.1 to 1.3), and direct bilirubin was 13.65 mg/dl. The serum levels of liver enzymes were: aspartate aminotransferase (AST) – 45 U/l (normally 5 to 50), alanine aminotransferase (ALT) – 63 U/l (normally 5 to 50), alkaline phosphatase (ALP) – 77 U/l (normally 35 to 125), and gamma-glutamyl transpeptidase (GGTP) – 27 U/l (normally 10 to 75). Creatinine level was slightly increased at 1.6 mg/dl (normally 0.9 to 1.3), but serum concentrations of sodium, potassium and urea were within normal limits. Peripheral blood morphology, levels of  $\alpha$ -fetoprotein (AFP) and immunoglobulins (Ig) were normal as well as INR (international normalized ratio). Concentration of albumin was reduced to 3.29 g/dl (normal range from 4.3 to 5.1) and serum concentration of cholesterol was very low – only 18 mg/dl (normally 130 to 200). Serologic tests for viral hepatitis (HAV, HBV, HCV), Epstein-Barr virus and HIV were negative. Autoantibodies (ANA, AMA, SMA, LMA, BCA) were negative too. Nuclear magnetic resonance of the biliary tract showed no obstruction in the biliary tree. Acute-phase proteins – C-reactive protein (CRP) and ceruloplasmin – were slightly increased.

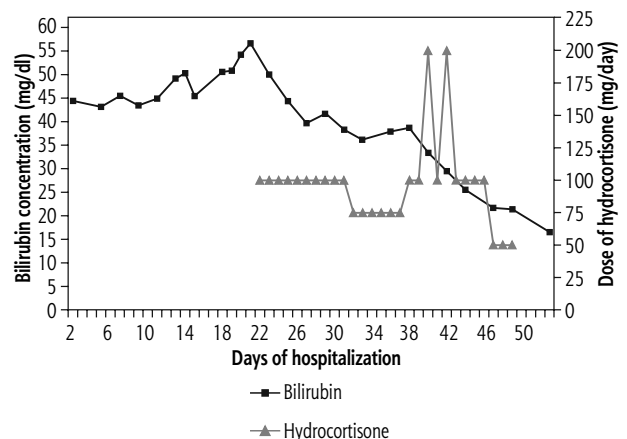
A percutaneous liver biopsy was performed, showing preserved cytoarchitectonics of the organ, toxic hepatitis of minor grade (A-4) with periportal fibrosis (F-2) and intrahepatic cholestasis (HAI Ishak). Disseminated feathery degeneration of hepatocytes with focal bilirubinostasis was present (Fig. 1).



**Fig. 1.** Stanozolol-induced cholestatic hepatitis with hepatocellular bile (arrow) in centrilobular area (hematoxylin and eosin staining,  $\times 200$ )

Medical treatment of the patient was conservative. Therapy included L-ornithine L-aspartate, timonacic and ursodeoxycholic acid (UDCA), among other things. In spite of the treatment the patient's general condition was deteriorating for 3 weeks and acute liver failure developed. The bilirubin level increased to 54.32 mg/dl; LDL (low-density lipoprotein) and HDL (high-density lipoprotein) were undetectable. The patient was suffering from insomnia. The INR increased to 1.7 (normally 0.8 to 1.2), so the patient received one dose of vitamin K<sub>1</sub> intravenously. When the concentration of bilirubin reached 56.64 mg/dl, we decided to administer low-dose hydrocortisone (100 mg/day, intravenously). After the first injection the level of bilirubin decreased from 56.64 to 50.05 mg/dl. In 11 days' time it had decreased to 36.16 mg/dl. Then the dose of hydrocortisone was reduced to 75 mg/day, but unexpectedly the concentration of bilirubin rose to 38.68 mg/dl during 4 days. Therefore we decided to use 200 mg/day of hydrocortisone for 2 days, then gradually reduce the dose for 10 days. As a result of this treatment the bilirubin concentration was 14.61 mg/dl after 2 weeks (Fig. 2). During steroid therapy, levels of ALT and AST rose to 135 U/l and 58 U/l respectively. After 2 months of hospitalization the patient was discharged.

Three weeks later he was admitted to the first follow-up. The liver function tests revealed: bilirubin – 3.81 mg/dl (indirect – 3.72 ml/dl), ALT – 59 U/l, AST – 29 U/l, ALP – 75 U/l, GGTP – 35 U/l. Concentration of albumin was 4.57 mg/dl, HDL – 45 mg/dl (normally 35 to 65), LDL – 62 mg/dl (normally < 135) and INR – 1.1. Renal functions (creatinine, urea, [Na<sup>+</sup>], [K<sup>+</sup>]) were normal too. Five months after the patient had discontinued taking stanozolol all hepatic enzymes had returned to normal values: total bilirubin concentration was 1.29 mg/dl, ALT – 36 U/l, AST – 22 U/l, ALP – 79 U/l, GGTP – 27 U/l.



**Fig. 2.** Correlation between dose of hydrocortisone and serum concentration of bilirubin

## Discussion

Nowadays stanozolol and other anabolic steroids are widely available via the Internet [5] and their usage has grown in recent years [6]. It is dangerous because many young people may buy such substances and use them without any control. The cholestasis induced by AAS is pure and usually it is not associated with damage of hepatocytes (hepatitis), so aminotransferase and ALP remain within normal limits [7,8]. The molecular mechanism of cholestasis after stanozolol or other anabolic steroids usage is unclear. Previous studies suggested interference with canalicular excretion of conjugated bile and the sinusoidal uptake of bile because of inhibition of Na<sup>+</sup>/K<sup>+</sup> ATPase on the sinusoidal membrane or competition for bile acid receptors [3,9,10]. Recently Fernandez-Perez *et al.* [11] characterized in male rat liver membranes of endoplasmic reticulum two sites for glucocorticoids and anabolic-androgenic steroids: the low affinity glucocorticoid binding site (LAGS) and the stanozolol binding protein (STBP). STBP, which has an extremely narrow pharmacological profile, seems to be selective only for stanozolol and danazol. The authors suggested that stanozolol (via STBP) may modulate glucocorticoid activity in the liver through negative allosteric modulation of the LAGS. This results in an effective increase in glucocorticoid availability to the classical cytosolic glucocorticoid receptor (GR). In 2011 Schwingel *et al.* published an analysis suggesting that AAS could be a new risk factor for toxicant-associated fatty liver disease (TAFLD) [12].

In our patient pure cholestasis and liver failure developed after stanozolol use. Similar cases were reported previously [9,13-15], but in most instances the patients also had renal failure [9,13] or high activity of ALT/AST [14,15]. A study describing acute, intrahepatic cholestatic hepatitis secondary to another anabolic steroid (Mastabol) was published recently [16]. In that case the patient had high ALP activity and an increased bilirubin concentration but only a mild aminotransferase increase. Our patient had normal renal function as well as levels of ALP and GGTP. The slightly increased concentration of creatinine could be associated with his well-developed muscle mass.

Liver injury due to AAS generally has a favorable prognosis for spontaneous recovery. The symptoms withdraw and liver enzymes with bilirubin normalize after discontinuing the drugs. Unfortunately, some cases may be associated with increased risk of liver failure, need for liver transplantation and high mortality. These occur when the bilirubin concentration is increased threefold above the standard value [17].

Because our patient had acute liver failure, we decided to use not only ursodeoxycholic acid but also a corticosteroid (hydrocortisone). According to a recent study [18], this kind of treatment appears to be safe, improves liver functions and speeds up recovery of the patient. We also observed a relationship between the dose of hydrocortisone and serum concentration of bilirubin.

## Disclosure

Authors report no conflict of interest.

## References

1. Kopera H. Side effects of anabolic steroids and contraindications. *Wien Med Wochenschr* 1993; 143: 399-400.
2. Socas L, Zumbado M, Pérez-Luzardo O, et al. Hepatocellular adenomas associated with anabolic androgenic steroid abuse in bodybuilders: a report of two cases and a review of the literature. *Br J Sports Med* 2005; 39: e27.
3. Ishak KG, Zimmerman HJ. Hepatotoxic effects of the anabolic/androgenic steroids. *Semin Liver Dis* 1987; 7: 230-236.
4. Patil JJ, O'Donohoe B, Loyden CF, Shanahan D. Near-fatal spontaneous hepatic rupture associated with anabolic androgenic steroid use: a case report. *Br J Sports Med* 2007; 41: 462-463.
5. Cordaro FG, Lombardo S, Cosentino M. Selling androgenic anabolic steroids by the pound: identification and analysis of popular websites on the Internet. *Scand J Med Sci Sports* 2011; 21: e247-259.
6. Bahrke MS, Yesalis CE. Abuse of anabolic androgenic steroids and related substances in sport and exercise. *Curr Opin Pharmacol* 2004; 4: 614-620.
7. Erlinger S. Drug-induced cholestasis. *J Hepatol* 1997; 26 Suppl 1: 1-4.
8. Kafrouni MI, Anders RA, Verma S. Hepatotoxicity associated with dietary supplements containing anabolic steroids. *Clin Gastroenterol Hepatol* 2007; 5: 809-812.
9. Yoshida EM, Karim MA, Shaikh JF, et al. At what price, glory? Severe cholestasis and acute renal failure in an athlete abusing stanozolol. *CMAJ* 1994; 151: 791-793.
10. Veneri RJ, Gordon SC. Anabolic steroid-induced cholestasis: choleretic response to corticosteroids. *J Clin Gastroenterol* 1988; 10: 467-468.
11. Fernández-Pérez L, Flores-Morales A, Chirino-Godoy R, et al. Steroid binding sites in liver membranes: interplay between glucocorticoids, sex steroids, and pituitary hormones. *J Steroid Biochem Mol Biol* 2008; 109: 336-343.
12. Schwingel PA, Cotrim HP, Salles BR, et al. Anabolic-androgenic steroids: a possible new risk factor of toxicant-associated fatty liver disease. *Liver Int* 2011; 31: 348-353.
13. Habscheid W, Abele U, Dahm HH. Severe cholestasis with kidney failure from anabolic steroids in a body builder. *Dtsch Med Wochenschr* 1999; 124: 1029-1032 [Article in German].
14. Stimac D, Milić S, Dintinjana RD, et al. Androgenic/Anabolic steroid-induced toxic hepatitis. *J Clin Gastroenterol* 2002; 35: 350-352.
15. Martínez B, Velasco MJ, Pozo A, et al. Cholestatic injury by stanozolol intake. *Rev Esp Enferm Dig* 2006; 98: 219-220 [Article in Spanish].

16. Hymel BM, Victor DW, Alvarez L, et al. Mastabol induced acute cholestasis: A case report. *World J Hepatol* 2013; 5: 133-136.
17. Björnsson E, Olsson R. Outcome and prognostic markers in severe drug-induced liver disease. *Hepatology* 2005; 42: 481-489.
18. Wree A, Dechêne A, Herzer K, et al. Steroid and ursodesoxycholic acid combination therapy in severe drug-induced liver injury. *Digestion* 2011; 84: 54-59.