

Case report

# Successful outcome of therapy of acute hepatitis C following sexual and parenteral exposure – report of two cases

Katarzyna Mazur-Melewska, Anna Mania, Pawel Kemnitz, Magdalena Figlerowicz, Wojciech Służewski

Department of Infectious Diseases and Child Neurology, Poznan University of Medical Sciences, Poznan, Poland

## Abstract

Acute hepatitis C (AHC) remains difficult to diagnose due to its asymptomatic course. The manuscript presents two children with AHC after known sexual and parenteral exposure, which allowed for close monitoring. Both developed increased aminotransferase activity, though the viral load was significantly higher after parenteral exposure. Lack of hepatitis C virus (HCV) clearance led to therapy with recombinant interferon- $\alpha$  with good toleration and response. The conclusion is that treatment of AHC was effective and well tolerated.

**Key words:** acute hepatitis C, children, exposure, treatment.

## Address for correspondence

Anna Mania, Department of Infectious Diseases and Child Neurology, Poznan University of Medical Sciences, 27/33 Szpitalna St., 60-572 Poznań, fax: +48 61 8491 319, e-mail: mania@mp.pl

## Introduction

Hepatitis C virus (HCV) is a significant cause of chronic liver disease worldwide. The acute phase of HCV infection is an unrecognized problem, due to its asymptomatic course and unknown moment of exposure [5]. Common risk factors include intravenous drug use, improperly performed invasive medical procedures and sexual intercourse with HCV-infected partners [8].

Treatment of acute hepatitis C (AHC) with interferon- $\alpha$  is well established. Early interferon- $\alpha$  therapy leads to a sustained virological response (SVR) in 85-98% of infected patients. Thus, studies concerning children are very limited [9].

We present two cases of acute HCV infection from the time of exposure to the initiation of the treatment and further follow-up.

## Case description

### Case 1

A 17-year-old girl was consulted after a sexual assault that occurred a month earlier. Initially, the HCV

infection of the assailant was unknown. The girl, consulted by a gynecologist, was not referred for HIV post-exposure prophylaxis. Consultation was performed a month later when the legal guardians obtained information regarding hepatitis B and C of the assailant. Medical records and a police statement confirmed the exposure. History of vaccination was up-to-date. The anti-HBs titer exceeded 10 IU/l. Anti-HCV and anti-HIV antibodies were negative. The ALT and AST were 44 and 48 IU/l, respectively. Reevaluation occurred every 4 weeks for ALT, AST, anti-HCV and anti-HIV antibodies. On the 90<sup>th</sup> day after the exposure anti-HCV antibodies were found positive. HCV-RNA was  $5.28 \times 10^3$  IU/l and the ALT and AST were 158 and 108 IU/l, respectively. The girl remained asymptomatic for the whole course of observation, complaining only of mild nausea and appetite loss. Slow decline of ALT and AST after 8 weeks was observed. On the 150<sup>th</sup> day after the exposure (the 60<sup>th</sup> day of the confirmed HCV infection) the HCV viral load was  $8.20 \times 10^2$  IU/ml. Due to the decline in the viral load and aminotransferase activity, observation was followed for a month consistently with then

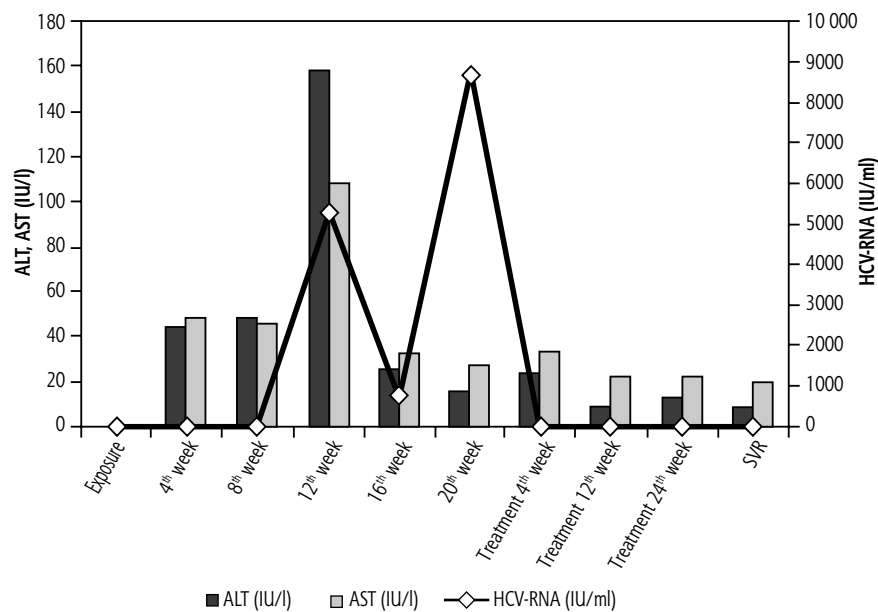


Fig. 1. Aminotransferase activity and HCV-RNA viral load in 17-year-old girl after sexual exposure to HCV and during antiviral treatment

local and EASL guidelines [2]. Nevertheless, on the 180<sup>th</sup> day after the exposure the HCV viral load rose to  $8.72 \times 10^3$  IU/ml although the ALT and AST declined to 16 and 26 IU/l (Fig. 1). The therapy used recombinant interferon- $\alpha$ 2-b indaily doses for the first 4 weeks and was continued for the next 20 weeks 3 times a week. No side effects were observed during the whole therapy. The viral load in the 12<sup>th</sup> week of the therapy was negative; therefore the therapy was continued until the 24<sup>th</sup> week. The patient remained HCV-RNA-negative at the end of the treatment as well as after six months of follow-up.

## Case 2

The 16-year-old boy was accidentally exposed to the serum of a HCV-infected patient during diagnostic procedures performed due to chronic urticaria. Upon discovering the exposure, the patient was found anti-HCV, anti-HIV and HBsAg negative directly after the accident. The anti-HBs titer exceeded 10 IU/l. Serum ALT and AST levels were 12 and 16 IU/l, respectively. HCV-RNA was negative as well. The source of the exposure was tested for potential HIV and HBV infection; therefore no antiretroviral prophylaxis was required at that time. Two weeks later the patient's ALT and AST levels remained normal. Four weeks after the exposure, the patient was still asymptomatic, and no complaints were reported. However, ALT and AST were 93 IU/l and 107 IU/l, respectively. The patient was anti-HCV, anti-HIV and

HBsAg negative. Yet, the HCV-RNA viral load was  $3.92 \times 10^4$  IU/ml. Acute hepatitis C was diagnosed and the patient was observed for the following two weeks. Six weeks after the exposure the patient remained asymptomatic, but his ALT was 571 IU/l, AST 681 IU/l and GGTP 167 IU/l. The patient developed anti-HCV antibodies and the HCV-RNA level was  $5.14 \times 10^6$  IU/ml. Early antiviral treatment was introduced, since the patient seemed unlikely to clear health-care-setting-acquired HCV. The regimen included recombinant interferon- $\alpha$ 2b in daily doses of 3 MIU for the first 4 weeks with subsequent treatment with 3 weekly doses for 20 weeks. HCV-RNA was checked in the 4<sup>th</sup>, 12<sup>th</sup>, and 24<sup>th</sup> weeks of the therapy as well as 6 and 12 months after the end of the treatment, giving negative results (Fig. 2).

## Other cases in the literature

Studies on AHC are rare, as the infection remains infrequently diagnosed at this stage due to its mostly asymptomatic course. The exact moment of exposure is not usually known. Studies of the evolution of HCV infection are based on children of HCV-positive mothers, where the moment of exposure may be easily defined. Although AHC is usually asymptomatic in the majority of infants, a fatal outcome of the infection in a neonate was also described [4]. A significant proportion of these children spontaneously clear the virus; thus if features of HCV infection persist longer than 6 months, chronic infection is diagnosed.

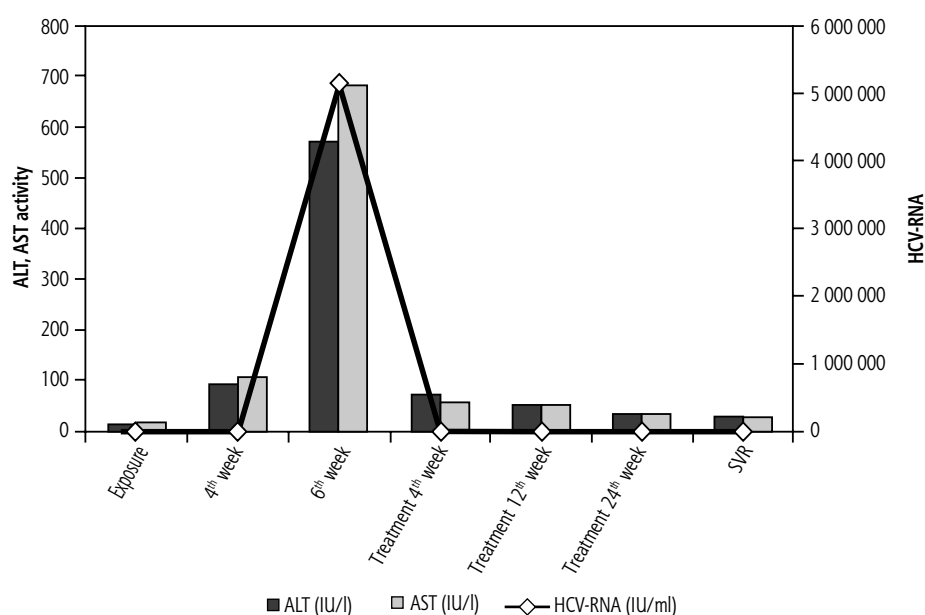


Fig. 2. Aminotransferase activity and HCV-RNA viral load in 13-year-old boy after iatrogenic parenteral exposure to HCV and during antiviral treatment

## Discussion

Developing an immune response after HCV infection becomes the main force influencing the viral population. Homogeneous HCV viral populations are associated with a high degree of liver injury, while heterogeneous quasispecies are related to lower ALT activity and milder liver injury [3]. In both described patients nearly the exact moment of exposure was defined. The patient with iatrogenic exposure was immediately tested, with evaluation of his status prior to HCV contact, while the patient with sexual exposure waited a whole month for the tests.

The extent to which HCV is transmitted by sexual intercourse depends on the circumstances. Published studies show conflicting results providing limited evidence of HCV transmission between spouses and numerous infections among patients with multiple sexual partners [7, 10]. Therefore, HCV testing should be performed (along with HIV and HBV tests) after sexual assaults, even if the infection status of the source is not known. Moreover, an increasing number of HCV infections has been noted in recent years in adolescents receiving intravenous drugs [7].

Parenteral exposure results in a much larger amount of the virus introduced to the organism of the host. In both patients an increase in aminotransferase activity and HCV-RNA level was observed; thus the boy infected by the parenteral route developed much higher values.

Strategies for AHC management have been based on the likelihood of spontaneous HCV clearance. Variable proportions of spontaneous HCV clearance were partially elucidated by a single nucleotide polymorphism upstream of the IL28B gene. Also, female gender, jaundice during AHC and significant decline of HCV-RNA within the first 4 weeks were associated with subsequent HCV clearance [1]. Therefore, close initial monitoring of immunocompetent individuals is recommended with serial testing of ALT and HCV-RNA. If the viral load is not declining by at least 2 log or remains detectable for more than 12 weeks, treatment using pegylated interferon- $\alpha$  (or recombinant if pegylated is unavailable) is recommended. If the patient is not likely to spontaneously clear the virus, the therapy should be offered earlier [1].

In both cases antiviral treatment was implemented after the observation period aiming at potential spontaneous viral clearance according to EASL and local guidelines [6]. Both patients responded well to antiviral treatment, which was well tolerated and effective. Therefore, children and adolescents should be managed in a manner approved in adults.

In the era of directly acting antivirals the management of AHC may change significantly, giving future therapeutic options for patients with contraindications to interferon treatment.

## Funding

The study was supported by a Polish National Center of Science grant to AM – NN 407012036.

---

## Disclosure

---

Authors report no conflict of interest.

## References

1. Beinhardt S, Payer BA, Datz C, et al. A diagnostic score for the prediction of spontaneous resolution of acute hepatitis C virus infection. *J Hepatol* 2013; 59: 972-977.
2. European Association for the Study of the Liver. EASL Clinical Practice Guidelines: management of hepatitis C virus infection. *J Hepatol* 2011; 55: 245-264.
3. Jackowiak P, Kuls K, Budzko L, et al. Phylogeny and molecular evolution of the hepatitis C virus. *Infect Genet Evol* 2014; 21: 67-82.
4. Kowala-Piaskowska A, Figlerowicz M, Mozer-Lisewska I, et al. Vertical transmission of hepatitis C virus infection. *Hepatol Res* 2004; 30: 137-140.
5. Lavanchy D. The global burden of hepatitis C. *Liver Int* 2009; 29 (Suppl 1): 74-81.
6. Pawlotsky JM, Aghemo A, Dusheiko G, et al. EASL Clinical Practice Guidelines: management of hepatitis C virus infection. European Association for Study of Liver. *J Hepatol* 2014; 60: 392-420.
7. Terrault NA, Dodge JL, Murphy EL, et al. Sexual transmission of hepatitis C virus among monogamous heterosexual couples: the HCV partners study. *Hepatology* 2013; 57: 881-889.
8. Thursz M, Fontanet A. HCV transmission in developed countries and resource constrained areas. *Nat Rev Gastroenterol Hepatol* 2013; 11: 28-35.
9. Wiegand J, Deterding K, Cornberg M, et al. Treatment of acute hepatitis C: the success of monotherapy with (pegylated) interferon alpha. *J Antimicrob Chemother* 2008; 62: 860-865.
10. Zibbell JE, Hart-Malloy R, Barry J, et al. Risk factors for HCV infection among young adults in rural New York who inject prescription opioid analgesics. *Am J Public Health* 2014; 104: 2226-2232.