

## Endophthalmitis following cataract surgery in diabetic patients

HANAPI MAYA-SAPIRA<sup>1, A-F</sup>, YI-NI KOH<sup>1, A-F</sup>, YAAKUB AZHANY<sup>1, A-F</sup>, EMBONG ZUNAINA<sup>1, A-F</sup>, SONNY-TEO KHAIRY-SHAMEL<sup>1, D, E</sup>, AHMAD TAJUDDIN LIZA-SHARMINI<sup>1, B, D</sup>, NANI DRAMAN<sup>2, D, E</sup>, ZAMRI NOORDIN<sup>3, B, D</sup>

<sup>1</sup> Department of Ophthalmology, School of Medical Sciences, Universiti Sains Malaysia, Kubang Kerian, Kelantan, Malaysia

<sup>2</sup> Department of Family Medicine, School of Medical Sciences, Universiti Sains Malaysia, Kubang Kerian, Kelantan, Malaysia

<sup>3</sup> Department of Ophthalmology, Hospital Raja Perempuan Zainab II, Kota Bharu, Kelantan, Malaysia

A – Study Design, B – Data Collection, C – Statistical Analysis, D – Data Interpretation, E – Manuscript Preparation, F – Literature Search, G – Funds Collection

**Summary Background.** Endophthalmitis post cataract surgery is rare, but the incidence and complications are higher in diabetics.

**Objectives.** We present 3 diabetic patients who underwent cataract surgery and developed endophthalmitis postoperatively.

**Material and methods.** This is a retrospective case series of diabetic patients who underwent cataract surgery and developed endophthalmitis postoperatively between September 2015 and August 2016. The medical records were retrieved from the system, and data was collected.

**Results.** The patients eventually had different visual outcomes depending on the severity of endophthalmitis. Case 1. The patient developed delayed subtle postoperative endophthalmitis at 8 weeks post cataract operation, with underlying foot cellulitis and poor blood sugar control. The patient responded well to topical and systemic antibiotics and stabilization of blood sugar. Case 2. The patient presented with delayed postoperative endophthalmitis secondary to a suture abscess of the cataract wound at 7 months post implantation of an anterior chamber intraocular lens. There was complete resolution of the infection after administration of topical, intravitreal and systemic antibiotics, with a good control of blood sugar. Case 3. The patient presented with acute severe postoperative endophthalmitis with the presence of hypopyon at day 5 following cataract surgery. There were no obvious risk factors besides poor control of blood sugar, but *Streptococcus mitis* was isolated from the vitreous specimen. The endophthalmitis worsened in spite of topical, intravitreal and systemic antibiotics, as well as vitrectomy. Evisceration was eventually performed for the painful blind eye.

**Conclusions.** Although endophthalmitis following cataract surgery is rare, the incidence and complications are much higher in diabetic patients.

**Key words:** endophthalmitis, cataract surgery, diabetes mellitus, *Streptococcus mitis*.

Maya-Sapira H, Koh Y-N, Azhany Y, Zunaina E, Khairy-Shamel S-T, Liza-Sharmini AT, Draman N, Noordin Z. Endophthalmitis following cataract surgery in diabetic patients. *Fam Med Prim Care Rev* 2017; 19(4): 431–436, doi: <https://doi.org/10.5114/fmPCR.2017.70821>.

### Background

Postoperative infectious endophthalmitis is an intraocular inflammation caused by an infective process that occurs following intraocular surgery, which accounts for significant visual morbidity [1]. Acute postoperative infectious endophthalmitis usually presents within 2 weeks of surgery, whereas delayed-onset infectious endophthalmitis usually present with onset ranges from 4 weeks to years following surgery [2]. Cataract surgery has become one of the most prevalent surgical procedures worldwide, mainly due to changes in population structure and increased life expectancy. A study by Congdon et al. revealed that cases of a cataract in the United States are estimated to increase from 20 million in 2000 to 30 million in 2020 [3]. Similarly, in Malaysia, a cataract is the main cause of blindness (58%) and low vision (68%), based on the National Eye Survey 2014 [4].

Cataract surgery, being the most common performed ocular surgery, is the most common type of surgery preceding endophthalmitis. In Malaysia, the rate of postoperative endophthalmitis following cataract surgery, based on the National Cataract Surgery Registry of Ministry of Health hospitals, was 0.19% in

2002, 0.24% in 2003 and 0.16% in 2004 [1]. Various risk factors have been identified that cause endophthalmitis, and diabetes is one of the important risk factors. A review of literature suggests that persons with diabetes are at increased risk of developing endophthalmitis after intraocular surgery. Previous reports showed that 14% to 21% of patients with endophthalmitis were diabetic [5, 6].

Generally, diabetes mellitus is a systemic condition that potentially has an effect on the severity of endophthalmitis, and as literature has shown, diabetic patients have confirmed growth in cultures more often than non-diabetic patients (84.5% vs 66.8%) [7]. Patients with diabetes mellitus have altered immunity in the body system, which leads to increased risk of developing endophthalmitis [8].

Disturbances in cellular innate immunity play an important role in the pathogenesis of the increased prevalence of infections in diabetic patients. This is probably due to decreased functions (chemotaxis, phagocytosis, killing) of polymorphonuclear cells and monocytes/macrophages in diabetic patients. A study by Le-cube et al. stated that the extent of impairment of phagocytosis in patients with diabetes mellitus oscillates in relation to glycemic



control. Therefore, persistently poor diabetic control could have a progressively deleterious effect, predisposing affected individuals to an increased incidence and severity of infection [9].

The occurrence, clinical presentation and severity of postoperative endophthalmitis depends on the route of infection, the virulence and number of inoculated pathogens, the patient's immune state, as well as the timing of initial presentation [10]. However, the outcome of postoperative infectious endophthalmitis has generally improved in recent years, as a result of better understanding of the disease process, pathogenicity of the organisms and host defense mechanisms, coupled with the availability of better drugs, intravitreal drug therapy and vitrectomy.

## Objectives

The purpose of our case series is to describe various clinical presentations of postoperative endophthalmitis, specifically post cataract surgery, with underlying diabetes mellitus, in our local hospital setting.

## Material and methods

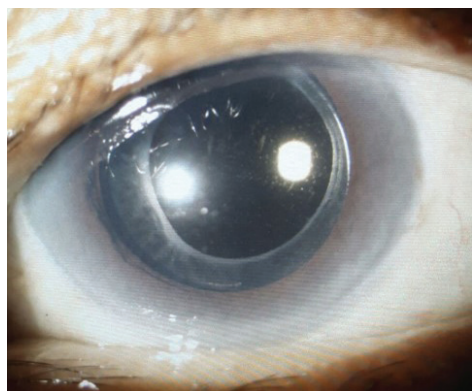
This is a retrospective case series of diabetic patients who underwent cataract surgery and developed endophthalmitis postoperatively between September 2015 and August 2016. The medical records were retrieved from the system, and data was collected.

## Results

### Case 1

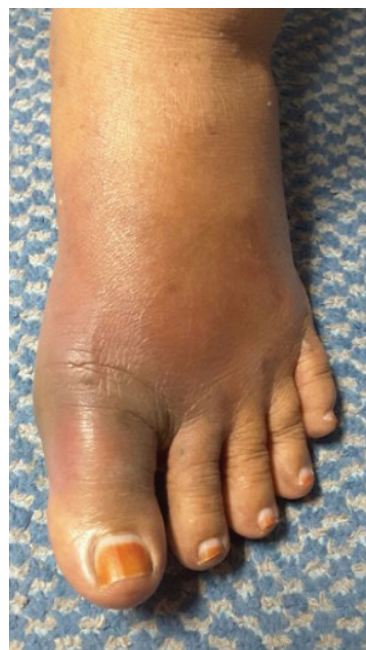A 65-year-old female who was a known case of diabetes mellitus for 10 years with good control of blood sugar with a latest HbA<sub>1c</sub> result of 6.8% presented with an immature cataract and moderate non-proliferative diabetic retinopathy in both eyes. Her visual acuity over the right eye was 6/30, and the left eye was 6/120. She had an uneventful phacoemulsification and posterior chamber intraocular lens (IOL) implantation in her left eye. However, her left eye visual acuity was 6/45 postoperatively due to significant postoperative corneal edema. The patient was treated with guttae prednisolone 2 hourly and guttae moxifloxacin 2 hourly, and the medications were tapered down gradually over 6 weeks.

At 6 weeks postoperatively, her left visual acuity was 6/18, with resolution of anterior chamber inflammation and corneal edema. However, at 8 weeks postoperatively, she complained of left eye redness with a duration of 2 days. This was associated with purulent discharge and reduced vision. Her left eye visual acuity deteriorated to 6/24. There was the presence of a ciliary injection and moderate inflammation in the anterior chamber, with an absence of hypopyon and vitritis (Photo 1).



**Photo 1.** The left eye showed moderate inflammation of the anterior chamber with an absence of hypopyon (case 1)

Upon further questioning, the patients claimed she had a left big toe swelling for a week prior to the eye redness. This was associated with low grade fever. Examination of the left foot showed diffuse swelling over the big toe area, extending up to the ankle, with surrounding skin inflammation (Photo 2). There was tenderness at the medial side of the foot, but the swelling did not fluctuate, and there was an absence of pus discharge. A plain radiograph of the left foot showed soft tissue swelling, suggestive of soft tissue inflammation, without evidence of osteomyelitis. Systemically, the patient was afebrile with stable vital signs.



**Photo 2.** The left foot showed cellulitis and was swollen and inflamed over the right big toe area at presentation (Case 1)

The patient was treated as delayed subtle postoperative endogenous endophthalmitis in her left eye with left foot cellulitis. She was given intravitreal ciprofloxacin 400 mg 12 hourly and C-penicillin 2.4 mega unit 6 hourly for 1 week. For the left eye, the patient was treated with guttae moxifloxacin 2 hourly and guttae prednisolone 2 hourly. In view of no posterior segment involvement, an intravitreal antibiotic was not administered.

While in the ward, her glucometer was unstable, ranging from 4 to 11 mmol/L. Besides continuing her oral hypoglycemic agents, she also was started on an injection of insulatard (10 unit on a nightly basis). The blood sugar was stable after optimization of treatment.

At 1 week post treatment, her left visual acuity improved to 6/18, with a significant reduction in anterior chamber inflammation. Her left foot cellulitis resolved concurrently. She was discharged after a week with oral cloxacillin 500 mg 6 hourly and oral ciprofloxacin 500 mg 12 hourly for another 1 week. Guttae moxifloxacin and prednisolone were tapered down to 4 hourly for a 1 month duration. Her visual acuity was 6/18 at the subsequent follow-up, and there were no signs or symptoms of endophthalmitis.

### Case 2

A 51-year-old Chinese male who was diagnosed to have diabetes mellitus for 10 years with good control of blood sugar underwent an uneventful bilateral cataract operation with IOL implantation 15 years ago and had good vision postoperatively.

He presented with painless blurring of vision in the left eye for a 1 year duration. His visual acuity worsened from 6/9 to 6/60 over the affected period. Ocular assessment revealed an

inferior subluxation of the posterior chamber IOL. He underwent an extraction of the subluxated posterior chamber IOL followed by implantation of an anterior chamber IOL. At 1 month postoperatively, his visual acuity improved to 6/6, with resolution of postoperative inflammation.

Seven months later, he presented with left eye redness for a 1 month duration. It was associated with eye discharge and blurring of vision. His left visual acuity deteriorated from 6/6 to 6/18. An ocular examination revealed an injected conjunctiva with the presence of a suture abscess at the superior part of the corneal limbal wound. There was the presence of moderate anterior chamber inflammation without hypopyon or vitritis. A diagnosis of delayed postoperative endophthalmitis was made. He was started on intravenous ciprofloxacin 400 mg 12 hourly, guttae moxifloxacin 2 hourly and guttae prednisolone 2 hourly. An eye swab of the suture abscess was taken prior instillation of topical antibiotic. A left eye intravitreal tap was immediately done followed by intravitreal antibiotics (vancomycin 2 mg /0.1 ml and ceftazidime 2 mg/0.1 ml). His visual acuity improved to 6/9 after 4 days of treatment. There was resolution of the suture abscess, with reduction of anterior chamber inflammation. An eye swab and vitreous specimen showed no growth of microorganisms.

Systemic ciprofloxacin was continued with oral administration for another 1 week 7 days after completion of intravenous ciprofloxacin. Guttae moxifloxacin and prednisolone were tapered down gradually over a period of 1 month. His blood glucose was well controlled with HbA<sub>1c</sub> of 6%. At the 1 month follow-up, his visual acuity improved to 6/7.5 and remained stable during subsequent reviews. There were no signs or symptoms of endophthalmitis observed during the last 5 month follow-up.

### Case 3

A 67-year-old male with underlying diabetes mellitus and ischemic heart disease underwent cataract surgery on his right eye. The operation was complicated, with a posterior capsule rupture, but an anterior chamber IOL was successfully implanted. Day 1 postoperatively, the right eye visual acuity was 6/36. He was discharged with guttae prednisolone 2 hourly, guttae moxifloxacin 2 hourly and guttae nepafenac 8 hourly over the right eye and was given a follow-up date of 1 week postoperatively. The blood sugar was well controlled during the admission period and also on the day of discharge.

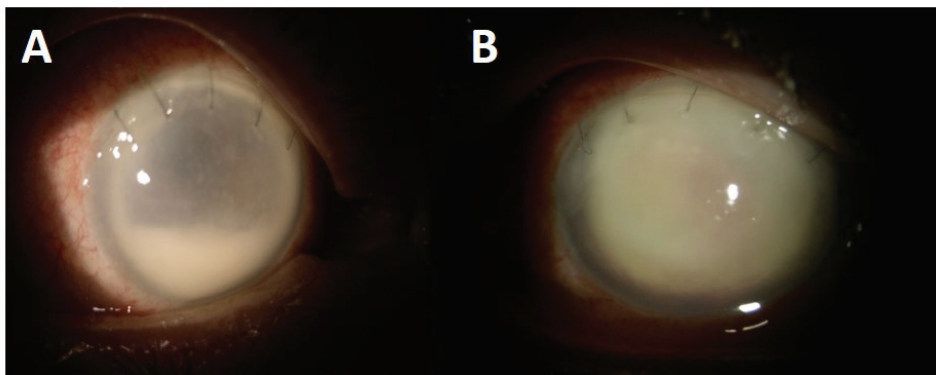
However, on day 5 postoperatively, he presented with painful loss of vision in the right eye for a 1-day duration. This was

associated with eye redness, but no eye discharge. He denied a history of recent ocular trauma or possible risk of systemic infection. His right eye vision subsequently deteriorated to perception to light. An ocular examination revealed swollen eyelids, chemosis and an injected conjunctiva. The cornea was hazy with a 4 mm level of hypopyon in the anterior chamber (Photo 3A). Seidel sign was negative over the surgical wound, with no corneal epithelial defect, eye discharge, suture abscess or vitreous incarceration seen at the surgical site. He was hemodynamically stable and afebrile. The capillary blood sugar was 12.7 mmol/L with HbA<sub>1c</sub> of 9.9%. A further ocular examination revealed good lid hygiene with no signs of possible infection, such as nasolacrimal blockage or surrounding skin infection. He had no evidence of diabetic complications, and other systemic co-morbidities were well controlled.

A diagnosis of acute postoperative endophthalmitis was made, and intravitreal antibiotics (vancomycin 2 mg /0.1 ml and ceftazidime 2 mg /0.1 ml) were given immediately to the right eye after performing an intravitreal tap. However, the vitreous sample was clear, and the culture did not yield any growth. He was also started on intravenous ciprofloxacin 400 mg 12 hourly, intravenous ceftazidime 2 g 8 hourly, guttae moxifloxacin hourly and guttae ceftazidime hourly. A urine and blood culture for bacteria and fungus showed no growth.

Despite intensive topical and systemic treatment, the patient's right eye condition worsened rapidly with total hypopyon noted two days later (Photo 3B). He was then referred to the vitreoretinal team for vitrectomy. The patient underwent right eye limited anterior vitrectomy, explantation of anterior chamber IOL and intravitreal antibiotic (vancomycin 2 mg /0.1 ml and ceftazidime 2 mg /0.1 ml). Intraoperative findings showed a very dense hypopyon adhered to the corneal endothelium, dense vitreous opacity and extrusion of necrotic tissue upon explantation of the anterior chamber IOL. A vitreous specimen from vitrectomy, as well as eye swab, revealed *Streptococcus mitis*. There was a poor response despite intensive treatment, and his right eye condition deteriorated to no perception to light. At 1 month post vitrectomy, there was reaccumulation of hypopyon in the right eye, and it progressively became phthisical. He unfortunately underwent enucleation for a painful blind eye at 2 months post vitrectomy.

The summary of the onset of endophthalmitis post cataract surgery, status of diabetes mellitus, risk factors, vision at presentation and final vision, treatment and the outcome of the 3 cases are shown in Table 1.



**Photo 3.** The right eye showed chemotic and injected conjunctiva, cloudy cornea with 4 mm level of hypopyon in the anterior chamber (A) and worsened rapidly with total hypopyon (B) (Case 3)

**Table 1. Summary of the endophthalmitis cases following cataract surgery in diabetic patients**

|  | Case 1  | Case 2   | Case 3  |
|--|---|--|---|
| Age (year)                                     | 65  | 51   | 67  |
| Gender   | Female  | Male   | Male  |
| Postoperative endophthalmitis status           | Delayed subtle postoperative endogenous endophthalmitis                                     | Delayed postoperative endophthalmitis  | Acute postoperative endophthalmitis   |
| Onset of endophthalmitis post cataract surgery | 8 weeks   | 7 months   | 5 days  |
| Status of diabetes mellitus                    | HbA <sub>1c</sub> : 6.8%<br>Blood sugar: 4–11 mmol/L  | HbA <sub>1c</sub> : 6.0%<br>Blood sugar: good control  | HbA <sub>1c</sub> : 9.9%<br>Blood sugar: 12.7 mmol/L  |
| Risk factor                                    | Left foot cellulitis  | Suture abscess of the cataract wound   | Poor diabetic control   |
| Presenting vision                              | 6/24  | 6/18   | Perception of light   |
| Final vision                                   | 6/18  | 6/7.5  | No perception of light  |
| Treatment                                      | Eye drop antibiotic (moxifloxacin)<br><br>Systemic antibiotic (ciprofloxacin, C-penicillin) | Eye drop antibiotic (moxifloxacin)<br><br>Intravitreal antibiotic (vancomycin, ceftazidime)<br><br>Systemic antibiotic (ciprofloxacin) | Eye drop antibiotic (moxifloxacin, ceftazidime)<br><br>Intravitreal antibiotic (vancomycin, ceftazidime)<br><br>Systemic antibiotic (ciprofloxacin, ceftazidime)<br><br>Vitrectomy and explantation of intraocular lens<br><br>Evisceration |
| Outcome  | Good  | Good   | Poor  |

## Discussion

Postoperative infectious endophthalmitis is a rare but devastating condition which can lead to blindness. Postoperative infectious endophthalmitis may present as two distinct entities: early or acute endophthalmitis, which occur within a few days of the procedure; and chronic or delayed endophthalmitis, which can present several weeks to months after surgery with more subtle symptoms. In Case 1 and 2, the patients presented with a subtle anterior chamber reaction with no vitritis seen and relatively good initial visual acuity clinically. On the other hand, Case 3 presented early, within a few days after surgery, with very severe infection and poor initial visual acuity. Studies showed that an initial visual acuity level has a good correlation with the visual prognosis [11, 12], and this was one of the most important prognostic factors stated in the Endophthalmitis Vitrectomy Study (EVS) [7]. It may be useful for clinicians by identifying prognostic factors of poor visual outcome at presentation, because these patients would probably benefit from more aggressive treatment.

Differential diagnosis of acute severe inflammation in the immediate postoperative period includes infection, surgical trauma, toxic anterior segment syndrome (TASS), retained lens fragments and uveitic syndromes. Although the clinical distinction between these conditions can sometimes be difficult, infection must be first ruled out, because a slight delay in treatment can result in irreversible severe vision loss. On the other hand, endogenous infection and masquerade syndromes are among the differential diagnosis of chronic postoperative endophthalmitis. To aid in diagnosis and management, vitreous sampling for culture and sensitivity is essentially important. As established by the EVS, the initial treatment of post cataract surgery endophthalmitis is specimen collection and antibiotic administration. A vitreous specimen is preferred, as this roughly doubles the diagnostic yield compared to an aqueous specimen (54.9% vs 22.5%) [13].

Studies by Combey de Lambert et al. [14] and EVS [7] both identified bacterial virulence as one of the main independent factors of visual outcome, which shows the influence of bacterial virulence on final visual prognosis, by taking into account baseline clinical factors. A report by Combey de Lambert et al. showed that culture-negative cases are usually associated with a better final visual outcome [14]. This is probably due to culture negative cases having a relatively lower level of inoculum, which were undetected by conventional cultures or PCR techniques despite infection. Similarly, in our case series, only Case 3, with the most severe initial presentation, showed positive culture results with a *Streptococcus mitis* yield from the eye swab and vitreous sampling culture. This patient had the worst final visual outcome, which was no perception to light, as compared to Case 1 and 2, with a final visual acuity of 6/18 and 6/7.5, respectively.

A review of literature showed that approx. 14 to 21% of all patients who develop postoperative endophthalmitis after cataract operations are diabetic patients [11, 15]. Diabetic patients who developed endophthalmitis after cataract surgery tend to have poorer visual outcome, especially if diabetic retinopathy is present pre-operatively [15]. However, other studies stated that pre-existing diabetes mellitus has not yet been confirmed as an isolated risk factor for postoperative infectious endophthalmitis after cataract surgery [7, 16].

In EVS, endophthalmitis patients with diabetes mellitus particularly benefited from vitrectomy, even when their initial vision was better than light perception [7]. EVS also stated that visual acuity at initial presentation was the most powerful predictor of visual outcome and of whether or not patients were likely to benefit from vitrectomy. This is probably because the vision at initial presentation reflected the virulence of the infecting microorganism, as well as the duration of the infection and the host's response to the infection. Thus, relative to microbiological results, presenting visual acuity appears to provide a more accurate basis for judging the value of immediate vitrectomy in acute bacterial endophthalmitis after cataract surgery or secondary IOL implantation [17]. In our case series, only Case 3, with

initial visual acuity of only light perception, proceeded with vitrectomy. However, in this case, vitrectomy did not improve the final visual outcome.

To the best of our knowledge, there is no review of literature suggesting the correlation between diabetic control and the incidence of postoperative infectious endophthalmitis. The association between glycemic control and the type of endophthalmitis was unclear and is yet to be determined. Most, but not all, literature suggested that diabetic patients are at increased risk of developing endophthalmitis after intraocular surgery [6, 8]. Nevertheless, there are many other potential pre-operative, intra-operative and postoperative risk factors which may contribute to the occurrence of postoperative infectious endophthalmitis [1].

As the ocular surface is a common source of pathogens, various measures have been used to prepare the ocular surface before surgery to reduce normal ocular surface flora. Antiseptic measures, such as instillation of a topical 5% povidone iodine solution into the conjunctival sac just before surgery, significantly reduced the incidence of culture positive endophthalmitis. On top of this, an intracameral injection of 1 mg cefuroxime in 0.1 ml of 0.9% sterile sodium chloride solution at the end of phacoemulsification surgery has been shown to significantly re-

duce the risk of postoperative endophthalmitis up to five-fold in a multicenter European study [1, 16]. Thus, improvement in surgical techniques, equipment sterilization, antiseptic measures and antibiotic prophylaxis will definitely reduce the risk of developing postoperative endophthalmitis in both diabetic and non-diabetic patients.

However, perioperative blood glucose control is still necessary in diabetic patients. Education on the importance of perioperative blood sugar optimization is crucial. Rapid correction of blood glucose should be avoided in patients with moderate to severe non-proliferative diabetic retinopathy, as it may increase the risk of postoperative progression of retinopathy and maculopathy, thus influence the postoperative visual prognosis [18]. Hence, better education and co-management with physicians and family doctors is necessary.

## Conclusions

Although endophthalmitis following cataract surgery is rare, the incidence and complications are much higher in diabetic patients. Visual acuity at presentation is the predictor of the visual outcome. Awareness of early detection and public health education of this disease are very crucial, as these will prevent subsequent complications of blindness or death.

Source of funding: This work was funded by the authors' own resources.

Conflict of interest: The authors declare no conflict of interests.

## References

1. Clinical practice guideline, management of post-operative infectious endophthalmitis. Ministry of Health Malaysia; 2008 [cited 10.11.2016]. Available from URL: <http://www.acadmed.org.my>.
2. Bowling B. *Kanski's Clinical Ophthalmology: a systematic approach*. 8 ed. Philadelphia: Elsevier & Saunders; 2015: 292.
3. Congdon N, Vingerling JR, Klein BE, et al. Prevalence of cataract and pseudophakia/aphakia among adults in the United States. *Arch Ophthalmol* 2004; 122(4): 487–494.
4. MSO Express: Session 2 Plenary Lecture 1. *Newsletter of Malaysian Society of Ophthalmology* (May 2016): 1.25 May 2016. Web [cited 08.11.2016]. Available from URL: <http://mso.org.my/newsmaster.cfm?&menuid=45&action=view&retrieveid=1>.
5. Cohen SM, Flynn HW Jr, Murray TG, et al. Endophthalmitis after pars plana vitrectomy: the Postvitrectomy Endophthalmitis Study Group. *Ophthalmology* 1995; 102(5): 705–712.
6. Montan PG, Koranyi G, Setterquist HE, et al. Endophthalmitis after cataract surgery: risk factors relating to technique and events of the operation and patient history. *Ophthalmology* 1998; 105(12): 2171–2177.
7. Doft BH, Wisniewski SR, Kelsey SF, et al. Diabetes and postoperative endophthalmitis in the Endophthalmitis Vitrectomy Study. *Arch Ophthalmol* 2001; 119(5): 650–656.
8. Casqueiro J, Casqueiro J, Alves C. Infections in patients with diabetes mellitus: a review of pathogenesis. *Indian J Endocrinol Metab* 2012; 16(Suppl. 1): S27–S36, doi: 10.4103/2230-8210.94253.
9. Lecube A, Pachón G, Petriz J, et al. Phagocytic activity is impaired in type 2 diabetes mellitus and increases after metabolic improvement. *PLoS ONE* 2011; 6: e23366, doi: 10.1371/journal.pone.0023366.
10. Peyman G, Lee P, Seal DV. *Endophthalmitis: diagnosis and management*. London: Taylor & Francis Group; 2004: 1–270.
11. Lalwani GA, Flynn HW Jr, Scott IU, et al. Acute-onset endophthalmitis after clear corneal cataract surgery (1996–2005): clinical features, causative organisms, and visual acuity outcomes. *Ophthalmology* 2008; 115(3): 473–476.
12. Wu PC, Kuo HK, Li M, et al. Nosocomial postoperative endophthalmitis: a 14-year review. *Graefes Arch Clin Exp Ophthalmol* 2006; 244(8): 920–929.
13. Barza M, Pavan PR, Doft BH, et al. Evaluation of microbiological diagnostic techniques in postoperative endophthalmitis in the Endophthalmitis Vitrectomy Study. *Arch Ophthalmol* 1997; 115: 1142–1150.
14. Combey de Lambert A, Campolmi N, Cornut PL, et al. Baseline factors predictive of visual prognosis in acute postoperative bacterial endophthalmitis in patients undergoing cataract surgery. *JAMA Ophthalmol* 2013; 131(9): 1159–1166, doi: 10.1001/jamaophthalmol.2013.4242.
15. Dev S, Pulido JS, Tessler HH, et al. Progression of diabetic retinopathy after endophthalmitis. *Ophthalmology* 1999; 106(4): 774–781.
16. Endophthalmitis Study Group, European Society of Cataract and Refractive Surgeons. Prophylaxis of postoperative endophthalmitis following cataract surgery: results of the ESCRS multicenter study and identification of risk factors. *Journal Cataract Refract Surg* 2007; 33(6): 978–988.
17. The Endophthalmitis Vitrectomy Study Group. Microbiologic factors and visual outcome in the Endophthalmitis Vitrectomy Study. *Am J Ophthalmol* 1996; 122(6): 830–846.
18. Suto C, Hori S, Kato S, et al. Effect of perioperative glycemic control in progression of diabetic retinopathy and maculopathy. *Arch Ophthalmol* 2006; 124(1): 38–45.

Tables: 1

Photographs: 3

References: 18

Received: 10.04.2017  
Revised: 22.06.2017  
Accepted: 24.06.2017

Address for correspondence:  
Embong Zunaina, MD  
Department of Ophthalmology  
School of Medical Sciences  
Universiti Sains Malaysia  
16150 Kubang Kerian, Kelantan  
Malaysia  
Tel.: + 6 09 767 6362  
E-mail: zunaina@usm.my