

Induction chemotherapy plus nimotuzumab followed by concurrent chemoradiotherapy for advanced nasopharyngeal carcinoma

Xinmao Song¹, Shengzi Wang¹, Ji Li¹, Li Yan¹, Fu Chen¹, Jie Wang²

¹Department of Radiation Oncology, Eye, Ear, Nose and Throat Hospital of Fudan University, Shanghai, China

²Department of Otorhinolaryngology, Eye, Ear, Nose and Throat Hospital of Fudan University, Shanghai, China

Submitted: 19 May 2018

Accepted: 26 September 2018

Arch Med Sci

DOI: <https://doi.org/10.5114/aoms.2019.86712>

Copyright © 2019 Termedia & Banach

Corresponding author:

Shengzi Wang
Department of Radiation
Oncology
Eye, Ear, Nose and Throat
Hospital of Fudan University
83 Fenyang Road
Shanghai 200031, China
Phone: +86 15900898809
Fax: +86 21-64377151
E-mail: shengziwang@fudan.
edu.cn

Abstract

Introduction: This study investigated the best mode for the application of nimotuzumab (Nimo) in combination with chemoradiotherapy to treat nasopharyngeal carcinoma (NPC).

Material and methods: Data were prospectively collected from 168 patients with NPC from September 2009 to February 2014. One hundred twelve patients received 2–3 cycles of induction chemotherapy (IC) followed by concurrent chemoradiotherapy (CCRT), and 56 patients with well-matched propensity scores received IC + CCRT + Nimo. Patients were divided into 3 subgroups according to the application schedule of Nimo: group A, IC + CCRT; group B: IC (combined with Nimo) + CCRT; and group C: IC + CCRT (combined with Nimo). The 5-year overall survival (OS) and progression-free survival (PFS) and adverse events were investigated.

Results: With a median follow-up of 61.4 months (range: 1.7–96.5 months), the 5-year OS and PFS for group A vs. groups B + C were $74.8 \pm 4.1\%$ versus $87.0 \pm 4.6\%$ ($p = 0.043$) and $72.7 \pm 4.3\%$ vs. $83.1 \pm 5.1\%$ ($p = 0.243$), respectively. The 5-year OS of group B was significantly improved over that of group A ($93.0 \pm 4.8\%$ vs. $74.8 \pm 4.1\%$, $p = 0.038$); however, there was no benefit to the 5-year PFS ($89.3 \pm 5.9\%$ vs. $72.7 \pm 4.3\%$, $p = 0.144$). The 5-year OS and PFS for group C were $80.4 \pm 7.9\%$ and $76.4 \pm 8.5\%$, respectively, and there was no statistically significant difference from group A ($p = 0.257$ and $p = 0.611$, respectively). No significant increase in toxicities was observed with the addition of Nimo.

Conclusions: Nimo administered with chemoradiotherapy is effective for NPC. Nimo concurrent with IC followed by CCRT could be the optimal mode of sequential treatment.

Key words: nasopharyngeal carcinoma, induction chemotherapy, concurrent chemoradiotherapy, monoclonal antibody.

Introduction

Radiation therapy is the mainstay of definitive therapy for non-metastatic nasopharyngeal carcinoma (NPC). However, it only successfully controls 50–70% of advanced tumors, and local recurrence and distant metastasis are the major causes of treatment failure. Multiple studies have reported the use of chemotherapy in combination with radiotherapy for the management of locoregionally advanced NPC [1], as NPC is sensitive to chemotherapy.

Targeted therapy has been the main focus of cancer research in the past decade, and more than 10 targeted therapeutic agents are approved by the Food and Drug Administration annually. Molecular targeted therapies, including epidermal growth factor receptor (EGFR) monoclonal antibodies, EGFR tyrosine kinase inhibitors, and vascular endothelial growth factor receptor inhibitors, have shown potential for treating head and neck cancer [2].

Epidermal growth factor receptor is a receptor tyrosine kinase of the ErbB family that plays a critical role in cellular proliferation, differentiation, and survival. Epidermal growth factor receptor is commonly overexpressed or abnormally activated in squamous cell carcinoma of the head and neck, and it is an ideal target for anti-cancer therapy. Epidermal growth factor receptor overexpression is found in more than 80% of patients with locoregionally advanced NPC, and it is associated with shorter survival. Therefore, administration of an anti-EGFR monoclonal antibody is a feasible strategy in locoregionally advanced NPC [3]. However, anti-EGFR molecular-targeted therapies in the clinical treatment of NPC are not an adequate alternative to traditional platinum-based chemotherapy, and their role is only to strengthen the synergy of radiotherapy and chemotherapy. Therefore, they are used mainly in combination with radiotherapy or chemoradiotherapy. Nimotuzumab (Nimo, h-R3), a humanized monoclonal antibody against EGFR, has significant anti-tumor, pro-apoptotic, anti-angiogenic, and radiosensitizing activities. There are emerging data demonstrating the benefits of Nimo in different cancer types [4, 5].

Little is known about the application of Nimo in NPC during a long course of chemoradiotherapy. Moreover, the appropriate timing and best sequential mode to achieve the greatest clinical benefit of combination therapy are unknown. Some retrospective studies have reported that Nimo combined with concurrent chemoradiotherapy (CCRT) shows encouraging outcomes in the treatment of locally advanced NPC, with no increased toxicity and an improved tolerance [6–8]. However, it is unclear whether Nimo combined with induction chemotherapy (IC) or CCRT is the best option. To answer this question, we designed a prospective study to investigate the best mode of Nimo in combination with chemoradiotherapy in the treatment of NPC.

Material and methods

Study subjects

Patients diagnosed with NPC between September 2009 and February 2014 at our institution were considered for enrollment. Inclusion criteria were as follows: 17–73 years old; objective mea-

surement or evaluation of the lesions; Karnofsky Performance Status Scale ≥ 70 ; blood evaluations: white blood cell (WBC) count $\geq 4.0 \times 10^9/\text{l}$, platelet count $\geq 100 \times 10^9/\text{l}$, hemoglobin $\geq 100 \text{ g/l}$; total bilirubin $\leq 1.5 \times$ the upper-normal limit (UNL), aspartate aminotransferase/alanine aminotransferase $\leq 1.5 \times$ UNL, and serum creatinine $\leq 1.5 \times$ UNL; no known allergies; no history of mental illness; and no drug abuse or other unhealthy habits. Patients with metastasis or malignancy in other organs were excluded. Patients were also excluded from the study if they had a history of another malignant tumor, participated in other clinical trials, had severe allergies, were pregnant or lactating, had previously received anti-EGFR therapy, or exhibited no tolerance to therapy.

The initial examination included a detailed medical history, assessment of performance status, physical examination, chest radiography or computed tomography (CT) scan, abdominal B ultrasonic scan or CT scan, bone emission CT scan, blood biochemical analysis, and intensive magnetic resonance imaging (MRI) or CT scan of the nasopharynx and neck. Cases were required to be staged according to the American Joint Committee on Cancer, 2010 Edition (7th, AJCC 2010).

The study protocol was approved by the Research Ethics Committee of the Eye, Ear, Nose & Throat Hospital of Fudan University. All procedures performed in studies involving human participants were in accordance with the ethical standards of the institutional and/or national research committee and with the 1964 Helsinki Declaration and its later amendments or comparable ethical standards. Written informed consent was obtained from all individual participants included in the study.

Study design and case grouping

This was a prospective, non-randomized trial, and the baseline demographic and clinical pathological characteristics and radiotherapy techniques were well matched. One hundred eighty patients diagnosed with NPC from September 2009 to February 2014 were enrolled, and they were divided into two groups with a sample ratio of 1 : 2 based on administration of Nimo. All the patients in our cohort completed 2–3 cycles of IC followed by CCRT, and 60 of the 180 patients were additionally administered Nimo. According to the application time of Nimo, the patients were divided into three groups: group A (120 patients), IC followed by CCRT; group B (30 patients), in which Nimo was applied at the beginning of IC (IC (+ Nimo) + CCRT); and group C (30 patients), in which Nimo was applied at the beginning of radiotherapy (IC + CCRT (+ Nimo)).

The primary study outcomes were overall survival (OS) and progression-free survival (PFS). The secondary outcome was the development of com-

mon toxicities, including hematological toxicity, skin reaction, mucositis, nausea/vomiting, and hepatotoxicity. The OS was defined as the time from the date of diagnosis to the date of death from any cause; PFS was defined as the time between the date of diagnosis and the date of local failure or distant metastasis. The investigators who assessed the treatment outcomes were blinded to the patients' group assignments.

Treatments

All patients received definitive intensity modulation radiation therapy (IMRT) or three-dimensional conformal radiotherapy (3D-CRT). Prescribed doses were determined according to the tumor volume and stage in reference to IMRT target dose designs and the expert consensus for NPC by the Chinese clinical NPC working committee and Wang's target delineation protocol [9]. The gross tumor volume doses were delivered with 66–69.75 Gy for the IMRT group and 68–73 Gy for the CRT group, and the treatment dose to involved lymph nodes was 60–70 Gy. The clinical tumor volume dose was delivered with 50–62 Gy.

IC regimens included TPF (docetaxel + cisplatin + 5-fluorouracil (5-FU)), TP (docetaxel + cisplatin), or PF (cisplatin + 5-FU). The TPF protocol consisted of 2–3 cycles of docetaxel 70 mg/m² on day 1 over 1 h, cisplatin 75 mg/m² on day 1 to day 3, and 5-FU 500 mg/m² from day 1 to day 4 as an intravenous infusion every 3 weeks. The PF protocol was the same as the TPF protocol except for the inclusion of docetaxel. Concurrent chemotherapy treatment regimens consisted of 1–3 cycles of cisplatin 80 mg/m² divided evenly across 3 days, and was repeated every 3 weeks. Dose modifications were allowed during chemotherapy according to the patient's tolerance, and the chemotherapy application time was adjusted appropriately. Chemotherapy was delayed until observation of a WBC count $\geq 3.5 \times 10^9/\text{l}$ and an absolute neutrophil count $\geq 1.5 \times 10^9/\text{l}$.

Nimo was administered weekly at a dose of 200 mg in 250 ml of physiological saline. Intravenous infusion of Nimo was administered over 60 minutes. Dexamethasone 5 mg was administered intravenously before Nimo to prevent allergic reactions. After infusion of Nimo, the infusion apparatus was flushed with normal saline to avoid mixed infusion with other drugs. Six to eight weeks of the targeted therapy was considered a complete dosage schedule.

Follow-up

Post-treatment assessment of patients, including a physical examination, was scheduled every 8 weeks in the first year, every 12 weeks in the

second year, and every 4–6 months thereafter. MRI/CT scan of the nasopharynx and neck, chest radiography, and abdominal ultrasound were performed approximately every 6 months during follow-up. An MRI/CT scan was performed for patients with clinical suspicion of local or locoregional recurrence. Distant metastases were diagnosed by clinical symptoms, physical examinations, chest CT, bone scan, MRI, CT, abdominal CT, or positron emission tomography/CT. The last recorded follow-up was August 25, 2017.

Statistical analysis

Numerical variables are expressed as the mean \pm standard deviation ($M \pm SD$), and categorical variables are expressed as a percentage (%). Categorized variables were compared using the χ^2 test. Kaplan-Meier curves were used to characterize OS and PFS, and differences in survival between patient subsets were evaluated using the log-rank test. A two-tailed *p*-value of less than 0.05 was considered statistically significant. All statistical analysis and graphing were performed using IBM SPSS 20 (IBM Corp., Armonk, NY, USA).

Results

Patient characteristics

A total of 168 patients with complete clinical and follow-up data were included in the analysis, including 126 men and 42 women, and 89.9% (151/168) of patients were diagnosed with advanced stage disease. The median age at diagnosis was 49 years (range: 17–72 years). Clinical data are shown in Table I. All the patients received 2–3 cycles of IC, and 20.8% (35/168) of patients underwent dose or time modification of chemotherapy during the course of CCRT. Fifty-six patients received 6–8 cycles of Nimo, and no dose or time modification occurred.

Efficacy

Through August 25, 2017, the median follow-up time was 61.4 months (range: 1.7–96.5 months). The 5-year OS for patients who did not receive Nimo (group A) and those who did (groups B + C) was 74.8 \pm 4.1% and 87.0 \pm 4.6%, respectively ($p = 0.043$; Figure 1 A). During follow-up, 34 patients who did not receive Nimo and 13 patients who did receive Nimo experienced disease progression, and the median times to disease progression were 26.6 and 45.3 months, respectively. The 5-year PFS for patients who did not receive Nimo and those who did was 72.7 \pm 4.3% and 83.1 \pm 5.1%, respectively ($p = 0.243$) (Figure 1 B).

There was a striking difference in the 5-year OS rate between group B and group A (93.0 \pm 4.8%

vs. $74.8 \pm 4.1\%$, $p = 0.038$; Figure 2 A). However, no significant difference in 5-year PFS was found between group B and group A ($89.3 \pm 5.9\%$ vs. $72.7 \pm 4.3\%$, $p = 0.144$, Figure 2 B). The 5-year OS and

PFS for group C were $80.4 \pm 7.9\%$ and $76.4 \pm 8.5\%$, respectively, and there was no significant difference compared with those of group A ($p = 0.257$ and $p = 0.611$, respectively; Figures 2 C and D).

Table I. Baseline characteristics of patients

Variable	Group A, n (%)	Group B, n (%)	Group C, n (%)	P-value*
Sex:				0.558
Male	84 (75.0)	20 (69.0)	22 (81.5)	
Female	28 (25.0)	9 (31.0)	5 (18.5)	
Age [years]:				0.501
> 50	63 (56.3)	14 (48.3)	18 (66.7)	
≤ 50	49 (43.7)	15 (51.7)	9 (33.3)	
T classification:				0.791
T1–2	62 (55.4)	16 (55.2)	13 (48.1)	
T3–4	50 (44.6)	13 (44.8)	14 (51.9)	
N classification:				0.655
N0–1	26 (23.2)	9 (31.0)	6 (22.2)	
N2–3	86 (76.8)	20 (69.0)	21 (77.8)	
Clinical stage:				0.362
II	11 (9.8)	2 (6.9)	4 (14.8)	
III	68 (60.7)	14 (48.3)	12 (44.4)	
IVA–B	33 (29.5)	13 (44.8)	11 (40.8)	

Group A – induction chemotherapy (IC) followed by concurrent chemoradiotherapy (CCRT); group B – IC concurrent with nimotuzumab followed by CCRT; group C – IC followed by CCRT and concurrent with nimotuzumab. *All p-values were obtained by the non-parametric test.

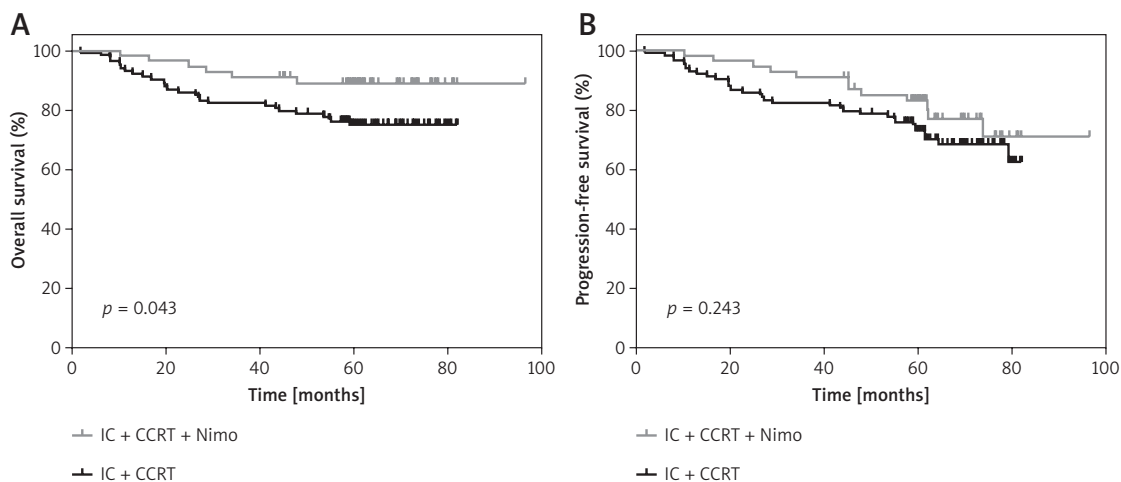


Figure 1. Kaplan-Meier estimation of 5-year-OS (A), 5-year-PFS (B) for patients who received IC plus CCRT treatment regimen with Nimo ($n = 56$) or without Nimo ($n = 112$)

P-values were calculated with log-rank test. IC – induction chemotherapy, CCRT – concurrent chemoradiotherapy, Nimo – nimotuzumab.

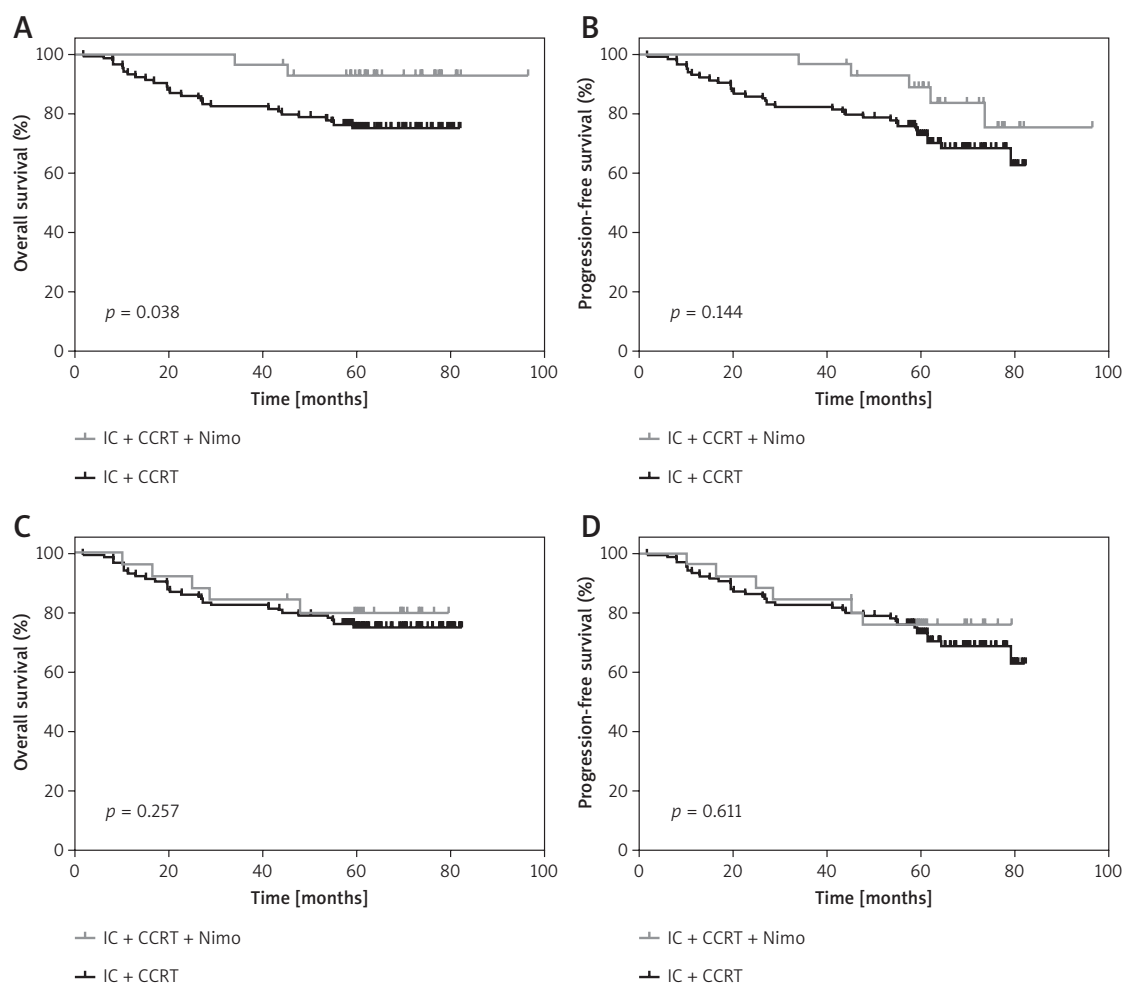


Figure 2. Kaplan-Meier estimation of 5-year-OS (A), 5-year-PFS (B) for patients who received IC concurrent Nimo plus CCRT ($n = 56$) or IC plus CCRT ($n = 112$), 5-year-OS (C), 5-year-PFS (D) for patients who received IC plus CCRT concurrent Nimo ($n = 56$) or IC plus CCRT ($n = 112$)

P-values were calculated with log-rank test. IC – induction chemotherapy, CCRT – concurrent chemoradiotherapy, Nimo – nimotuzumab.

Adverse events

Graded adverse events were evaluated using the National Cancer Institute Common Terminology Criteria for Adverse Events version 3.0. The treatment toxicities were generally mild, and no grade 3–4 acute toxicities occurred in the IC setting in any of the patients. In the concurrent chemotherapy phrase, nausea and vomiting were common in patients who received cisplatin. The other common acute adverse effects were oral mucositis, leukocytopenia, and skin reaction; however, there was no significant difference in toxicities among the different treatment regimens. It was rare to find a specific toxicity that was induced by Nimo. The majority of acute toxicities rapidly disappeared, and most patients recovered in a few months. Detailed adverse effects are displayed in Table II.

Xerostomia was the most common late adverse effect, and the degree of xerostomia appeared to decrease with time. Some patients complained of hearing impairment and recurrent secretory otitis media, and were treated in the Department of Otorhinolaryngology.

Discussion

This is a prospective, non-randomized trial of Nimo combined with IC followed by chemoradiotherapy for advanced NPC.

At present, IC + CCRT, CCRT, and CCRT plus adjuvant chemotherapy are the three major sequential modalities used to treat advanced NPC [10]. Studies have shown that CCRT plus adjuvant chemotherapy provides significant survival benefits over RT alone; however, it is also accompanied by intolerable toxicities [11–14]. According to the 2013

Table II. Acute toxicities in different treatment regimens

Adverse events	Group A, n (%)	Group B, n (%)	Group C, n (%)	P-value*
Anemia:				0.965
G1–2	26 (23.2)	7 (24.1)	6 (22.2)	
G3–4	5 (4.5)	1 (3.4)	1 (3.7)	
Thrombocytopenia:				0.964
G1–2	22 (19.6)	6 (20.7)	5 (18.5)	
G3–4	5 (4.5)	1 (3.4)	1 (3.7)	
Leukocytopenia:				0.987
G1–2	50 (44.6)	13 (44.8)	13 (48.1)	
G3–4	4 (3.7)	1 (3.4)	2 (7.4)	
Skin reaction:				0.87
G1–2	91 (81.3)	24 (82.8)	23 (85.2)	
G3–4	6 (5.4)	1 (3.4)	1 (3.7)	
Nausea/vomiting	63 (56.3)	16 (55.1)	15 (55.6)	0.994
Hepatotoxicity	17 (15.2)	3 (10.3)	3 (11.1)	0.727
Mucositis:				0.977
G1–2	103 (92.0)	27 (93.1)	25 (92.6)	
G3–4	9 (8.0)	2 (6.9)	2 (7.4)	

Group A – induction chemotherapy (IC) followed by concurrent chemoradiotherapy (CCRT); group B – IC concurrent with nimotuzumab then followed by CCRT; group C – IC followed by CCRT and concurrent with nimotuzumab. *All p-values were obtained by the non-parametric test.

National Comprehensive Cancer Network guidelines for head and neck cancer, CCRT is the standard treatment for patients with advanced NPC. However, increasing clinical trials have shown the feasibility and efficacy of IC for the treatment of advanced NPC. IC has the potential advantage of shrinking the tumor bulk before irradiation and, as a result, narrowing the radiation dose distribution difference caused by change in tumor size. Addition of TPF IC to CCRT significantly improves failure-free survival in locoregionally advanced NPC with acceptable toxicity [15].

EGFR has been evaluated as a therapeutic target for NPC, as there is increasing evidence that the EGFR signaling pathway might be important in NPC pathogenesis [16]. Anti-EGFR monoclonal antibodies have improved survival in patients with advanced head and neck cancer [17, 18]. Ma *et al.* [19] suggested that the use of cisplatin combined with cetuximab to treat locally advanced NPC was feasible. Nimo, a human EGFR monoclonal antibody, can antagonize epidermal growth factor and growth factor- α to block the EGFR extracellular domain structure, inhibiting tyrosine kinase activity and cell proliferation, thereby exhibiting anti-tumor capability [20]. Interestingly, however,

Westphal *et al.* [21] found that there was no obvious correlation of Nimo efficacy with EGFR status. Nimo was proven to increase the cytotoxic effect of radiation and chemotherapy on tumor cells in advanced head and neck tumors [22]. Two retrospective analyses with a large cohort of patients with stage II–IV b NPC suggested that Nimo administered concurrently with IMRT might improve the survival benefit in patients with advanced NPC over CCRT alone [6, 23]. Li *et al.* [24] believed that Nimo + RT should only be administered to patients with stage II NPC, those older than 60 years, and those resistant to cisplatin.

Nimo was safe and well tolerated with few mild to moderate self-limiting adverse events. There are few studies on the best combination of Nimo and chemoradiotherapy to achieve the maximum therapeutic effect. In this study, we investigated the difference among 3 sequential modalities of Nimo in combination with chemoradiotherapy. We found that Nimo plus IC followed by CCRT achieved the best survival benefit for advanced NPC.

Regardless of when Nimo was administered, we observed a significant improvement in 5-year OS ($87.0 \pm 4.6\%$ vs. $74.8 \pm 4.1\%$, $p = 0.043$) and a non-significant improvement in PFS ($83.1 \pm 5.1\%$

vs. $72.7 \pm 4.3\%$, $p = 0.243$) in patients who received Nimo. Therefore, we conclude that Nimo combined with chemoradiotherapy is effective for advanced NPC. In further analysis, we found that when Nimo was applied simultaneously with IC, the 5-year-OS was significantly higher than that in patients who did not receive Nimo ($p = 0.038$); however, there was no difference in 5-year OS or PFS between patients who received Nimo at the beginning of CCRT and those who did not receive Nimo. Therefore, Nimo concurrent with IC followed by CCRT might be the optimal mode of sequential treatment for patients with advanced NPC. The results in our study were quite different from the current thinking in the field, which could be because all the published data are based on the application of Nimo with CCRT [25–27]. To the best of our knowledge, there are few studies reporting that Nimo can be applied concurrently with IC to treat NPC. Moreover, this treatment mode achieved better survival benefits. Nimo might assist the IC to control the primary tumor and the locoregional lymph nodes. In addition, the weekly application of Nimo could also contribute to patient well-being, because many patients did not believe they were treated promptly during the IC interval.

Compared with cetuximab, another EGFR inhibitor, Nimo showed a great advantage in terms of toxicity and tolerance. In our study, the proportion of common adverse events did not increase with the addition of Nimo to chemoradiotherapy. In addition, our results demonstrated that no Nimo-related skin rash was found in any patient. Nimo was well tolerated, especially when combined with IC. The results of this study were similar to those of previous studies [8]. However, in our experience, the tolerance and compliance of patients who received Nimo with IC were better than those of patients who received Nimo combined with CCRT. The former were more likely to adhere to the treatment without delay or dose modification.

However, due to the small number of patients administered Nimo and the non-randomized design of this trial, further randomized controlled phase III clinical research is required. A retrospective study of large samples similar to this study is ongoing, and we expect a promising result soon.

In conclusion, based on our present data, the addition of Nimo to chemoradiotherapy was more effective in improving the overall survival rate of patients with nasopharyngeal carcinoma compared to chemoradiotherapy alone. Nimotuzumab administered with chemoradiotherapy was effective for advanced nasopharyngeal carcinoma. However, Nimo concurrent with induction chemotherapy followed by concurrent chemoradio-

therapy could be the optimal mode of sequential treatment for this combination.

Acknowledgments

We deeply appreciate the help from our colleagues in the Department of Radiation Oncology at the Eye, Ear, Nose and Throat Hospital of Fudan University. The authors would like to thank all study participants. We would like to thank Editage (www.editage.com) for English language editing.

This work was supported by funds from the People's Republic of China Ministry of Science and Technology. The project number was 2011ZX09101-001.

Conflict of interest

The authors declare no conflict of interest.

References

1. OuYang PY, Xie C, Mao YP, et al. Significant efficacies of neoadjuvant and adjuvant chemotherapy for nasopharyngeal carcinoma by meta-analysis of published literature-based randomized, controlled trials. *Ann Oncol* 2013; 24: 2136-46.
2. Dorsey K, Agulnik M. Promising new molecular targeted therapies in head and neck cancer. *Drugs* 2013; 73: 315-25.
3. Wu F, Wang R, Lu H, et al. Concurrent chemoradiotherapy in locoregionally advanced nasopharyngeal carcinoma: treatment outcomes of a prospective, multicentric clinical study. *Radiother Oncol* 2014; 112: 106-11.
4. Ma NY, Cai XW, Fu XL, et al. Safety and efficacy of nimotuzumab in combination with radiotherapy for patients with squamous cell carcinoma of the esophagus. *Int J Clin Oncol* 2014; 19: 297-302.
5. Huang J, Zou Q, Qian D, et al. Intensity-modulated radiotherapy plus nimotuzumab with or without concurrent chemotherapy for patients with locally advanced nasopharyngeal carcinoma. *Onco Targets Ther* 2017; 10: 5835-41.
6. You R, Sun R, Hua YJ, et al. Cetuximab or nimotuzumab plus intensity-modulated radiotherapy versus cisplatin plus intensity-modulated radiotherapy for stage II-IVb nasopharyngeal carcinoma. *Int J Cancer* 2017; 141: 1265-76.
7. Liu ZG, Zhao Y, Tang J, et al. Nimotuzumab combined with concurrent chemoradiotherapy in locally advanced nasopharyngeal carcinoma: a retrospective analysis. *Oncotarget* 2016; 7: 24429-35.
8. Wang F, Jiang C, Ye Z, et al. Efficacy and safety of nimotuzumab with neoadjuvant chemotherapy followed by concurrent chemoradiotherapy for locoregionally advanced nasopharyngeal carcinoma. *Oncotarget* 2017; 8: 75544-56.
9. Wang SZ, Li J, Miyamoto CT, et al. A study of middle ear function in the treatment of nasopharyngeal carcinoma with IMRT technique. *Radiother Oncol* 2009; 93: 530-3.
10. Ji X, Xie C, Hu D, Fan X, Zhou Y, Zheng Y. Survival benefit of adding chemotherapy to intensity modulated radiation in patients with locoregionally advanced nasopharyngeal carcinoma. *PLoS One* 2013; 8: e56208.
11. Al-Sarraf M, LeBlanc M, Giri PG, et al. Chemoradiotherapy versus radiotherapy in patients with advanced na-

- sopharyngeal cancer: phase III randomized Intergroup study 0099. *J Clin Oncol* 1998; 16: 1310-7.
12. Langendijk JA, Leemans CR, Buter J, Berkhof J, Slotman BJ. The additional value of chemotherapy to radiotherapy in locally advanced nasopharyngeal carcinoma: a meta-analysis of the published literature. *J Clin Oncol* 2004; 22: 4604-12.
13. Chen Y, Sun Y, Liang SB, et al. Progress report of a randomized trial comparing long-term survival and late toxicity of concurrent chemoradiotherapy with adjuvant chemotherapy versus radiotherapy alone in patients with stage III to IVB nasopharyngeal carcinoma from endemic regions of China. *Cancer* 2013; 119: 2214.
14. Ohno T, Thinh DH, Kato S, et al. Radiotherapy concurrently with weekly cisplatin, followed by adjuvant chemotherapy, for N2-3 nasopharyngeal cancer: a multicenter trial of the Forum for Nuclear Cooperation in Asia. *J Radiat Res* 2013; 54: 467-73.
15. Sun Y, Li WF, Chen NY, et al. Induction chemotherapy plus concurrent chemoradiotherapy versus concurrent chemoradiotherapy alone in locoregionally advanced nasopharyngeal carcinoma: a phase 3, multicentre, randomised controlled trial. *Lancet Oncol* 2016; 17: 1509-20.
16. Tsang J, Lee VH, Kwong DL. Novel therapy for nasopharyngeal carcinoma – where are we. *Oral Oncol* 2014; 50: 798-801.
17. Bonner JA, Harari PM, Giralt J, et al. Radiotherapy plus cetuximab for squamous-cell carcinoma of the head and neck. *N Engl J Med* 2006; 354: 567-78.
18. Bonner JA, Harari PM, Giralt J, et al. Radiotherapy plus cetuximab for locoregionally advanced head and neck cancer: 5-year survival data from a phase 3 randomised trial, and relation between cetuximab-induced rash and survival. *Lancet Oncol* 2010; 11: 21-8.
19. Ma BB, Kam MK, Leung SF, et al. A phase II study of concurrent cetuximab-cisplatin and intensity-modulated radiotherapy in locoregionally advanced nasopharyngeal carcinoma. *Ann Oncol* 2012; 23: 1287-92.
20. Akashi Y, Okamoto I, Iwasa T, et al. Enhancement of the antitumor activity of ionising radiation by nimotuzumab, a humanised monoclonal antibody to the epidermal growth factor receptor, in non-small cell lung cancer cell lines of differing epidermal growth factor receptor status. *Br J Cancer* 2008; 98: 749-55.
21. Westphal M, Heese O, Steinbach JP, et al. A randomised, open label phase III trial with nimotuzumab, an anti-epidermal growth factor receptor monoclonal antibody in the treatment of newly diagnosed adult glioblastoma. *Eur J Cancer* 2015; 51: 522-32.
22. De Wever O, Mareel M. Role of tissue stroma in cancer cell invasion. *J Pathol* 2003; 200: 429-47.
23. You R, Hua YJ, Liu YP, et al. Concurrent chemoradiotherapy with or without anti-EGFR-targeted treatment for stage II-IVb nasopharyngeal carcinoma: retrospective analysis with a large cohort and long follow-up. *Theranostics* 2017; 7: 2314-24.
24. Li HM, Li P, Qian YJ, et al. A retrospective paired study: efficacy and toxicity of nimotuzumab versus cisplatin concurrent with radiotherapy in nasopharyngeal carcinoma. *BMC Cancer* 2016; 16: 946.
25. Wang F, Jiang C, Ye Z, et al. Treatment outcomes of 257 patients with locoregionally advanced nasopharyngeal carcinoma treated with nimotuzumab plus intensity-modulated radiotherapy with or without chemotherapy: a single-institution experience. *Transl Oncol* 2018; 11: 65-73.
26. Li Z, Li Y, Yan S, et al. Nimotuzumab combined with concurrent chemoradiotherapy benefits patients with advanced nasopharyngeal carcinoma. *Onco Targets Ther* 2017; 10: 5445-58.
27. Wang F, Sun Q, Jiang C, et al. Additional induction chemotherapy to concurrent chemotherapy and intensity-modulated radiotherapy with or without nimotuzumab in first-line treatment for locoregionally advanced nasopharyngeal carcinoma: a propensity score matched analysis. *J Cancer* 2018; 9: 594-603.